

# Experience using a glucose oxidase dressing on chronic diabetic foot ulcers

Martin Turns

**Chronic diabetic foot ulcers are costly to treat and can markedly reduce quality of life. To promote ulcer healing, all factors contributing to good wound bed preparation need to be addressed, including oxygen balance. Oxyzyme is a new hydrogel dressing that increases the concentration of dissolved oxygen at the wound surface, and was the subject of two recently published non-comparative clinical trials, which are described here. A case study in which the dressing was used to treat a chronic diabetic foot ulcer is also reported.**

Chronic wounds are a huge financial burden on health services, with their management estimated to cost the NHS more than £1 billion per year (Bennett et al, 2004). The personal cost to those affected, in terms of reduced quality of life, is also well documented (Franks et al, 2006). To ease the economic burden on health services, and to improve quality of life for those affected, it is essential that chronic wounds are closed as quickly as possible.

This article reviews the role of a new hydrogel dressing, Oxyzyme (Archimed, Bedford), in healing diabetic foot ulcers.

## Role of oxygen in wound healing

The role of oxygen in wound healing is multifaceted and has been well documented (Kalliainen et al, 2003; Gottrup, 2004; Hunt et al, 2004). Oxygen is needed during all phases of wound healing for:

- Energy metabolism during cellular repair.
- Collagen synthesis and neovascularisation during tissue regeneration.
- Polymorphonuclear cell function in defence against infection.
- Antimicrobial action against malodorous anaerobic bacteria.
- The effective action of some antibiotics (Ivins et al, 2007).

Various methods of delivering oxygen to the wound bed have been documented, but remain controversial. One method of delivery is the use of topical oxygen, which diffuses no deeper than the upper 2mm of tissue (Ovington and Eisenbud, 2004). Oxygen delivered topically to a wound cavity supports autolytic debridement and oxygen-dependent tissue regeneration activities, prevents chronic hypoxia-mediated neutrophil chemotaxis, and promotes more effective phagocytic

## Article points

1. Diabetic foot wounds are costly and markedly reduce quality of life.
2. Oxygen is essential for all phases of wound healing.
3. How best to deliver oxygen to a wound remains controversial.
4. Oxyzyme is a hydrogel dressing which increases the concentration of dissolved oxygen at the wound surface.
5. Treatment with this hydrogel dressing facilitated final closure of a non-healing diabetic foot ulcer in a person with a complex medical history.

## Key words

- Diabetic foot ulceration
- Wound healing
- Oxygen dressing

Martin Turns is Lead Podiatrist in Diabetes, Southdowns NHS Trust, Brighton.

**Page points**

1. While oxygen is necessary for wound healing, it is impractical to create oxygen balance in a wound through continuous exposure to the air.
2. Oxyzyme is a two-piece hydrogel dressing that incorporates a biochemical system, which increases the concentration of dissolved oxygen at the wound surface and releases iodine from within the gel matrix.
3. Two non-comparative clinical trials to evaluate the safety and performance of the dressing have recently been published.
4. An international multicentre case study programme to assess the efficacy of the dressing is currently being undertaken.

and microbicidal neutrophil activity (Hunt et al, 2007).

While oxygen is necessary for many of the cellular activities essential to achieving wound healing, it is impractical to create oxygen balance in a wound through continuous exposure to the air, as this would disrupt other factors associated with good wound bed preparation. Thus, therapeutic dressings that introduce oxygen into the wound cavity provide essential oxygen while simultaneously acting as a protective barrier.

Oxyzyme is a two-piece dressing based on hydrogel technology. Like other sheet hydrogels, it provides a moist wound environment that supports autolytic debridement and can reduce pain and facilitate healing. Additionally, it incorporates a biochemical system that increases the concentration of dissolved oxygen at the wound surface. This is achieved when the two components of the dressing (packaged separately) are brought together: the larger hydrogel contact sheet (containing glucose and iodide ions) is applied to the wound surface, while the smaller hydrogel sheet (containing the enzyme glucose oxidase) is applied to the centre of the contact layer. Oxygen from the atmosphere then enters the dressing and the glucose oxidase catalyses the formation of hydrogen peroxide. The hydrogen peroxide then diffuses through the iodide ion-impregnated layer, resulting in the formation of free iodine and dissolved oxygen. The iodine and the dissolved oxygen are designed to work in concert to produce an oxygen-rich environment, while reducing the bioburden, through the increased presence of oxygen and the action of the iodine itself (Trabold et al, 2003; Thomas, 2008).

**Clinical trials**

Results from two non-comparative clinical trials to evaluate the safety and performance of the dressing have recently been published. The trials were conducted at the Cardiff Wound Healing Research Unit (Ivins et

al, 2007) and the Toronto Wound Healing Centre (Queen et al, 2007).

*Cardiff Wound Healing Research Unit study*

This study was conducted over a 6-week period in people with venous leg ulcers. The duration of the ulcers ranged from 6 weeks to 48 years. Previous treatments included topical antimicrobials (e.g. iodine and silver) and compression therapy. All ulcers in this study were treated with Oxyzyme and graduated high compression therapy. The authors found that 32% of the wounds healed and 58% improved during the 6-week study period. The authors noted that “the results were surprising in that a number of recalcitrant wounds healed within the 6-week time frame” (Ivins et al, 2007).

No diabetic foot ulcers were included in the Cardiff trial, although three participants had type 2 diabetes. Of these three, two healed and one improved.

*Toronto Wound Healing Centre study*

This study was conducted over a 4-week period. Twenty people with 22 wounds of differing aetiologies were included in the study. The duration of the wounds in the study ranged from 1 month to 37 years. Previous treatments included Hydrofiber, topical antimicrobials (e.g. silver and iodine) and hydrocolloids. Oxyzyme was applied to all wounds and was covered with an adhesive polyurethane film dressing. By study end, 18% of the wounds had healed and 68% had improved (Queen et al, 2007).

Three of the wounds treated in this study were diabetic foot ulcers; two showed improvement, one was withdrawn due to maceration (Queen et al, 2007).

*Forthcoming data*

An international multicentre case study programme, the preliminary results of which are available, has been undertaken to demonstrate the efficacy of this dressing (Archimed, 2009). In this study, participants with chronic wounds of more than 12 weeks’

duration, receiving care from clinicians in a variety of settings, were treated with the dressing and their progress followed for a period of 6 weeks. Participants had been previously managed, without success, using a number of modern dressings and treatments, including vacuum-assisted closure therapy, larval therapy, hydrogels, films, foams and silver-based antimicrobial dressings. At the time of writing, the results of 100 of the 150 cases collected had been analysed. These data showed that 68% of wounds had healed or improved within the 6-week treatment period (Archimed, 2009).

Meta-analysis of the results from the diabetic foot ulcers included in this case study programme suggest a positive clinical response to the dressing in the diabetic foot. Diabetic foot ulcers included ( $n=13$ ) healed or improved in 77% of cases by week 6 (Archimed, 2009).

The following case study reports one diabetic foot ulcer that was followed as part of this programme.

### Case study

Mr R, a 46-year-old man with type 1 diabetes (diagnosed in 1972), has a complex medical history. He has background retinopathy, peripheral neuropathy (reporting numbness to his feet and a reduced perception when tested with a 10g monofilament), hypertension, diabetic nephropathy (creatinine level 271  $\mu\text{mol/L}$ , estimated glomerular filtration rate 22 mL/minute, both taken in July 2007) and evidence of autonomic neuropathy. Attempts to take Mr R's ankle-brachial pressure index were unsuccessful, indicating incompressible vessels. Audible Doppler sounds indicated a monophasic right dorsalis pedis pulse, a biphasic right posterior tibial pulse and triphasic left dorsalis pedis and posterior tibial pulse. Dorsalis pedis pulses were palpable in both feet. In May 2005, Mr R's left Achilles tendon was surgically repaired.

Mr R first presented with an ulcer on the plantar surface of his left heel in

February 2006. He was treated with various wound management dressings, but the wound remained open and healing had been static for several months. During this period the wound fluctuated in size and appearance and there were numerous episodes when the wound deteriorated, infection was present and antibiotics were prescribed.

In September 2006, Mr R's management plan was reassessed: an Aircast Boot (Mobilis, Oldham) was issued and a plain X-ray was requested. Mr R did not appear to be concordant with the boot. The X-ray was inconclusive for osteomyelitis and a magnetic resonance imaging scan was requested; no definite sinus tract, cloaca or intraosseous abnormality was reported to indicate the presence of osteomyelitis. In December 2006, a Scotchcast boot (3M, Bracknell) was manufactured, but Mr R was unable to tolerate the device.

In January 2007, Mr R made a decision to wear the Aircast Boot continuously with crutches, which resulted in the ulcer nearly healing by May 2007. However, the ulcer failed to close, and, in July 2007, Mr R returned to using normal shoes and insoles. As a consequence, the wound deteriorated in August 2007.

Mr R was enrolled in the case study programme in September 2007. Upon entry to the study, the wound was described as a small, shallow cavity situated on the left heel, measuring 1  $\text{cm}^2$ . The wound bed was found to be 100% granulation tissue. There was a moderate level of clear wound exudate. The surrounding tissue was healthy with slightly macerated wound margins (*Figure 1*).

The glucose oxidase dressing was applied to the wound (but not cut to the size of the wound) and covered with a Premierpad dressing (Shermond, Brighton) and a retention bandage. The wound was reviewed at twice-weekly dressing changes. There were no changes to Mr R's off-loading regimen.

Following treatment for 1 week, the wound was reassessed. A reduction in wound area of 43% and a reduction in wound exudate, which had become haemoserous, were

### Page points

1. Participants in the case study programme are treated with the dressing for a period of 6 weeks. Of the 100 cases assessed so far, 68% of wound have been found to heal or improve within the 6-week treatment period.
2. Meta-analysis of diabetic foot ulcers included in the case study suggests a positive clinical response to the dressing in the diabetic foot; 77% of cases have healed or improved by week 6.
3. Mr R, a 46-year-old man with type 1 diabetes and a complex medical history, presented with an ulcer on the plantar surface of the left heel in February 2006.
4. A 6-month period of wearing an Aircast Boot with crutches led to the ulcer almost healing by May 2007. However, a return to wearing normal shoes and insoles in July 2007 led to the ulcer deteriorating in August 2007.

**Page points**

1. The dressing was applied to Mr R's wound and covered with a Premierpad dressing and a retention bandage and the wound was reviewed at twice-weekly dressing changes.
2. After 1 week's treatment, the wound area had reduced by 43%; wound exudate was also reduced and had become haemoserous.
3. At week 6, the wound area was reduced by 76%. Because of this rapid improvement, treatment was continued for a further 11 weeks.
4. The wound continued to reduce in area and depth and was fully healed at week 17.

noted (Figure 2). By week 6, a reduction in wound area of 76%, with slight maceration of the wound edges, was noted. Owing to the rapid improvement of the wound, treatment was continued for a further 11 weeks. The wound continued to reduce in area and depth and was reported to be fully epithelialised by week 17. The progress of Mr R's ulcer is represented graphically in Figure 3. Use of the glucose oxidase dressing was discontinued in December 2007, owing to plugging of the wound, and a simple non-adherent dressing was applied. Final closure was noted in January 2008 (Figure 4).

Insoles were manufactured to reduce excess pressure on Mr R's heel and a physiotherapy referral was requested for review of his previously repaired left Achilles tendon. The wound remains healed at March 2009, without any noticeable scarring.

**Discussion**

Oxygen is essential in the wound healing process and various methods of oxygen application and delivery have been suggested. There is a growing body of evidence suggesting that hyperbaric oxygen therapy can have a positive effect on wound healing (Leach et al, 1998; Neal, 2001;

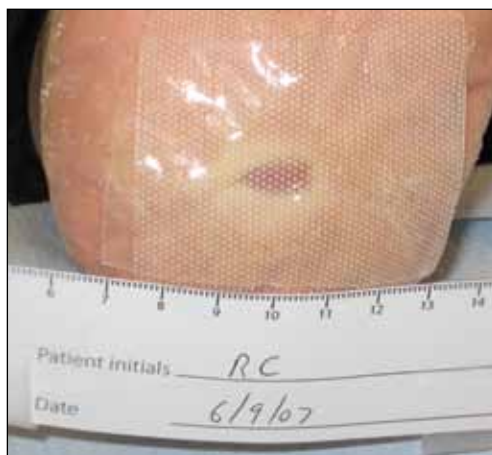

Figure 1. The appearance of Mr R's ulcer prior to commencement of therapy with the glucose oxidase dressing.

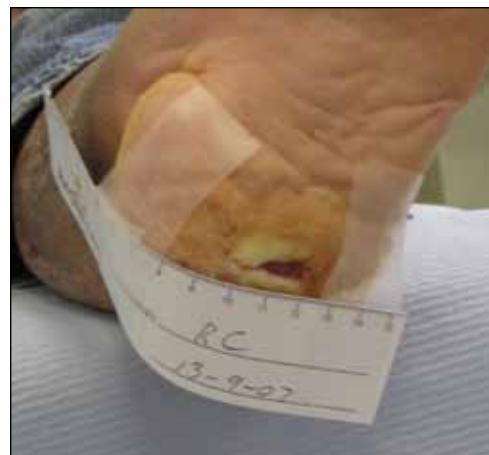


Figure 2. Mr R's ulcer 1 week after the commencement of therapy with the glucose oxidase dressing. Note the slight maceration.

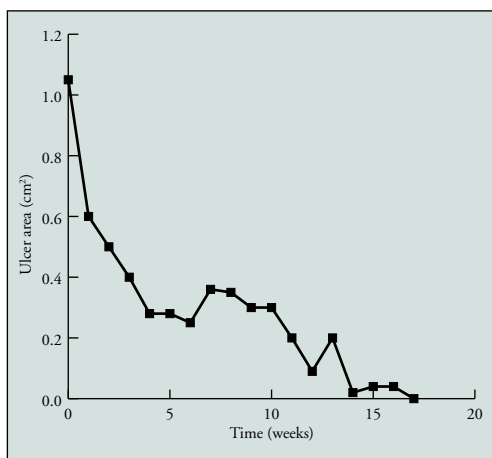


Figure 3. The progression of Mr R's diabetic foot ulcer from the initiation of treatment to full epithelialisation in week 17.

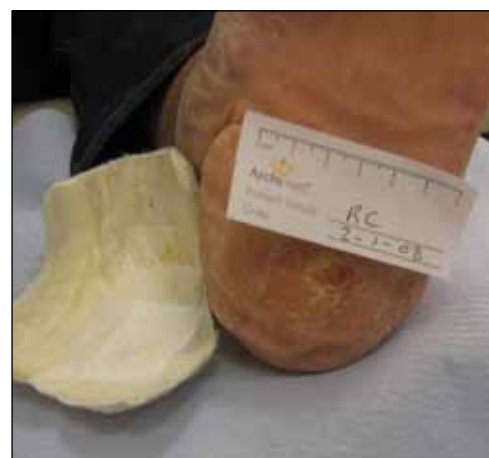

Figure 4. Following 17 weeks of treatment with the glucose oxidase dressing, Mr R's ulcer closed in January 2008.

Rowe 2001). Further studies are required to fully understand the role of hyperbaric oxygen therapy in wound healing.

The topical delivery of oxygen to wounds, via the novel hydrogel dressing Oxyzyme, is described here. The dressing is easy to apply, ideally sized for use in diabetic foot wounds (6.5 × 5 cm), is indicated for use in the treatment of non-infected wounds and may also be used on moderately exuding, non-exuding and dry wounds. There is no limit to the length of time that the dressing can be used, despite its iodine generation. It is indicated for the removal of devitalised tissue and can be used on sloughy, necrotic or granulating wounds (Thomas, 2008).

This dressing is not suitable for use on very wet wounds requiring daily dressing changes, or for sinuses. It is contraindicated for the treatment of infected wounds, and should not be used in those taking lithium, those sensitive to iodine or those with a thyroid disorder (Thomas, 2008).

### Conclusion

While oxygen is required for wound healing, determining a practical way to create oxygen balance, without disrupting other factors associated with wound bed preparation, is complex. Use of Oxyzyme is one method of delivering oxygen to the wound bed.

The results presented here suggest that the dressing is effective in promoting healing of diabetic foot ulcers. Further studies on the use of this dressing in the treatment of diabetic foot ulcers are required to fully understand the impact that this dressing may have on improving outcomes for this expensive and debilitating diabetic complication. ■

### Acknowledgement

The author would like to thank Lisa Wood (Tissue Viability Nurse, Archimed, Bedford) for her assistance in the research and development of this article.

Archimed (2009) *Summary Analysis of the First 100 Case Studies from the Ongoing European Case Study Programme*. Available at: [http://www.insense.co.uk/oxy\\_100.html](http://www.insense.co.uk/oxy_100.html) (accessed 02.03.09)

Bennett G, Dealey C, Posnett J (2004) The Cost of pressure ulcers in the UK. *Age and Ageing* **33**: 230–5

Franks PJ, Moffatt CJ, Doherty DC et al (2006) Assessment of health-related quality of life with lymphedema of the lower limb. *Wound Repair and Regeneration* **14**: 110–18

Gottrup F (2004) Oxygen, wound healing and infection. *World Journal of Surgery* **28**: 312–15

Hunt TK, Ellison EC, Sen CK (2004) Oxygen: At the foundation of wound healing: Introduction. *World Journal of Surgery* **28**: 291–3

Hunt TK, Aslam RS, Beckert S (2007) Aerobically derived lactate stimulates revascularization and tissue repair via redox mechanisms. *Antioxidants & Redox Signaling* **9**: 1115–24

Ivins N, Simmonds W, Turner A et al (2007) The use of an oxygenating hydrogel dressing in VLU. *Wounds UK* **3**: 77–81

Kalliainen LK, Gordillo GM, Schlanger R et al (2003) Topical oxygen is an adjunct to wound healing: A clinical case series. *Pathophysiology* **9**: 81–7

Leach RM, Rees PJ, Wilmshurst P (1998) Hyperbaric oxygen therapy. *British Medical Journal* **317**: 1140–3

Neal MS (2001) Benefits of hyperbaric oxygen therapy for diabetic foot lesions. *Journal of Wound Care* **10**: 507–9

Ovington LG, Eisenbud D (2004) Dressings and cleansing agents. In: Morison IM, Ovington LG, Wilkie K (eds). *Chronic Wound Care: A Problem-based Learning Approach*. Elsevier, Oxford: 117–27

Queen D, Coutts P, Fierheller M et al (2007) The use of a novel oxygenating hydrogel dressing in the treatment of different chronic wounds. *Advances in Skin & Wound Care* **20**: 200–6

Rowe K (2001) Hyperbaric oxygen therapy: What is the case for its use? *Journal of Wound Care* **10**: 117–21

Thomas S (2008) *SMTL Dressings Datacard – Oxyzyme*. Available at: [www.dressings.org/dressings/oxyzyme.html](http://www.dressings.org/dressings/oxyzyme.html) (accessed 23.01.09)

Trabold O, Wagner S, Wicke C et al (2003) Lactate and oxygen constitute a fundamental regulatory mechanism in wound healing. *Wound Repair and Regeneration* **11**: 504–9

### Page points

1. This dressing is indicated for use in the treatment of non-infected wounds, moderately exuding, non-exuding and dry wounds, for the removal of devitalised tissue in sloughy, necrotic or granulating wound, and there is no limit to the length of time that it can be used.
2. The dressing is not suitable for use on very wet wounds, sinuses or infected wounds, and should not be used for the treatment of wounds in those taking lithium, those sensitive to iodine or those with a thyroid disorder.
3. The results presented here suggest that this dressing is effective at promoting healing of diabetic foot ulcers.