

The role of a soft silicone sealant on patients with diabetic foot ulceration: A case study series

Samantha Haycocks, Kimberley Watts, Paul Chadwick

Article points

1. The foot can be difficult to dress, particularly post operatively.
2. The contours of the foot and the act of walking create problems in maintaining a seal when using negative pressure wound therapy.
3. The periwound can be adversely affected by exudates from a wound and may contribute to delayed healing.
4. Periwound maceration can impact on clinical (e.g. delay healing), patient-centred (e.g. pain), and economic (e.g. increased treatment costs) parameters.

Samantha Haycocks is an Advanced Podiatrist, Kimberley Watts is a Senior Podiatrist and Paul Chadwick is Principal Podiatrist. All are based at the Salford Royal Foundation Trust, Salford.

Article sponsored by



The authors report a case series evaluating the role of a soft silicone sealant (Mepiseal[®] with Safetac[®] technology; Mölnlycke Health Care, Gothenburg, Sweden), designed to work in conjunction with wound dressings, negative pressure wound therapy (NPWT) or ostomy systems, in protecting the periwound region and providing an aid to the conservation of wound interface integrity. Fourteen patients with diabetic foot ulcers were enrolled. The sealant was reported to be easy and quick to apply and – in the case of NPWT – the investigators felt it enhanced the seal. The investigators rated the overall experience of using the soft silicone sealant as “good” or “very good”.

The incidence of diabetes is escalating worldwide (Wild et al, 2004) and is associated with a number of complications, including diabetic foot ulcers (DFUs; Boulton et al, 2005). Good medical management of DFUs should focus on the holistic care of the person and specifically on pressure relief of the ulcerated area, wound bed preparation – especially debridement – and the careful management of exudate levels, infection and pain (Frykberg, 2002).

Background

Modern wound management is based on the principal of moist wound healing first described by Winter (1962). Modern wound care products are designed to address this principal in conjunction with trying to address other aspects of wound complications, such as infection (using impregnated antimicrobials such as silver or iodine) or pain (using, for example, silicone adhesives).

The ability of a wound dressing to remain in place can be adversely affected by the location of the wound, the quality of the periwound skin, incontinence, as well as patient mobility (Whitney et al, 2006). The failure of a dressing to remain *in situ* can result in the leakage of exudate onto the periwound region, thus increasing the risk of moisture-related skin damage (i.e. maceration), which can be clinically challenging and costly to resolve. This issue of maintaining a wound care product, such as a dressing, or negative pressure wound therapy, *in situ* is a particular issue with the foot. Anecdotally, it is acknowledged that the contours and structure of feet provide a particular challenge. Further considerations with feet are that they are walked on and have to be accommodated in footwear. The act of walking creates stresses and pressures (Kinoshita, 1985) on the feet and subsequently the dressings, which can impede their ability to remain *in situ*. The placing of feet in hosiery and footwear can

alter a dressing's moisture vapour transmission rate (MVTR) (Chadwick, 2008). The MVTR represents the amount of moisture that passes through a membrane, such as a dressing, during a given time period. The higher the MVTR, the more effectively moisture is removed, preventing the accumulation of pools of moisture under the dressing membrane, which can lead to maceration. Altering MVTR by close proximity of the dressing to hosiery or footwear can result in an increase in exudate levels.

The failure of a dressing to remain *in situ*, and the effects of periwound maceration, can impact in a variety of ways:

Clinical – Maceration should be avoided in all wounds as it damages the wound and periwound region due to the constitution of its exudates. Chronic wound exudate contains proteases, which break down protein and will actively damage what may be otherwise healthy tissue (Gibson et al, 2009) This damage will have an impact on wound healing. Within the management of DFUs, maceration is a particular concern. This relates to increased risk of infection of an immunocompromised patient further exacerbated by providing a moist environment where bacteria, particularly organisms like *Pseudomonas aeruginosa*, can multiply.

Patient-centred – Often ignored in the treatment of a chronic wound is the effect that the wound will have on the patient. A primary effect of wound treatment is pain. There is evidence to show that significant pain is often experienced by patients during wound care, specifically in relation to dressing changes (Upton et al, 2012). If patients are subjected to unnecessary dressing changes due to the failure of a seal or adherence to a wound, they may suffer pain and stress that can delay wound healing (Upton et al, 2012). While pain at dressing change is not usually considered important for people with DFUs due to the possible presence of underlying neuropathy, it needs to be remembered that in the continuum of DFU starting at neuropathic and ending in ischaemic, there is a group of patients who will potentially have some partial sensory loss with or without some vascular reduction.

People with only partial sensory loss and some reduction in blood flow are more likely to feel pain; Bradbury and Price (2011) showed that 86% of their DFU population had some ulcer-related pain.

Further patient-centred impacts include living with the wound and dressings. In a qualitative study, Abbotts (2010) explored patients' views of dressing a wound (including DFUs) with negative pressure wound therapy (NPWT). Nine themes emerged from the data and included healing, smell, embarrassment and pain. It was found that patients felt embarrassed due to the noise and aesthetics of the system, and the odour of the exudate. These problems may be increased if the NPWT seal fails or there is leakage of exudates. Abbotts (2010) concluded that these embarrassments restricted patients' social lives and resulted in anxiety.

Economic – If a dressing fails due to the issues described above there will be an economic impact as dressing changes will be required more frequently, which results in an increased need for staff care and higher hospital costs (Mendonca et al, 2006).

Here, the authors report the results of a case series designed to evaluate the role of a soft silicone sealant (Mepiseal® with Safetac® technology; Mölnlycke Health Care, Gothenburg, Sweden) in optimising wound management. Mepiseal is a non-sterile, viscous silicone designed to work in conjunction with wound dressings, NPWT or ostomy systems.

After application to the skin, Mepiseal cures spontaneously to a double-sided fixating sealant designed to protect the skin from body fluids such as exudate, urine and faeces. When used in conjunction with NPWT, Mepiseal may help to achieve both an initial seal and to maintain a seal during the periods between dressing changes to ensure constant, accurate delivery of negative pressure to the wound. The inclusion of Safetac technology in the design of Mepiseal assures minimisation of pain and trauma at application, during use and at removal.

This case series evaluation focused on the following perspectives:

Page points

1. Maceration should be avoided in all wounds as it damages the wound and periwound region.
2. While pain at dressing change is not usually considered important for people with diabetic foot ulcers due to the possible presence of underlying neuropathy, it needs to be remembered that people with only partial sensory loss and some reduction in blood flow are more likely to feel pain.
3. The authors report the results of a case study series designed to evaluate the role of a soft silicone sealant (Mepiseal® with Safetac® technology; Mölnlycke Health Care, Gothenburg, Sweden) in optimising wound management.
4. After application to the skin, Mepiseal cures spontaneously to a double-sided fixating sealant designed to protect the skin from body fluids such as exudate, urine and faeces.

Page points

1. The primary objectives of this preliminary study were to evaluate the role of a soft silicone sealant in protecting the periwound region and providing an aid to the conservation of wound interface integrity.
2. The investigation was designed as a single-centre, open, non-randomised case series involving in- and out-patients attending a specialist podiatry clinic with active diabetic foot ulcers.
3. Each participant was treated according to local clinical practice and evaluated over a treatment period of 4 weeks.
4. Fourteen patients were enrolled in the evaluation.
5. In the majority of the cases the sealant was used as an adjunctive therapy to negative pressure wound therapy.
6. By the final evaluation, the periwound region was healthy or improved in 90% of cases.

- The importance of managing the moisture content of wounds with respect to areas of vulnerable tissue, with particular emphasis on the protection to periwound skin, which may be damaged by proteolytic enzymes present in exudate from chronic wounds
- Maintaining a dressing *in situ* on difficult to dress areas associated with dressings on the feet and, in particular, maintaining an effective seal with NPWT

Aims

The primary objectives of this preliminary study were to evaluate the role of a soft silicone sealant in protecting the periwound region and providing an aid to the conservation of wound interface integrity. Secondary objectives were to evaluate the level of pain associated with dressing changes, investigator opinion of the sealant’s performance and any adverse events. No hypothesis testing was planned for this descriptive investigation.

Methods

The investigation was designed as a single-centre, open, non-randomised case series. In- and out-patients attending a specialist podiatry clinic with active DFUs who, in the opinion of the investigators and in line with the manufacturer’s instructions, were suitable for treatment with the soft silicone sealant, were enrolled.

Each participant was treated according to local clinical practice and evaluated over a treatment period of 4 weeks. Baseline participant demographic data and wound history were recorded at the first consultation.

Assessments for the purposes of this study were undertaken weekly during the study period and the results recorded, or until the ulcer healed, whichever occurred first. The following variables were assessed by qualitative visual assessment by the investigators, unless stated otherwise:

- Condition of periwound skin; rated as healthy, maceration, excoriation, or eczematous
- Pain severity reported by participants before, during and after dressing change using a validated visual analogue scale ranging from zero (no pain) to 100 (worst pain ever) (Harms-Ringdahl et al, 1986)

- Adverse events

All participants received traditional adjunctive wound care as part of their treatment (debridement and offloading appropriate for their foot and wound type). Systemic antibiotics were used concomitantly if judged necessary by the investigators. Dressing changes were undertaken according to local clinical practice (usually three times per week).

Photographs were taken during dressing removal and after cleansing and/or debridement.

At the final dressing change for each case, the investigators rated (“very good”, “good”, “poor”, “very poor”) each of the following parameters: (i) ease of application; (ii) ease of removal of dressing; (iii) condition of periwound skin; (iv) pain levels at removal; (v) comfort of sealant during use; (vi) adherence (or lack of) to periwound region.

Data are presented in a descriptive manner. All efficacy endpoints are summarised by visit number (visits 1–4).

It was agreed by the local clinical governance committee that research ethics committee approval was not required for this study because it was an in-market evaluation of a CE-marked dressing in accordance with its instructions for use.

Results

Fourteen patients (median age, 65 years [range 38–88]; 10 men) with diabetes type 2 and active foot wounds were enrolled in the evaluation. In the majority of the cases (12/14) the sealant was used as an adjunctive therapy to NPWT; in the other two cases NPWT was contra-indicated and the product was used in conjunction with conventional wound care products for high levels of wound exudate. Group mean wear time per application was 3 days and median treatment duration was 18 days (range 6–40).

The presence of wound exudate, ranging from moderate to high levels, was recorded in 94% of the wound assessments. At baseline, 68% of wounds had unhealthy periwound skin; by the final evaluation the periwound region was healthy or improved in 90% of cases (*Figure 1*).

No adverse events were reported during this evaluation.

Application

The sealant was found to be easy to prepare. The initial adhesion of the sealant to both the skin and dressing – and its ability to fill crevices – were all rated very highly by the investigators. The adherence of the dressing during wear was generally rated “very good” or “good” (Figure 2).

Removal

Ease of dressing removal and the sealant were reported to be “very good” or “good” in more than 98% of the procedures (Figure 3). On removal of the sealant, all patients found pain minimisation was “very good” or “good” and mean pain scores reduced to less than 5/100 by visit 4 (Figure 4). The comfort of the sealant was rated very highly by all patients (Figure 3).

Overall evaluation

The investigators found the soft silicone sealant easy to apply in the majority of applications (>97%). At the end of the treatment period for each case, the investigator rated the overall experience of using the soft silicone sealant; the majority of ratings were either “very good” or “good” (Figure 5).

Discussion

This article concentrates on an adjunctive wound care product that assists in meeting many of the primary requirements of the ideal dressing described by Thomas (2008). Overall, the parameters assessed with respect to the efficacy of the soft silicone sealant were scored highly when used in this patient population.

The sealant was used predominantly in conjunction with NPWT in this series. NPWT is becoming a more regular part of treatment regimens for DFUs, particularly following the work of Armstrong and Lavery (2005) and Blume et al (2008), which demonstrated the modality’s efficacy when used in partial amputation wounds. More recently, NPWT has been used following hydro-surgical wound debridement (Chadwick et al, 2009). Hydro-surgical or other radical debridement techniques often result in wounds with irregular edges in anatomically complex areas; it can be a challenge in these wounds to create and

maintain a seal to deliver NPWT. Loss of this seal will cause extravasation of fluid, resulting in periwound maceration and an inability of the NPWT therapy device to function properly. In the study by Armstrong and Lavery (2005), 19.4% (6/31) patients experienced periwound maceration.

The soft silicone sealant used in the present series helped to achieve a good NPWT seal and avoid leakage (see Case Study 1). The

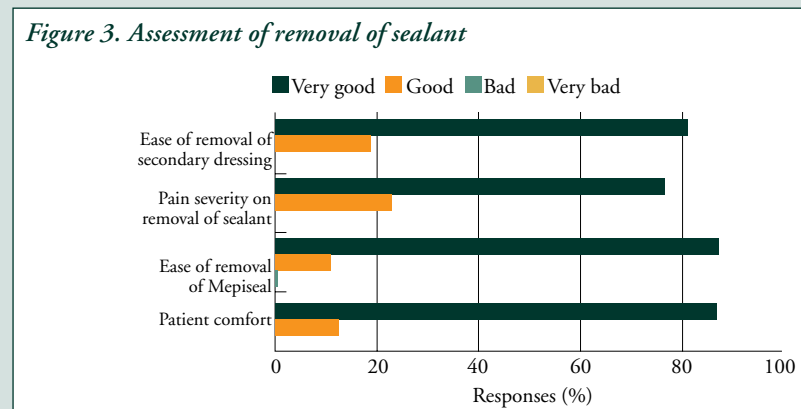
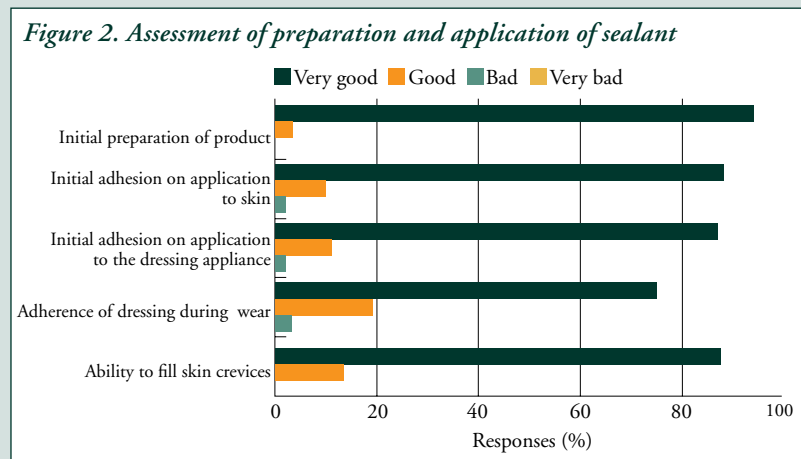
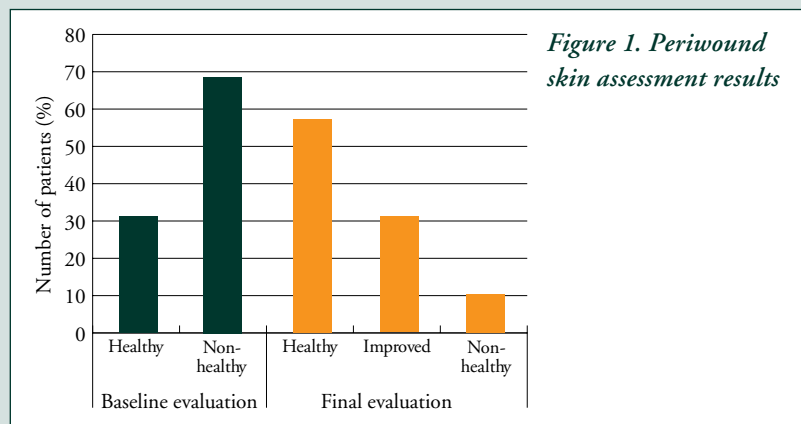


Figure 4. Assessment of pain on application and removal of sealant

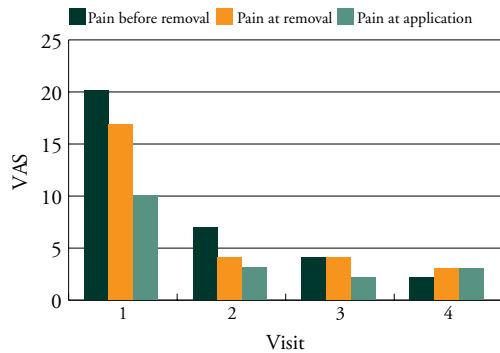
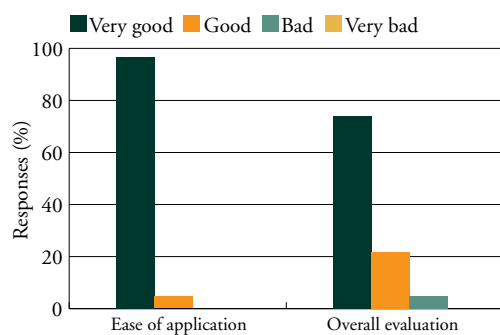


Figure 5. Overall investigator evaluation of sealant



investigators noted anecdotally that the sealant was easier and quicker to apply than the thin hydrocolloid strips that have been used previously in the clinic, meaning that the sealant reduced application time resulting in saved practitioner time. The thin hydrocolloid strips tend to occlude wound edges and have a tendency to cause maceration to the periphery of the wound. The lack of maceration observed in this series suggests that such problems can be prevented by using the soft silicone sealant, thereby reducing overall treatment costs.

The sealant was also used in conjunction with traditional wound care methods in wounds where periwound maceration was identified as a barrier to wound healing. This proved particularly useful in areas where normal moisture management products, such as super-absorbers, could not be used (due to anatomical difficulties or size of dressing; see *Case Study 2*).

Although pain is not traditionally recognised as a problem in DFUs given that many patients

CASE STUDY 1

Mrs J (type 2 diabetes, angina) underwent angioplasty of the left leg in 2010. She developed a neuro-ischaemic ulcer on her left 5th metatarsal phalangeal joint with extensive bone and soft tissue infection. She was on ertapenem and ceftazidime IV antibiotics but, due to the extent of bone infection, Mrs J was referred for amputation of the 5th toe and metatarsal. She had constant high levels of pain managed with opiates.

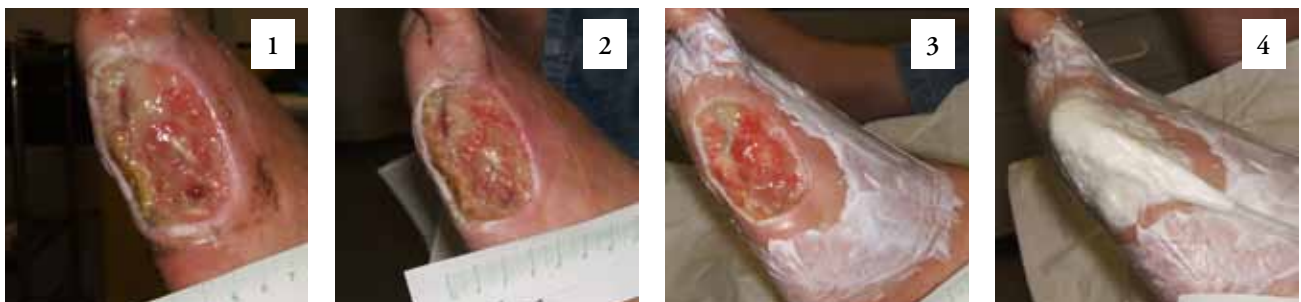Following surgery, the wound measured 65 mm × 35 mm in area with exposed tendon and bone palpable. Negative pressure wound therapy was commenced (Picture 1).

Mepiseal was used around the surrounding skin to protect from maceration and to aid adhesion of the seal. Obtaining a good seal on the foot can be very challenging particularly around the toe area. Mepiseal helped to achieve a good seal around the base of the fourth toe very easily.

At the first dressing change (Picture 2) there was less maceration to the wound periphery and the seal had been maintained. Mrs J had very high levels of pain and contact sensitivity but she reported that the dressing was comfortable between dressing changes and removal and application of the dressings were not uncomfortable.

During the 4 weeks of negative pressure wound therapy Mepiseal was used to aid the seal on the dressing and protect the surrounding skin. There were no problems between dressing changes with the seal breaking. As the Mepiseal is flexible it moves with the film dressing, thereby preventing friction and loosening of the dressing so helping to achieve optimum therapy by maintaining the seal.

At the discontinuation of therapy, the wound was 100% granulating covering the previously exposed tendon and had reduced in size to 45 mm × 25 mm.



have neuropathy, recent work by Bradbury and Price (2011) showed that 86% of their population with DFUs had some ulcer-related pain. They also reported that pain was at its worse during dressing changes and while wearing footwear. Pain in DFUs can impact negatively on a person's quality of life (Ribu et al, 2006; Bengtsson et al, 2008).

The pain scores in the present case series reduced dramatically during the treatment period, suggesting a positive role for reducing pain at dressing removal and application by use of the soft silicone sealant.

Conclusion

The soft silicone sealant described here, used in conjunction with NPWT and other treatment regimens, is designed to protect periwound skin by avoiding maceration as a result of preventing exudate leakage. The sealant is easy and quick to apply and, in the case of NPWT, the practitioners felt it was easier to

apply and enhanced the seal, compared to the hydrocolloid strips, which have been used previously in the clinic.

Data on the effect of moisture-related skin changes on treatment costs are difficult to find, and the authors are unaware of any dressing studies specifically focused on this area. It is not unreasonable to assume, however, that secondary damage caused in this way will delay healing and extend treatment times – with obvious financial implications for dressing usage, practitioner time and, potentially, extended periods of hospitalisation. It will also have a negative impact on the patient's quality of life. If the skin changes also contribute to the development of infection, there may be additional costs for systemic antimicrobial therapy.

As in many areas of clinical practice, prevention of moisture-related skin changes is better – and cheaper – than cure. Furthermore, the soft silicone sealant described here aided in the management of patients' ulcer-related pain. n

CASE STUDY 2

Mr M was referred to the authors' diabetic foot clinic with chronic neuropathic ulceration to his right 1st toe, which had been present for 12 months.

Mr M had no evidence of peripheral arterial disease but had venous disease resulting in gross oedema to both limbs. He also had profound neuropathy present in both feet.

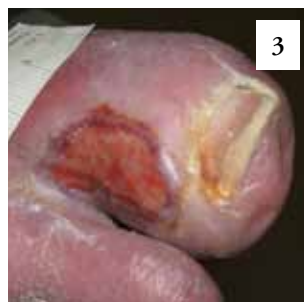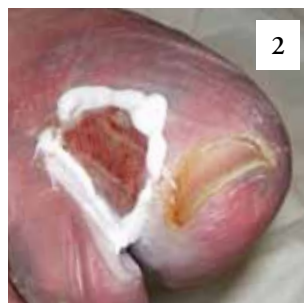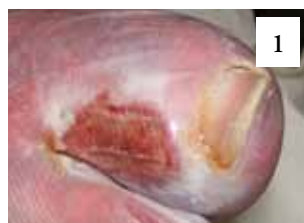The wound bed was clean and granulating and there were no signs of soft tissue infection or underlying osteomyelitis. A protease modulator dressing was started and there was slight improvement, but the periwound remained macerated.

Mepiseal was used around the wound edges and surrounding skin to help protect and prevent further damage. The dressing was then placed onto the wound bed and covered with a foam dressing and bandage.

After 2 weeks using Mepiseal, the maceration had resolved and the surrounding skin was healthy (Picture 3).

At dressing changes, the Mepiseal was easily removed and reapplied. Mr M reported that the dressing stayed in place between dressing changes and that before using the Mepiseal his dressing had a tendency to slip, due to the position of the ulcer.

Mepiseal was used at each dressing change until exudate levels had reduced. The ulcer went onto heal.



Abbotts J (2010) Patients' views on topical negative pressure: 'effective but smelly'. *Br J Nurs* 19: S37–41

Armstrong DG, Lavery LA, Diabetic Foot Study Consortium (2005) Negative pressure wound therapy after partial diabetic foot amputation: a multicentre, randomised controlled trial. *Lancet* 366: 1704–10

Bengtsson L, Jonsson M, Apelqvist J (2008) Wound-related pain is underestimated in patients with diabetic foot ulcers. *J Wound Care* 17: 433–5

Blume PA, Walters J, Payne W et al (2008) Comparison of negative pressure wound therapy using vacuum-assisted closure with advanced moist wound therapy in the treatment of diabetic foot ulcers: a multicenter randomized controlled trial. *Diabetes Care* 31: 631–6

Boulton AJ, Vileikyte L, Ragnarson-Tennvall G, Apelqvist J (2005) The global burden of diabetic foot disease. *Lancet* 366: 1719–24

Bradbury S, Price PE (2011) Diabetic foot ulcer pain (part 1): the hidden burden. *EWMA Journal* 11: 11–22

Chadwick P (2008) The use of sorbion sachet S in the treatment of a highly exuding diabetic foot wound. *The Diabetic Foot Journal* 11: 183–6

Chadwick P, Haycocks S, Bielby A, Milne J (2009) A dynamic care pathway to coordinate the use of advanced therapy in diabetic foot ulceration. *J Wound Care* 18: 433–7

Frykberg RG (2002) Diabetic foot ulcers: pathogenesis and management. *Am Fam Physician* 66: 1655–62

Gibson D, Cullen B, Legerstee R (2009) *MMPs Made Easy*. Wounds International, London. Available at: <http://www.woundsinternational.com/made-easy/mmps-made-easy> (accessed 04.12.2012)

Harms-Ringdahl K, Carlsson AM, Ekholm J et al (1986) Pain assessment with different intensity scales in response to loading of joint structures. *Pain* 27: 401–11

Kinoshita H (1985) Effects of different loads and carrying systems on selected biomechanical parameters describing walking gait. *Ergonomics* 28: 1347–62

Mendonca DA, Papini R, Price PE (2006) Negative-pressure wound therapy: a snapshot of the evidence. *Int Wound J* 3: 261–71

Ribu L, Rustoen T, Birkeland K et al (2006) The prevalence and occurrence of diabetic foot ulcer pain and its impact on health-related quality of life. *J Pain* 7: 290–9

Upton D, Solowiej K, Hender C, Woodyatt KY (2012) Stress and pain associated with dressing change in patients with chronic wounds. *J Wound Care* 21: 53–8

Wild S, Roglic G, Green A et al (2004) Global prevalence of diabetes: estimates for the year 2000 and projections for 2030. *Diabetes Care* 27: 1047–53

Whitney J, Phillips L, Aslam R et al (2006) Guidelines for the treatment of pressure ulcers. *Wound Repair Regen* 14: 663–79

Winter GD (1962) Formation of the scab and the rate of epithelization of superficial wounds in the skin of the young domestic pig. *Nature* 193: 293–4

Thomas S (2008) The role of dressings in the treatment of moisture-related skin damage. *World Wide Wounds*. Available at: <http://www.worldwidewounds.com/2008/march/Thomas-Maceration-and-the-role-of-dressings.html> (accessed 04.12.2012)