

Using an activated charcoal dressing with silver for malodour, infection and overgranulation in diabetic foot ulcers

Samantha Haycocks, Paul Chadwick

Citation: Haycocks S, Chadwick P (2014) Using an activated charcoal dressing with silver for malodour, infection and overgranulation in diabetic foot ulcers. *The Diabetic Foot Journal* 17: 74–7

Article points

1. Silver-containing antimicrobial dressings play an important role in wound management; ACTISORB® Silver 220 (Systagenix) is one such dressing and is designed to reduce infection and wound malodour in patients with critically colonised or infected wounds.
2. The authors present three cases (taken from a larger series) describing the successful use of ACTISORB Silver 220 in people with infected diabetic foot wounds with malodour and/or overgranulation.
3. When prescribing silver dressings it is important to follow best practice; the rationale for use should be fully documented and a review schedule detailed, along with a record of the physical and psychological benefits to patients, to demonstrate quality care.

Key words

- ACTISORB Silver 220
- Charcoal dressing
- Malodour
- Overgranulation
- Silver dressing

Authors

Samantha Haycocks is Advanced Podiatrist, Salford Royal (NHS) Foundation, Salford. Paul Chadwick is Principal Podiatrist, Salford Royal (NHS) Foundation, Salford.

Silver-containing antimicrobial dressings play an important role in wound management. ACTISORB® Silver 220 (Systagenix) is a dressing comprising an activated charcoal layer impregnated with silver that is designed to reduce infection and wound odour in patients with critically colonised or infected wounds. The following cases, taken from a larger case series (Wounds UK, 2014; in press), describe the use of ACTISORB Silver 220 in people with infected diabetic foot wounds, with malodour and/or overgranulation.

Silver-containing antimicrobial dressings have been available for many years and are now an integral part of the wound management armamentarium. The widespread uptake of silver has been driven by its use in antimicrobial dressings (Leaper, 2006). As with any intervention, judicious use of silver dressings is central to ensuring sustainability of these products.

Topical antiseptics, such as silver, have a low risk of bacterial resistance. As a result, silver has the potential to play an important part in controlling bioburden while limiting exposure to antibiotics and reducing the risk of development of further antibiotic resistance (International Consensus, 2012).

Silver dressings may be used as an antimicrobial barrier in wounds at high risk of infection or reinfection. They may also be used to prevent entry of bacteria at medical device entry/exit sites, such as around percutaneous gastrostomy tubes (International Consensus, 2012), while silver dressings may have the potential to reduce the development of overgranulated tissue (Leak, 2002).

Importance of appropriate dressing selection for diabetic foot ulcers

When choosing a silver dressing, it is important to balance the needs of the patient, the wound and the environment, and to consider how the overall characteristics of the selected silver dressing will meet the other needs of the patient.

Infection

Recognising infection in patients with diabetic foot ulcers is one of the most important steps in the assessment. It is at this crucial stage that practitioners have the potential to prevent progression from mild infection to more severe infection, helping to reduce the risk of amputation (Wounds International, 2013). Therefore early and aggressive treatment is important. Systemic antibiotic therapy should be started immediately in the presence of clinical signs of infection using an empiric approach. However, topical antimicrobials do play an important adjunctive role in the diabetic foot and may be beneficial where there are concerns regarding reduced antibiotic tissue penetration (e.g. poor vascular supply) to manage the local symptoms of infection such as exudate, malodour or even pain. They may also have a role to play in non-healing wounds where the classic signs and symptoms of infection are absent, but there is a clinical suspicion of increased bacterial bioburden.

In these situations topical antimicrobials (either alone or as an adjunct to systemic therapy) have the potential to reduce bacterial load and may protect the wound from further contamination (Wounds International, 2013). In addition, treatment at an early stage may prevent spread of infection to deeper tissues.

Malodour

Malodour in wounds healing by secondary intention is associated with necrotic tissue that supports the growth of anaerobic bacteria, and the presence of volatile fatty acids in the wound (White, 2013).

Application of dressings that block the odour, such as charcoal, or dressings that are antimicrobial, will reduce or remove bacteria from the wound.

Other contributory factors to malodour are infection and stagnant exudate. Infected wounds tend to produce high levels of exudate and there may be considerable odour, which may be unpleasant and distressing for the patient (Murray, 2005). In such cases, a combination of a highly absorbent secondary dressing and a charcoal dressing to manage the odour would be preferable. Where there is also evidence of infection, the addition of silver can address both the odour and the underlying cause.

Exudate becomes malodorous if it is allowed to collect and stagnate within the wound. The use of a dressing with good conformability may help to prevent the formation of pools of exudate where bacteria might flourish beneath the dressing. This may be particularly challenging if the patient is weight-bearing (Murray, 2005).

Overgranulation

Overgranulation (or hypergranulation) is a common problem in chronic wounds, especially diabetic foot ulcers. It appears as an excess of friable, red and often shiny granulation tissue, which as well as increasing the patient's risk of infection, will prevent or slow epithelial migration across the wound and thus delay wound healing. Treatment options include surgical excision or the use of foams and silver dressings. However, there is limited evidence to suggest which one is most effective (Krishnaprasad et al, 2013).

ACTISORB® Silver 220 dressing

ACTISORB® Silver 220 (Systagenix) is a sterile primary dressing comprising an activated charcoal cloth, impregnated with silver within a spun bonded perforated nylon sleeve. This allows wound exudate to move freely through to a secondary dressing, while facilitating dressing removal by minimising adherence to the wound. It may be used in the treatment of most types of chronic wounds, but is particularly recommended for the management of malodorous, infected wounds.

When applied to a wound, the active charcoal layer in ACTISORB Silver 220 absorbs bacteria and locally released toxins as well as the volatile amines and fatty acids responsible for wound odour (Kerihuel, 2010).

The silver in ACTISORB Silver 220 has been shown not to cause any detrimental effect to cell growth, while providing an antimicrobial effect (Nisbet, 2011). As bacteria and endotoxins are absorbed by the activated charcoal, they are destroyed by the silver within the dressing, preventing them from returning to the wound (Verdu Soriano et al, 2004).

Laboratory testing has indicated that the dressing is effective against many common wound pathogens, including methicillin-resistant *Staphylococcus aureus* (Furr et al, 1994; Jackson, 2001). *Staphylococcus aureus* is the major pathogen implicated in diabetic foot infections (Rich and Lee, 2005) and therapies aimed at aerobic Gram-positive cocci may be sufficient in patients with mild-to-moderate infections who have not already received antibiotic therapy (Lipsky et al, 2006).

Whether ACTISORB Silver 220 is used to control odour in wounds with increased bioburden, to prevent infection or to manage overgranulation, the rationale should be fully documented in the patient's health records and a schedule for review should be specified.

This series of cases describes the use of ACTISORB Silver 220 on infected wounds, malodour and/or overgranulation in patients with diabetic foot ulcers.

Case one

Mr S is a 62-year-old man with post-traumatic paraplegia, type 2 diabetes (HbA_{1c} 43 mmol/mol) and peripheral arterial disease, and a history of neuropathy. He had a pressure ulcer on his right lateral malleolus for 9 months; this was protected with a soft cast. Previous therapies included Biatain® (Coloplast) and Flaminal® (Crawford Healthcare). The wound measured 31 mm × 24 mm with punched out granulation and a crescent of slough, with non-healing friable tissue and moderate exudate (*Figure 1a*). Wound swab showed *Pseudomonas* and mixed skin flora.

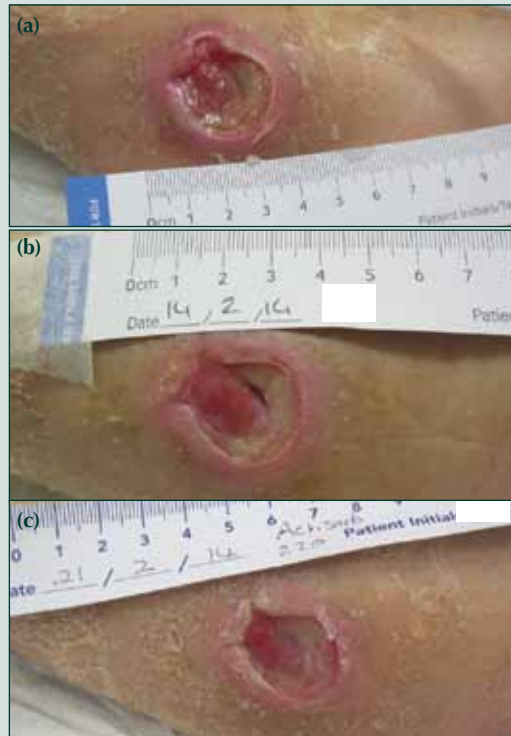
Malodour was noticed at dressing change and this, along with the infection, led to a decision to use ACTISORB Silver 220 dressing, changed every 2 days. A secondary dressing of tubegauze was applied.

At week 1, there was still some slight wound malodour. The ulcer had reduced in size (20 mm × 22 mm) and the exudate level and bioburden had decreased (*Figure 1b*). The dressing had stayed in place and there was no pain on removal. The

“This series of cases describes the use of ACTISORB® Silver 220 (Systagenix) on infected wounds, malodour and/or overgranulation in patients with diabetic foot ulcers.”

“At week 4 [following commencement of a treatment regimen including ACTISORB® Silver 220 (Systagenix)], there was no exudate or malodour, indicating a reduction in wound bioburden.”

Figure 1. (a) At presentation, Mr S’ wound showed punched out granulation and a crescent of slough, with non-healing friable tissue and moderate exudate. (b) At week 1, the ulcer reduced in size and the exudate level and bioburden decreased. (c) At week 2, and the wound was smaller and shallower.



clinician was satisfied with the ease of application and removal of the dressing.

There was no malodour at week 2, and the wound was smaller (19mm × 20mm) and shallower (Figure 1c). The decision was made to continue with the dressing to manage the bioburden, and review in 7 days. A soft cast was used for protection.

Further improvements in the wound were observed at week 3, with an increase in granulation. The size was unchanged, and the dressing regimen was continued.

At week 4, there was no exudate or malodour, indicating a reduction in wound bioburden, and the wound measured 19mm × 18mm. The decision was made to switch to foam dressing and continue with a soft cast.

Case two

Mr F is a 70-year-old man with type 2 diabetes (HbA_{1c} 34mmol/mol) and Charcot neuroarthropathy. He reported banging his big toe, which led to onychocryptosis with overgranulation and subsequent

ulceration. The plantar ulcer measured 20mm × 34mm and had been present for 4 weeks. Mr F had received oral antibiotics (co-amoxiclav 625mg, three times daily) and the wound had been debrided and the nail spike cut back. Healing had been stalled for 2 weeks (Figure 2a).

Mr F’s wound had been infected for 2 days, with cellulitis and malodour. Swabs were taken for microbiology. It was decided to use ACTISORB Silver 220 dressing to manage malodour as well as aiding reduction in bacterial burden in conjunction with co-amoxiclav. The dressing was changed every 2 days, with a secondary dressing of tubegauze.

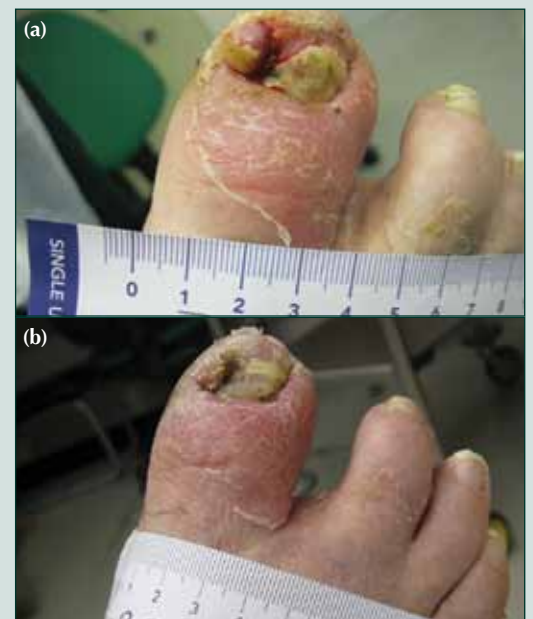At day 6, the overgranulation had improved slightly, with a reduction in exudate, infection and bleeding. There was no pain on dressing removal, which had stayed in place during wear. The dressing regimen and antibiotics were continued.

By day 10, there had been a significant reduction in overgranulation (Figure 2b). Bleeding had reduced and infection and exudate had improved. Mr F was due to have nail surgery, so the dressing was discontinued.

Case three

Mr B is 80 years old, has diabetes, a history of ulceration on both feet and Charcot neuropathy

Figure 2. (a) At presentation, Mr F’s wound had been stalled for 2 weeks. (b) At day 10, there had been a significant reduction in overgranulation, bleeding, signs of infection and exudate.



on his right foot. Pressure on the right foot had led to callus formation and ulceration on the inner longitudinal arch. He had received debridement to remove the callus and an offloading insole to reduce plantar pressures.

Mr B complained that his ulcer “stinks” and was reluctant to leave the house due to the smell. A fishy odour was noticeable on examination, and there were signs of an increase in bioburden, with a change in granulation colour observed. The ulcer measured 16mm × 10mm, and was of moderate depth with callused edges, slough, periwound maceration and moderate exudate (*Figure 3a*).

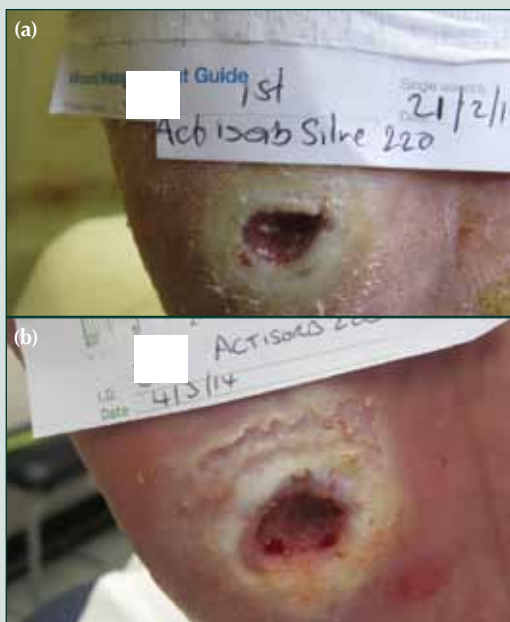Mr B reported no pain. Because of the malodour and critical colonisation, the decision was made to use ACTISORB Silver 220 dressing, with a K-Band® (Urgo Medical) secondary dressing, changed every 2–3 days.

Mr B was seen in clinic after 11 days. The wound had reduced in size to 12mm × 10mm and the exudate volume was now minimal (*Figure 3b*).

Signs of infection had reduced. The dressing had stayed in place and there was no pain on removal. The clinician was highly satisfied with the ease of removal of the dressing.

Mr B reported the malodour was much improved.

Figure 3. (a) Mr B’s wound was of moderate depth with callused edges, slough, periwound maceration and moderate exudate at presentation. (b) After 11 days, the wound had reduced in size and exudate reduced.



As there were still signs of infection, it was decided to continue with the ACTISORB Silver 220 dressing. Mr B returned 10 days later. The ulcer size was unchanged and periwound maceration present. The exudate level had increased to moderate. There was no odour or infection and the granulation had improved, so the dressing was discontinued.

Conclusion

The three cases demonstrate how the appropriate use of an activated charcoal dressing with silver can control bioburden and malodour, as well infection with overgranulation in patients with diabetic foot ulceration. The clinicians reported that ACTISORB Silver 220 dressing was easy to apply and stayed in place during wear with reductions in pain, malodour and signs of infection seen at 7–14 days.

Malodour has a significant impact on quality of life, and patients often experience anxiety when around others; it can lead to depression, poor body image and isolation, with the inevitable impact on social and family relations (Van Toller, 1994). Poor symptom management (e.g. pain, exudate) can cause patients to become non-concordant with therapy (Vedhara et al, 2010), increasing demands on healthcare budgets. Total NHS spending on ulceration and amputation in people with diabetes in England in 2010–11 is estimated at £639 million–£662 million, equivalent to 0.6%–0.7% of NHS expenditure (Kerr, 2012). Treatment of malodorous wounds should, therefore, address both physical and psychological factors.

Effective management (doing the right thing at the right time in the right way to the right person and having the best possible outcomes) can help to reduce healthcare costs and improve patient quality of life. This includes the need to select appropriate wound dressings based on accurate assessment and diagnosis. For those with wound malodour, the use of a charcoal dressing can relieve distress and, when combined with silver, assist in the management of infection and other contributory factors.

When prescribing silver dressing it is important to follow best practice, as detailed in the International Consensus (2012). The rationale for using silver dressings should be fully documented in the patient’s notes and a review schedule should be detailed, along with a record of the physical and psychological benefits to patients, to demonstrate quality care. ■

Furr JR, Russell AD, Turner TD, Andrews A (1994) Antibacterial activity of Actisorb Plus, Actisorb and silver nitrate. *J Hosp Infect* **27**: 201–8

International Consensus (2012) *Appropriate Use Of Silver Dressings In Wounds. An Expert Working Group Consensus*. Wounds International, London

Jackson L (2001) Use of a charcoal dressing with silver on an MRSA infected wound. *Br J Community Nurs* **6**(Suppl 2): 19–26

Kerihuel JC (2010) Effect of activated charcoal dressings on healing outcomes in chronic wounds. *J Wound Care* **19**: 208–15

Leaper DJ (2006) Silver dressings; their role in wound management. *Int Wound J* **3**: 282–94

Leak K (2002) PEG site infections: a novel use for Actisorb Silver 220. *Br J Commun Nurs* **7**: 321–5

Lipsky BA, Berendt AR, Deery HG et al (2006) Diagnosis and treatment of diabetic foot infections. *Plast Reconstr Surg* **117**(Suppl 7): 212S–238S

Murray F (2005) Malodour in diabetic foot wounds. *The Diabetic Foot Journal* **8**: 122–32

Kerr M (2012) *Foot Care For People With Diabetes In The NHS In England: The Economic Case For Change*. Factsheet No. 37. NHS Diabetes, London. Available at: <http://bit.ly/1knaaGh> (accessed 27.05.14)

Nisbet L, Turton K, Cullen B, Foster S (2011) The beneficial effects of a non-releasing silver containing wound dressings on fibroblast proliferation. Poster presented at Wounds UK, Harrogate: 14–16 November

Krishnaprasad IN, Soumya V, Abdulgafoor S (2013) Management of overgranulation in a diabetic foot ulcer. A clinical experience. *Indian Journal of Physical Medicine and Rehabilitation* **24**: 19–22

Rich J, Lee JC (2005) The pathogenesis of *Staphylococcus aureus* infection in the diabetic NOD Mouse. *Diabetes* **54**: 2904–10

Van Toller S (1994) Invisible wounds: the effects of skin ulcer malodours. *J Wound Care* **3**: 103–5

Verdú Soriano J, Rueda López J, Martínez Cuervo F, Soldevilla Agreda J (2004) Effects of an activated charcoal silver dressing on chronic wounds with no clinical signs of infection. *J Wound Care* **13**: 419–23

White R (2013) Wound malodour and the role of Actisorb Silver 220. *Wounds UK* **9**: 101–4