

# Injectable liquid silicone to reduce plantar pressure: A case report

Matthew Malone, Stuart Metcalfe,  
Abdulaziz Al Gannass, Frank Bowling

The authors report a case in which high plantar pressures in a person with peripheral diabetic neuropathy and a history of metatarsal head associated ulceration were reduced using injection of liquid silicone as a metatarsal fatty pad substitute. Evidence for this indication are discussed. In combination with other offloading and pressure redistributing modalities, injectable liquid silicone represents another modality for preventing reulceration in the diabetic foot.

**M**etatarsal fatty pad atrophy (FPA) is common in the general population. The condition frequently increases the prominence of the metatarsal heads and increases localised plantar pressures. For people with diabetes the increased plantar pressures associated with metatarsal FPA, in combination with peripheral neuropathy, can result in plantar ulceration (Masson et al, 1989).

Treatments used for FPA include metatarsal pads (Hodge et al, 1999), rocker-sole footwear (Brown et al, 2004), bespoke footwear (Uccioli et al, 1995) and total-contact foot orthoses (Colagiuri et al, 1995). More recently, the injection of liquid silicone (LS) as a soft-tissue metatarsal fatty pad substitute has been reported (Balkin, 2005).

In the following case, the authors report the use of injectable LS in a person with diabetic peripheral neuropathy, prominent metatarsal heads and a history of ulceration.

## Case report

Ms B – an obese (BMI 34 kg/m<sup>2</sup>) 50-year-old woman with insulin-treated type 2 diabetes

(diagnosed in 2000) and significant peripheral neuropathy – had a history of chronic ulceration to her right 2nd, 4th and 5th metatarsal heads, including osteomyelitis in the right 5th metatarsal head in 2009.

Assessment of the foot revealed metatarsal FPA. The 2nd, 4th and 5th metatarsal heads were subluxed and plantarflexed and there were signs of an intrinsic minus foot type (i.e. retraction of the lesser digits along with plantarflexed metatarsal heads, which often occurs in response to neuropathic changes [Bernstein, 2003]). There was no restriction of movement around the right sub-talar joint, mid-tarsal joint or the 1st metatarsalphalangeal joint (MTPJ). On standing, hindfoot valgus was detected, as was a navicular drop of 10 mm, forefoot abduction and a valgus rotation of the 1st MTPJ.

On review of Ms B's gait (both visually and quantitatively using the F-Scan Mobile [Tekscan, Boston, MA]), signs of increased late-stance pronation were evident. As a result, forefoot pressures moved rapidly across all the metatarsal heads causing shear stress. The

## Article points

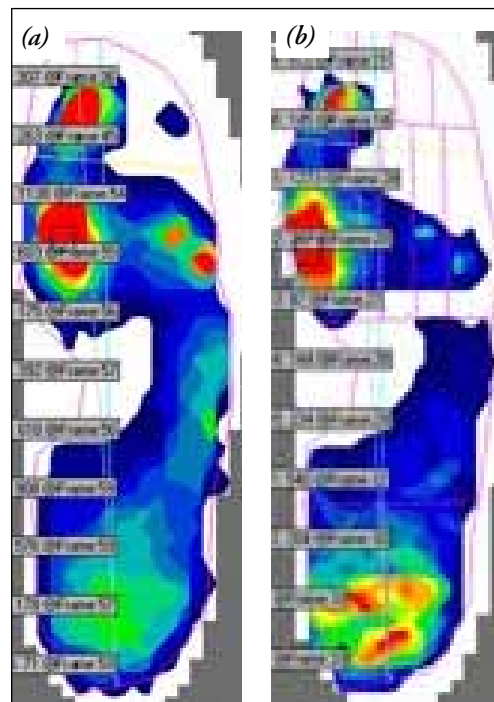
1. Metatarsal fatty pad atrophy with prominent metatarsal heads causes an increase in plantar pressure.
2. Injectable liquid silicone acts as a soft tissue dermal filler, replacing the atrophied metatarsal fatty pad and reducing plantar pressures.
3. In this case report injectable liquid silicone was used to reduce plantar pressures in a person with diabetes with recurrent plantar ulceration.

## Key words

- Injectable liquid silicone
- Offloading
- Plantar pressure
- Plantar ulceration

Author details can be found on the last page of this article.

*Figure 1. Visual representations of Ms B's right foot plantar pressure distribution (higher pressure is represented by reds, lower pressure by blues; F-Scan Mobile; Tekscan). Readings (a) pre- and (b) post-injectable liquid silicone treatment.*



increased pronation moment continued until propulsion, resulting in reduced 1st MTPJ dorsiflexion along with a valgus rotation of the metatarsal and interphalangeal joints (IPJs). These findings accounted for the extremely high pressures seen under the 1st metatarsal head and IPJs and the high pressures around the prominent dropped 2nd, 4th and 5th metatarsal heads (Figure 1a; Table 1).

Although high pressures at the 1st metatarsal head and IPJ were detected, there was no FPA present under the 1st metatarsal head and no history of ulceration at the site. Excessive pressures at the 1st MTPJ and IPJ were attributed to the altered mechanics of

the foot and sagittal plane dysfunction that arose during propulsion.

Due to the prominence of the right 2nd, 4th and 5th metatarsal heads, and Ms B's history of ulceration, the decision was taken to use a soft-tissue dermal filler in the form of medical-grade injectable LS (350-centistoke injectable silicone; Innopad, OsteoTec, Christchurch) at these three sites to manage some of the excess plantar pressures.

#### Injectable liquid silicone intervention

Prior to injection, informed written consent was obtained from Ms B and the risks and benefits of the procedure explained. At the time of the procedure Ms B had been ulcer-free for >3 months.

Ms B's foot was cleansed with chlorhexidine spray. Due to Ms B's peripheral neuropathy, no local anaesthesia was necessary.

LS (1 mL) was injected underneath the 2nd, 4th and 5th metatarsal heads, one site per week over three consecutive weeks (a total of 3 mL). Following each injection Ms B was asked to limit her weight-bearing activities for several days. A postoperative sandal with 6 mm memory foam was provided to reduce external stresses around the injection site.

One week after the final injection in the series had been completed, Ms B's plantar pressures were retested using the F-Scan Mobile. Plantar pressures were found to have been reduced by approximately 64% at the three injection sites (Table 1; Figure 1).

Injectable LS was not used as stand-alone treatment to address Ms B's high plantar

**Table 1. Ms B's plantar pressures (measured using the F-Scan Mobile; Tekscan) at three sites before and after injectable liquid silicone (ILS).**

		Plantar pressure (KPa)		Change in plantar pressure from baseline to post-ILS	
		Baseline	Post-ILS	Actual change (KPa)	Percentage change (%)
Metatarsal head	5 <sup>th</sup>	618	234	-384	-62
	4 <sup>th</sup>	392	144	-248	-63
	2 <sup>nd</sup>	603	207	-396	-66

pressure. In addition, Ms B received custom-made foot orthosis and was advised to wear them in a pair of sports training shoes.

## Discussion

### Evidence for use

A long-term study on the injection of LS in cadaveric models showed that the compound is histologically stable with biologically tolerable responses (Balkin, 2005). Further studies report no significant adverse events (e.g. inflammation, infection, allergy, or granulomas) following the injection of LS *in vivo* (Masson et al, 1989; Wallace et al, 2004).

Balkin et al (1972) first suggested the injection of LS to reduce plantar pressures. In 1991, 350-centistoke injectable LS for the prevention of diabetic foot ulceration was approved for marketing in Europe (Balkin and Kaplan, 1991). As such, ethical approval is not needed for use of this modality in clinical practice.

The only randomised, double-blinded, placebo-controlled study to assess the efficacy of this modality specifically in the diabetic foot was van Schie et al (2000). The authors recruited 28 people with diabetes and peripheral neuropathy who were randomised to receive plantar LS injection or plantar saline injection (controls). Plantar pressure measurements were taken at baseline and again at 3, 6 and 12 months post-injection and revealed a significant reduction in plantar pressures in the silicone-treated group compared with controls ( $-232$  vs  $-25$  kPa;  $P < 0.05$ ). Furthermore, plantar tissue thickness also increased in the silicone-treated group in comparison to controls (1.8 vs 0.1 mm;  $P < 0.0001$ ). A 2-year follow-up of this cohort found that 24 months after treatment the silicone-treated group had experienced an increase in plantar pressure, suggesting the need for silicone “top-ups” to maintain efficacy (van Schie et al, 2002).

### In the clinic

Before using injectable LS in the clinic, practitioners should undertake appropriate training in the technique. A thorough understanding of injectable LS technique, its actions and the possible (albeit rare)

adverse events. It is recommended that those new to the procedure be supervised by an experienced practitioners initially. Written consent should be obtained before the procedure, and the patient should be provided with written information on the modality. Injectable LS for the management of increased plantar pressure in the diabetic foot is contraindicated in feet with active ulceration; the foot to be treated must have been continuously healed for  $>3$  months before the injection of LS is undertaken.

## Conclusions

Despite positive safety data and marketing approval the use of injectable LS for ulcer prevention among people with diabetes has not taken off to-date. Injectable LS in the diabetic foot has not been widely reported on, and although positive short-term results in the only randomised controlled trial on the modality to-date, follow-up data suggest that reductions achieved will likely require re-injection to be maintained.

This case study highlights that injectable LS alone decreased plantar pressures in the neuropathic diabetic foot with metatarsal FPA and a history of ulceration. When combined with other offloading and pressure redistributing modalities, injectable LS represents another modality in the clinician’s toolbox for preventing reulceration in the diabetic foot. ■

## Authors

*Matthew Malone is a Specialist Podiatrist and Abdulaziz Al Gannass is Director of Podiatric Surgery, both are based in the Department of Surgery, National Guard Health Affairs, King Abdulaziz Medical City, Riyadh, Saudi Arabia; Stuart Metcalfe is a Consultant Podiatric Surgeon, Podiatric Surgery Unit, Solihull NHS Care Trust, Birmingham; Frank Bowling is a Research Fellow, Central Manchester University Hospital, Manchester.*

- Balkin SW, Westin G, Wilbur M, Cozen L (1972) Plantar keratoses: treatment by injectable liquid silicone report of an 8-year experience. *Clin Orthop Relat Res* 87: 235–47
- Balkin SW (2005) Injectable silicone and the foot: a 41-year clinical and histologic history. *Dermatol Surg* 31: 1555–9
- Balkin SW, Kaplan L (1991) Silicone injection management of diabetic foot ulcers: a possible model for prevention of pressure ulcers. *Decubitus* 4: 38–40
- Bernstein RK (2003) Physical signs of the intrinsic minus foot. *Diabetes Care* 26: 1945–6
- Brown D, Wertsch J, Harris GF, et al (2004) Effect of rocker soles on plantar pressures. *Arch Phys Med Rehabil* 85: 81–6
- Colagiuri S, Marsden LL, Naidu V, Taylor L (1995) Use of orthotic devices to correct plantar callus in people with diabetes. *Diabetes Res Clin Pract* 28: 29–34
- Hodge MC, Bach TM, Carter GM (1999) Orthotic management of plantar pressure and pain in rheumatoid arthritis. *Clin Biomech (Bristol, Avon)* 14: 567–75
- Masson EA, Hay EM, Stockley I et al (1989) Abnormal foot pressures alone may not cause ulceration. *Diabet Med* 6: 426–8
- Uccioli L, Faglia E, Monticone G et al (1995) Manufactured shoes in the prevention of diabetic foot ulcers. *Diabetes Care* 18: 1376–8
- van Schie CH, Whalley A, Vileikyte L et al (2000) Efficacy of injected liquid silicone in the diabetic foot to reduce risk factors for ulceration: a randomized double-blind placebo-controlled trial. *Diabetes Care* 23: 634–8
- van Schie CH, Whalley A, Armstrong DG et al (2002) The effect of silicone injections in the diabetic foot on peak plantar pressure and plantar tissue thickness: a 2-year follow-up. *Arch Phys Med Rehabil* 83: 919–23
- Wallace WD, Balkin SW, Kaplan L, Nelson S (2004) The histologic host response to liquid silicone injections for prevention of pressure-related ulcers of the foot: a 38-year study. *J Am Podiatr Med Assoc* 94: 550–7