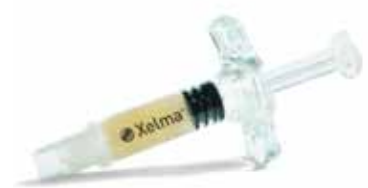

A new initiative in the treatment of hard-to-heal diabetic foot ulcers

This is a report from a satellite symposium held at the *10th Annual Conference and Exhibition of The Diabetic Foot Journal*. The meeting took place on 15 June 2009 at The Corn Exchange, Edinburgh, and was sponsored by Mölnlycke Health Care.

The purpose of this symposium was to highlight the use of Xelma in hard-to-heal diabetic foot ulcers. Xelma is a topical gel that provides a temporary extracellular matrix for cellular attachment in hard-to-heal wounds, creating a framework around which the wound healing cascade can occur. Three speakers addressed the attendees on this subject: Matthew Young (Consultant Physician, Edinburgh), Joanne McCardle (Acute Diabetes Podiatrist, Edinburgh) and Debbie Wilson (Diabetes Specialist Podiatrist, Wishaw). The symposium began with Matthew's description of Xelma's mode of action, Joanne went on to discuss the use of Xelma in the clinical setting and the positive results achieved, and Debbie described the benefits to the patient of using Xelma.



During their lifetime, it is estimated that between 12% and 25% of people with diabetes will develop a diabetic foot ulcer (Singh et al, 2005). The pathology behind this dreaded diabetic complication is the nexus of ischaemia, neuropathy and infection – factors that not only contribute to the development of a diabetic foot ulcer, but also impede its progression to healing (Edmonds et al, 2004).

Xelma (Mölnlycke Health Care, Dunstable) is a new agent for the treatment of hard-to-heal wounds that addresses structural and molecular insufficiencies at the wound site, assisting the body in initiating the wound-healing cascade and progression to complete healing.

Mode of action

Matthew Young began by discussing the importance of the extracellular matrix (ECM) in the coordination of wound healing. The ECM's central role in the healing of injured tissue is to act as a structural framework for cell adhesion. The ECM is also involved in enhancing nuclear transcription factors that result in an increase in the proteins needed to generate new tissues (Agren and Werthén, 2007).

Matthew highlighted that the structure and function of ECM proteins can be damaged by hyperglycaemia, and thus diabetes is associated with disordered or poor-quality ECM formation (Lobmann et al, 2005). *Figures 1a* and *1b* illustrate the

difference between an acellular, protein deficient wound with disordered ECM (as might be seen in a person with a chronic diabetic foot ulcer), and a wound with a dense, functional ECM that is anchoring proliferating fibroblasts and is progressing to healing. Among the former wound type, it may be necessary to address the underlying structural and molecular insufficiencies to achieve healing, one option being the use of Xelma to provide a substitute ECM.

Xelma comprises four components: (i) amelogenin, (ii) propylene glycol alginate as a vehicle, (iii) water as a filler, and (iv) trace amounts of acetic acid. Matthew described the role of amelogenin, a protein primarily

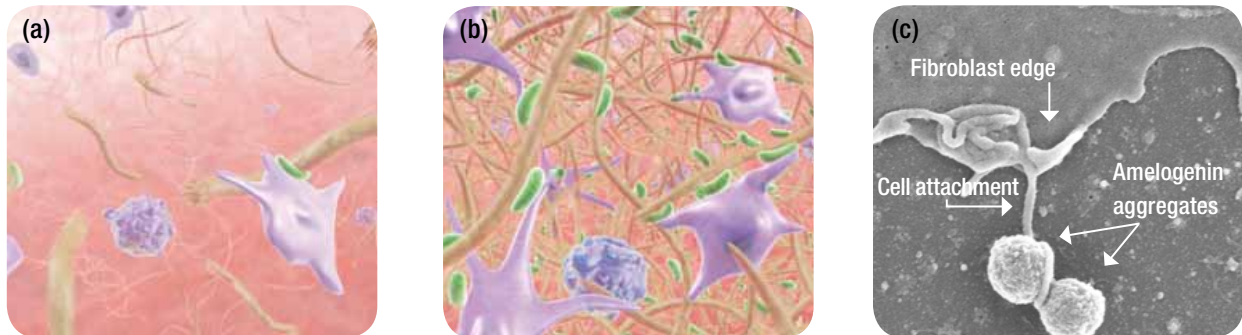


Figure 1. (a) Graphic representation of an acellular, protein deficient wound with disordered extracellular matrix, as might be seen in a person with a chronic diabetic foot ulcer. (b) Graphic representation of a wound with a dense, functional extracellular matrix that is anchoring proliferating fibroblasts and is progressing to healing. (c) An electron micrograph showing a fibroblast attaching itself to aggregated amelogenin chains forming a temporary extracellular matrix.

found in dental enamel, in Xelma: amelogenin protein chains, when applied to the wound site, aggregate into ball-shaped units at the body's pH and provide a temporary, biological, degradable ECM. At a cellular level, these amelogenin aggregates provide attachment points for fibroblasts, as the electron micrograph in *Figure 1(c)* shows. Once anchored, fibroblasts are able to proliferate at the wound site, synthesising growth factors and ECM components. When functioning properly, this process triggers the normal wound healing cascade.

Matthew concluded by saying that Xelma provides critical cell adhesion proteins that initiate wound healing when standard treatments have failed to achieve ulcer resolution.

Xelma in action

Joanne McCardle discussed the clinical aspects of treatment with Xelma. Xelma is not recommended as a first-line treatment for diabetic foot ulcers. Joanne stressed that, before considering treatment with this agent,

clinicians should revisit the basics and ensure that the patient is receiving adequate debridement, appropriate off-loading, and good infection control and blood supply. When traditional wound care has failed to heal a diabetic foot ulcer, treatment with Xelma may be considered. Indications for the type of wounds in which the use of Xelma is appropriate are those without:

- Clinical signs of infection.
- High levels of wound exudates.
- High levels of slough.

Xelma is a topical gel that should be applied to suitable wounds at weekly intervals. Weekly foot care visits should include continued sharp debridement, pressure relief and infection control in addition to Xelma application.

Xelma should be refrigerated during storage, and warmed to body temperature just prior to application. Xelma should be applied inside the wound margins using the sterile, single-use applicator. Following this, secondary dressings should be applied. Secondary dressings can be changed between weekly Xelma applications, but, Joanne stressed,

the person whose ulcer is being treated with Xelma, and any healthcare professionals or caregivers involved the day-to-day management of the ulcer, should be informed that no irrigation is to take place between appointments, to avoid any interruption of the wound healing cascade.

The manufacturer indicates continuous treatment with Xelma for no longer than 12 weeks. If the ulcer has not responded with a decrease in area within the first 6 weeks of treatment, use of Xelma should be discontinued and treatment reassessed.

Joanne reported a case series of ten hard-to-heal diabetic foot ulcers in nine people treated with Xelma (McCardle et al, 2008). Of the 10 ulcers, all but two healed or reduced in total area by the end of the 12-week treatment period. The case histories of two people successfully treated with Xelma are summarised on page 3 (*Boxes 1 and 2*). Other case series in the literature likewise demonstrate positive results using Xelma on hard-to-heal wounds (Vowden et al, 2007; Romanelli et al, 2008).

Joanne found that Xelma was easy to apply, no adverse effects were reported by patients and, in a number of cases, treatment with Xelma improved overall patient compliance with therapeutic protocol.

While the cost of Xelma (£56/0.5 ml syringe for wounds <10 cm²; £98/1.0 ml syringe for wounds 10–20 cm²) is higher than that of traditional wound care products, this must be weighed against the total cost of traditional treatments, and periods of hospitalisation, during the months, or even years, that a chronic diabetic foot ulcer may persist.

Xelma from the patient's perspective

Debbie Wilson spoke about her experiences of treating people with hard-to-heal diabetic foot ulcers with Xelma, and the psychosocial impact that the treatment had alongside its clinical outcome.

She began by discussing the effect chronic foot ulcers have on those with diabetes in terms of quality of life. Debbie reminded the attendees that quality of life is the uniquely personal experience that represents the way a person perceives, and reacts to, their health status (Brod, 1998). Studies assessing quality of life among people with a diabetic foot ulcer have identified four key domains:

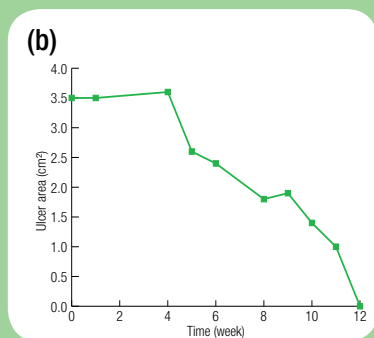
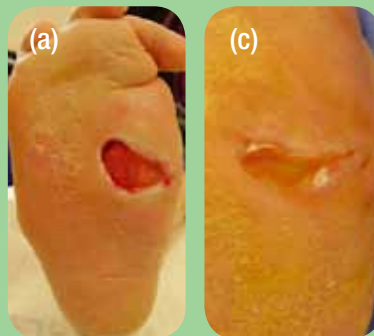- Social (daily leisure activities of social and family life).
- Psychological (emotional health).
- Physical (physical health and the impact of treatment).
- Economic (employment and finance).

All four of these domains have been associated with a significant negative impact on both the person with the condition and their family members and caregivers (Carrington et al, 1996;

Box 1. CASE REPORT: Ms S

Ms S, a 33-year-old woman with type 1 diabetes, presented with a neuropathic ulcer on the plantar aspect of her right foot (a) that had persisted for approximately 5 years. Her foot showed evidence of a previous episode of Charcot foot, a number of toes had been amputated, and her immunosuppressive drug regimen (for pancreas and kidney transplants carried out 4 years prior), were impairing wound healing.

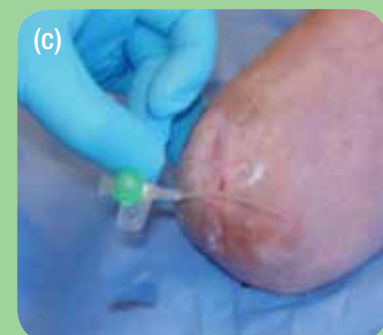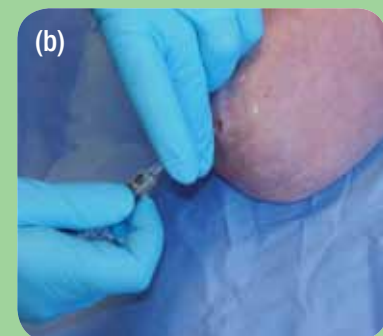
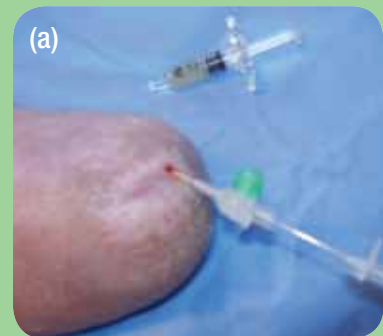A number of interventions were attempted during the year following Ms S' referral. The ulcer remained unhealed and treatment with Xelma was commenced. The progress of Ms S' wound progressed rapidly during the 12-week treatment period (b), and the ulcer healed by treatment end (c). Ms S remains healed at the time of writing.



Box 2. CASE REPORT: Mr X

Mr X, a 44-year-old man with type 2 diabetes, underwent a below-knee amputation. A deep sinus developed at the amputation site and persisted for 6 months without response to traditional treatments.

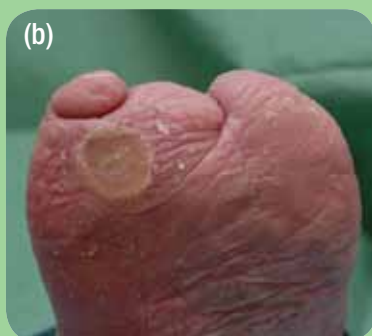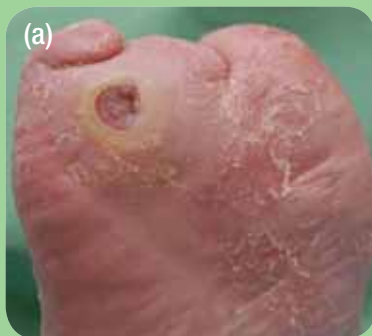Xelma was applied to the wound using a catheter to deliver the gel along the length of the sinus (a–c). Following 6 weeks of treatment with Xelma, Mr X's sinus closed and remains healed.



Box 3. CASE REPORT: Mr K

Mr K, a 72-year-old man with type 2 diabetes, had experienced 10 different episodes of ulceration over the past 12 years, with the longest period of ulceration lasting continuously for 3 years. Each ulcer had taken between 6 and 18 months to heal. During this time, Mr K had been hospitalised six times, experienced severe gentamicin toxicity, and had four toes amputated. The psychological, physical and social impact of Mr K's diabetic foot disease was significant.

Presenting with a 1.2 cm² neuroischaemic ulcer on the plantar aspect of his right foot (a), Mr K was treated with Xelma. Following 6 weeks of treatment, Mr K's ulcer healed (b). A second episode of ulceration succeeded the first 4 weeks after healing. Xelma was again used, and the ulcer healed within 5 weeks.



Brod, 1998; Bishop, 2007). In light of the association between diabetic foot ulceration and reduced quality of life, treatments that improve progression to healing in chronic wounds should be pursued when traditional methods are not sufficient.

Debbie presented the case history of Mr K (Box 3). Debbie described the impact that Mr K's recurrent, chronic diabetic foot ulcers had on his quality of life, and that of his family. Mr K was forced to retire from his business due to his diabetic foot ulceration, was unable to drive, and could no longer participate in his main social activity – his “beloved” golf. Mr K described to Debbie feelings of “anger, guilt and sever anxiety”. Mr K felt especially frustrated by having to suspend family holidays to Spain during his numerous episodes of ulceration. Given Mr K's 12-year history of chronic ulceration, Debbie initiated Xelma treatment when he next presented with an ulcer. With the use of Xelma in conjunction with standard wound care, two consecutive ulcers were successfully healed on Mr K's feet, each in under 6 weeks.

Mr K reported to Debbie “I could not believe the result, it was wonderful! As a result of this new treatment, I am enjoying a better quality of life”. Using Xelma to reduce the duration of Mr K's diabetic foot ulcers had a material impact on his wellbeing, and that of his family. Mr K and his wife were invited to the symposium, but were unable to attend because, Debbie reported, they were at that time on holiday with their family in Spain – just as they should be.

Conclusion

Diabetic foot ulcers are debilitating, costly and reduce the quality of life of those with the complication.

The use of Xelma can kick-start the wound healing cascade, and move a wound from a chronic state to complete healing. To reduce both the psychosocial and financial burdens of chronic diabetic foot ulceration, the speakers found Xelma to be a useful treatment modality. ■

Agren MS, Werthén M (2007) The extracellular matrix in wound healing: a closer look at therapeutics for chronic wounds. *Int J Low Extrem Wounds* **6**: 82–97

Bishop A (2007) Stress, social support and coping with a diabetic foot ulcer. *The Diabetic Foot Journal* **10**: 76–82

Brod M (1998) Quality of life issues in patients with diabetes and lower extremity ulcers: patients and care givers. *Qual Life Res* **7**: 365–72

Carrington AL, Mawdsley SK, Morley M et al (1996) Psychological status of diabetic people with or without lower limb disability. *Diabetes Res Clin Pract* **32**: 19–25

Edmonds ME, Foster AVM, Sanders L (2004) *A Practical Manual of Diabetic Foot Care*. Blackwell Publishing, Oxford

Lobmann R, Schultz G, Lehnert H (2005) Proteases and the diabetic foot syndrome: mechanisms and therapeutic implications. *Diabetes Care* **28**: 461–71

McCardle J, Brewin E, Young M (2008) Use of a synthetic extracellular matrix protein in non-healing diabetic foot wounds. *The Diabetic Foot Journal* **12**: 27–32

Romanelli M, Kaha E, Stege H et al (2008) Effect of amelogenin extracellular matrix protein and compression on hard-to-heal venous leg ulcers: follow-up data. *J Wound Care* **17**: 17–23

Singh N, Armstrong DG, Lipsky BA (2005) Preventing foot ulcers in patients with diabetes. *JAMA* **293**: 217–28

Vowden P, Romanelli M, Price P (2007) Effect of amelogenin extracellular matrix protein and compression on hard-to-heal venous leg ulcers. *J Wound Care* **16**: 189–95

The images used in Figure 1 are copyright (2008). They are reproduced here with the permission of Mölnlycke Health Care.