

The use of Aquacel Ag in the management of diabetic foot ulcers

Duncan Stang

ARTICLE POINTS

1 Over-prescription of antibiotics has led to a worrying increase in the number of infections caused by resistant organisms such as MRSA and VRE.

2 The specific effects of silver ions (Ag^+) on bacteria mean that dressings containing Ag^+ may provide an ideal alternative to antibiotic treatment in suitable wounds.

3 Dressings containing Ag^+ ions are being used increasingly, particularly as they possess many of the characteristics sought in an ideal topical dressing.

4 The author uses the Aquacel Ag dressing as a principal therapy for healing foot ulcers in diabetes patients meeting criteria.

KEY WORDS

- Wound care
- Silver
- MRSA / VRE
- Dressings
- Wound healing

Introduction

The over-prescription of antibiotics has led a worrying increase in the number of infections caused by resistant organisms such as methicillin-resistant *Staphylococcus aureus* (MRSA) and vancomycin-resistant *Enterococci* (VRE) (Van der Mee-Marquet, 2004). As a result, the potential for unconventional antimicrobial therapy use in the treatment of skin and soft tissue infection has increased. This article will explore the possible use of an antimicrobial dressing as a way of reducing the amount of antibiotics prescribed for people with diabetic foot ulcers.

The antimicrobial properties of silver were apparently known to the Ancient Egyptians, who placed silver coins in clay pots of drinking water to prevent water-borne infections (Lansdown, 2004). When silver is used in antimicrobial dressings in wound care, the generation of silver ions (Ag^+) leads to direct binding of Ag^+ ions to proteins within the cell membrane of the bacteria, resulting in selective cell wall damage. In addition, Ag^+ ions block cellular respiration pathways within the bacteria enhancing their microbicidal effects (Diprov et al, 2002).

In contrast, in tissue cells Ag^+ ions induce the expression of two proteins, MT-1 and MT-2, which are beneficial in wound healing (Demling and DiSanti, 2001). Thus, dressings containing Ag^+ ions may provide an ideal alternative to antibiotic treatment in suitable wounds, and ultimately reduce the potential for increasing antibiotic resistance amongst the common pathogens causing foot infections in patients with diabetes.

Current practice

In the diabetic foot clinic of Hairmyres Hospital, the current policy is to limit the prescription of antibiotic therapy to those patients who present with clinical signs of infection. However, we do have a low threshold for prescription, in keeping with current expert guidance: 'Clinical diagnosis of infection is based on the presence of discharge from the ulcer, cellulitis, warmth and signs of toxicity, though the latter is

uncommon' (Jude, 2004).

This practice allows antibiotic therapy to be directed at those with the greatest likelihood of benefit, and minimises the risk of promoting bacterial resistance in those with a low bacterial load, which could be managed by alternative means.

Our reasons for not prescribing prophylactic antibiotics are based on the following notions:

- Over-prescription of antibiotics has led to bacterial resistance (Van der Mee-Marquet, 2004).
- There is often an ischaemic element resulting in impaired microcirculation (Edmonds et al, 2004; Krentz et al, 2001). This may result in an impaired delivery of white blood cells to the site of infection in addition to lowered tissue levels of antibiotics.
- Some patients report side-effects during a course of antibiotics (Dancer, 2004). This can interrupt their eating habits and destabilise their diabetes control.

Modern wound care has advanced with the recent development of dressings incorporating potent antimicrobial agents. Dressings containing Ag^+ ions are being used increasingly, particularly as they possess many of the characteristics we seek in an ideal topical dressing.

In particular, when assessing the properties of a topical antimicrobial dressing, the following were felt to be particularly important by our multidisciplinary team:

- Providing a broad spectrum of sustained

PAGE POINTS

1 Studies have shown the Aquacel Ag dressing to provide broad spectrum sustained antimicrobial activity in vitro.

2 The author's use of the dressing as a principal therapy for the treatment of diabetic foot ulcers is based on patients meeting certain criteria (e.g. ulcers showing no signs of clinical infection).

3 The use of the dressing is illustrated in a case study of a man with type 2 diabetes who presented to the clinic with neuro-ischaemic ulceration of the right first toe.

Figure 1 (top). Due to the favourable appearance of the toe, it was decided not to prescribe antibiotic therapy, but instead to use an antimicrobial and foam dressings.

Figure 2 (bottom). The toe auto-amputated after six weeks, leaving the bone of the interphalangeal joint exposed.

antimicrobial activity

- Efficacy against methicillin-resistant *Staphylococcus aureus* (MRSA) and vancomycin-resistant *Enterococci* (VRE)
- Establishing a host-manageable bio-burden
- Containing bacteria within the wound dressing
- Providing a moist wound environment
- Managing wound exudate to prevent maceration of surrounding skin
- Ease of application and removal
- Cost-effectiveness when compared with antibiotic therapy.

As a result of these demands, our team often choose the Aquacel Ag dressing (Convatec) as we feel it meets most of the criteria. Studies have shown the dressing to provide broad-spectrum sustained antimicrobial activity in vitro (Bowler et al, 2003). Additionally, Caruso and colleagues (2004) carried out a phase II non-comparative trial in superficial, mid-dermal and mixed partial-thickness burns and found that the dressing rated positively in conformability and ease of use, with the speed of re-epithelialisation being satisfactory, and appeared similar at least to results achieved with silver sulphadiazine (Caruso et al, 2004).

Of more interest to our practice was a study on 134 non-ischaemic diabetic foot ulcer patients comparing Aquacel Ag to a calcium alginate (Jude, 2004). Preliminary results suggest that the dressing provides improvement in healing time, enhanced reduction in ulcer area and depth, total healing at eight weeks, as well as synergistic effects in patients treated with antibiotics (Jude, 2004).

When do we use it?

Our choice of Aquacel Ag as a principal therapy for healing foot ulcers in patients with diabetes is based on patients meeting one or more of the following criteria:

- Ulcers showing no signs of clinical infection
- Chronic or slow to heal ulcers where critical colonisation is thought to be the cause of delayed healing
- Ulcers where there is a localised non-spreading mild erythema
- In conjunction with antibiotic therapy where clinical infection has been diagnosed but where local control of infection is thought likely to be adequate after a limited

course of antibiotic therapy.

These criteria are used to select patients for dressing use, and are illustrated below in a case study from our unit.

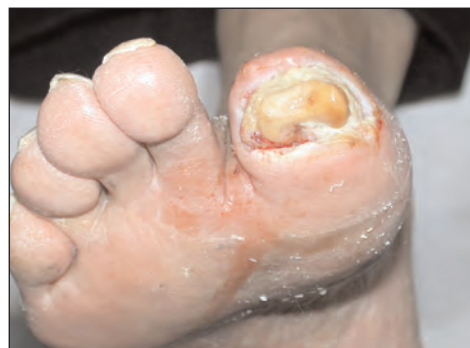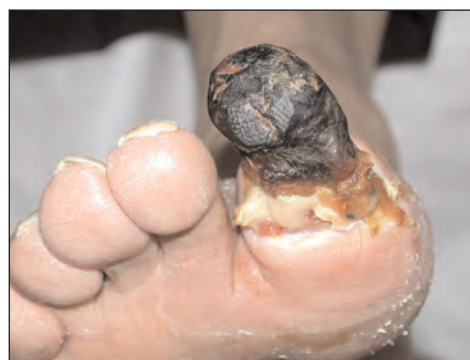Case study

Mr AJ is a 77-year-old male with type 2 diabetes who presented to our clinic with neuro-ischaemic ulceration of the right first toe. He has profound sensory neuropathy due to diabetes and memory impairment due to Alzheimer's disease, and relies on carers to detect foot problems.

Angiography of his lower limbs showed critical narrowing of the distal external iliac artery and a percutaneous angioplasty was performed which improved the perfusion to the foot. Although the circulation was improved, it was too late to salvage the toe.

It was decided to allow auto-amputation to take place and the patient could be managed as an outpatient with regular visits to the clinic with support by district nurse services and his son.

The line of demarcation at the interphalangeal joint had a degree of slough present but there was very little surrounding erythema and no cellulitis was present (*Figure 1*). Due to the favourable appearance, it was decided not to prescribe antibiotic therapy but to apply Aquacel Ag and foam dressings to manage the bacterial



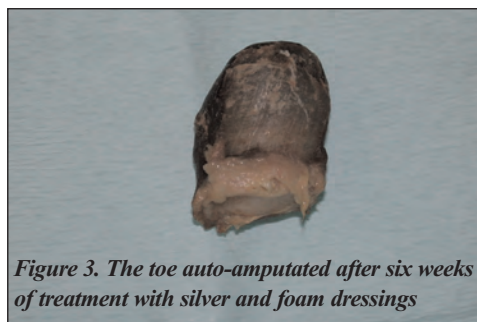


Figure 3. The toe auto-amputated after six weeks of treatment with silver and foam dressings

burden and wound exudate.

At each visit to the clinic the slough around the line of demarcation was removed using sharp debridement and the silver and foam dressings were reapplied. The foot temperature was monitored at each visit and the surrounding skin checked for any signs of clinical infection.

The toe auto-amputated (with help from a number 15 scalpel blade) after six weeks, leaving the bone of the interphalangeal joint exposed (Figures 2 and 3).

At this stage there was very little slough present and very little erythema in the surrounding tissues. The final barrier to wound healing and closure was the exposed bone, so this was removed at the next visit (Figure 4).

At subsequent visits, Aquacel Ag and foam dressings were applied after debridement and the ulcer progressed to complete healing in another six weeks (Figures 5 and 6). The patient was then referred to the orthotist for prescription footwear and total contact casts to redistribute the pressure evenly to aid walking and prevent further breakdown. To date the foot remains intact.

Conclusion

Central to the management of healing in a patient with a diabetic foot ulcer is the need for a multidisciplinary foot team to address the multifactorial nature of the pathogenesis of the ulcer (Foster and Edmonds, 2001). In addition, it is essential to remember that if infection does occur in a diabetic foot ulcer, it can spread very rapidly. Therefore, when any patient is being managed without prophylactic antibiotic therapy, they must be monitored very closely. Good lines of communication between all healthcare professionals who may be sharing the patient's care must be in place. Similarly, patients and their carers must be educated in recognising the signs of infection

– i.e. swelling, spreading erythema, rise in blood sugars and feeling generally unwell – as well as having a clear plan of action if these factors occur.

Large randomised control trials are required to investigate the use of the prophylactic prescription of antibiotics versus the use of antimicrobial dressing in the management of non-clinically infected diabetic foot ulcers. Only by assessing these dressings in this way can we be confident that we can move away from prophylactic antibiotics.

In our recent experience, the use of Aquacel Ag as a topical antimicrobial therapy has proved very successful and raises the possibility that not all patients with diabetic foot ulcers require antibiotic therapy, especially if there are no clinical signs of infection. However, this mode of treatment can only be carried out with very close monitoring and education of everyone involved in the delivery of care.

ACKNOWLEDGEMENT: I thank Dr Andrew Jamieson for help with this manuscript.

- Bowler P, Schank J, Bates-Jensen B (2003) *Infection control practices relating to chronic wounds*. Poster presentation, 8th National Conference NPUAP (National Pressure Ulcer Advisory Panel), New Orleans
- Caruso DM, Foster KN, Hermans MHE, Rick C (2004) Aquacel Ag in the management of partial thickness burns: Results of a clinical trial. *Journal of Burn Care Rehabilitation* **25**: 89–97
- Dancer SJ (2004) How antibiotics can make us sick: the less obvious adverse effects of antimicrobial chemotherapy. *Lancet Infectious Diseases* **4**(10): 611–19
- Demling RH, DiSanti L (2001) Effects of silver on wound management. *Wounds* **13**(suppl A): 5–15
- Dibrov P, Dzioba J, Gosink KK, Hase CC (2002) Chemiosmotic mechanism of antimicrobial activity of Ag(+) in *Vibrio cholerae*. *Antimicrobial Agents and Chemotherapy* **46**(8): 2668–70
- Edmonds ME, Foster AV, Sanders S (2004) *A Practical Manual of Diabetic Foot Care*. Blackwell Publishing, London
- Foster A, Edmonds M (2001) An overview of foot disease in patients with diabetes. *Nursing Standard* **16**(12): 45–52; quiz 54–55
- Jude E (2004) *Non-ischemic diabetic foot ulcer: effects of Aquacel Ag with hydrofibre versus alginate dressing*. Oral presentation, 2nd World Union of Wound Healing Societies' Meeting, Paris
- Krentz AJ, Mani R, Shearman CP (2001) Peripheral arterial disease in diabetes: time for a co-ordinated approach to management. *British Journal of Diabetes and Vascular Disease* **3**: 92–96
- Lansdown AB (2004) A review of the use of silver in wound care: facts and fallacies. *British Journal of Nursing* **13**(6 Suppl): S6–19
- Van der Mee-Marquet N, Blanchard M, Domelier AS, Quentin R; the Infection Survey study group of the Relais d'Hygiene du Centre (2004) Virulence and antibiotic susceptibility of *Staphylococcus aureus* strains isolated from various origins. *Pathol Biol (Paris)* **52**(10): 579–83

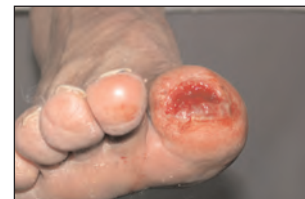

Figure 4 (above). The exposed bone was removed at the subsequent visit.

Figures 5 and 6 (below). The antimicrobial and foam dressings were applied after debridement on subsequent visits to complete healing.

