

# Should antibiotics be used in the treatment of the diabetic foot?

Tony Berendt, Benjamin A Lipsky

## ARTICLE POINTS

**1** Purulence and any two of the signs of inflammation (erythema, tenderness, swelling, local warmth) are sufficient to diagnose infection.

**2** There is not sufficient evidence to justify widespread and prolonged use of antibiotic therapy for the entire population with diabetic foot ulcers.

**3** Severity of infection should be assessed before the decision to use antibiotics or not is made.

**4** Intravenous agents should be used in severe and some moderate infections when rapid high levels of antibiotic are essential; oral therapy can be used for mild infections.

**5** Antibiotics and the microbiology should be used in a rational way.

## KEY WORDS

- Infection
- Ulcer
- Erythema
- Antibiotics

Tony Berendt is Consultant Physician-in-Charge at the Bone Infection Unit, Nuffield Orthopaedic Centre NHS Trust, and Honorary Consultant in Infectious Diseases, Oxford Radcliffe Hospitals NHS Trust; Benjamin A Lipsky is Professor of Medicine, University of Washington, and Director, General Internal Medicine Clinic, VA Puget Sound Health Care System, Seattle, USA.

## Introduction

**Infection is a major step on the path to lower limb amputation in people with diabetes. Clinicians involved in the care of the diabetic foot need to be able to assess suspected infection, initiate appropriate treatment, and coordinate a definitive management plan. This article describes the spectrum of diabetic foot infections and offers a scheme for assessing their severity that will help clinicians select an empiric antibiotic regimen. It stresses the need to integrate antibiotic use into a total management plan for the infected ulcer, and highlights uncertainties that need to be addressed in future research. The use of antibiotics should be rational and kept to a minimum.**

Infection is a major step on the 'pathway to amputation' (Pecoraro et al, 1991; Reiber et al, 1992; International Working Group on the Diabetic Foot, 1999). It can be limb threatening in a variety of ways. Through its locally destructive effects it can cause irreparable soft tissue loss, or so affect the bony architecture of the foot that it becomes mechanically useless. The systemic effects of acute infection may be so severe that they are life threatening, and are only ameliorated by amputation (as in gas gangrene). More insidiously, chronic infection may prove so debilitating through malaise, cachexia, poor glycaemic control and repeated hospitalisation that amputation comes as a welcome relief.

## Clinical spectrum

Infection may present in a number of ways, involving the full range of tissue structures in the foot (*Table 1*). Of these, however, it is the infective complications of diabetic foot ulceration that pose the greatest challenge, since, by definition, these occur in the context of a compromised foot.

## Defining and diagnosing an infection

As yet there are no universally agreed definitions of infection in a diabetic foot ulcer, although the International Consensus on the Diabetic Foot and the Infectious

Diseases Society of America Diabetic Foot Infection Guideline Committee are attempting to produce these. A consensus definition has been produced by the American Diabetes Association (1999). A generic definition of infection is that it is a process characterised by the invasion and injury of host tissue by microorganisms, with an associated inflammatory host response.

This state is distinct from colonisation, in which there is a non-invasive and harmless association between the host and the microbe. Colonisation with microbial flora of some kind is normal and inevitable on all body surfaces exposed to the external environment, including wounds, but the colonising flora can vary by location, between patients, and in a given site, over time.

This has an additional important implication for clinicians treating diabetic foot infections. Since colonisation is inevitable, antibiotics not only kill infecting organisms, but also influence the specific composition of the colonising flora. The repeated or prolonged use of antibiotics will select for favouring epidemic antibiotic-resistant strains such as methicillin-resistant *Staphylococcus aureus* (MRSA). This is already an increasing problem in diabetic foot services (Tentolouris et al, 1999).

Colonisation is distinct from contamination, which is the abnormal presence, in a tissue or a sample, of microbes derived from the external environment, but without evidence

**Table 1. Clinical spectrum of diabetic foot infection**

Type of infection	Common anatomical sites	Common microbial pathogens
Infected ulcer	All sites of ulceration, as determined by biomechanics and ischaemia, if present	<i>Staphylococcus aureus</i> β-haemolytic streptococci
Cellulitis	Soft tissues surrounding ulcer, traumatic wound, burn, abscess or broken skin; whole foot and beyond	β-haemolytic streptococci <i>S. aureus</i>
Fasciitis	Superficial or deep fascia, tracking from margin of full-thickness ulcer; extensive involvement of fascia ascending from foot into lower limb	β-haemolytic streptococci
Myositis	Any muscle group	<i>S. aureus</i>
Abscess formation	Deep spaces of foot	<i>S. aureus</i> β-haemolytic streptococci
Tendon sheath infection	Tracking into foot from metatarsal ulceration directly involving tendon sheath	<i>S. aureus</i>
Septic arthritis	Metatarsophalangeal joints (especially first) and proximal interphalangeal joints	<i>S. aureus</i> Often polymicrobial, also including β-haemolytic streptococci, enterococci, aerobic Gram-negative rods, and anaerobes.
Osteomyelitis	Bone exposed through ulceration; metatarsal heads, phalanges, calcaneum	

of infection.

A workable definition of diabetic foot infection used in a number of clinical trials of antimicrobial treatment is the presence of systemic toxicity (with no other explanation), of purulence, or of any two of the signs of inflammation (erythema, tenderness, swelling or local warmth) (American Diabetes Association, 1999).

Using this definition, and taking into account the problems of microbial colonisation, it follows that the diagnosis of infection in the diabetic foot should be a clinical one. Laboratory investigations play little part in the diagnosis of an infected ulcer, although they can be important in defining the extent of infection (especially bone involvement), the need for surgery, and the pathogen.

**Assessing the severity of infection**

Once a clinical diagnosis of infection is made, it is all too easy to assume that the next and most important task is to

prescribe antibiotics. Paradoxically, this should be the last step in commencing treatment for an infected ulcer. It is better to think of antibiotics as an essential form of adjunctive therapy, as this will focus attention on first addressing other factors that have a critical impact on overall outcome (Armstrong et al, 1998), namely:

- Ischaemia
- The structures involved (affecting duration of treatment)
- The degree of tissue damage (affecting the need for surgery)
- The potential for wound healing
- The need for hospitalisation.

**Whole patient**

Assessment should begin at the level of the whole patient, to establish the degree of systemic response. Fever, raised pulse rate and other signs of sepsis are known to be relatively blunted in diabetic patients with foot infections (Edelson et al, 1996; Eneroth et al, 1997), and their presence should raise suspicion of a serious complication such as

**PAGE POINTS**

**1** Assessment should begin at the level of the whole patient, to establish the degree of systemic response.

**2** Fever, raised pulse rate and other signs of sepsis are known to be relatively blunted in diabetic patients with foot infections.

**3** Their presence should therefore raise suspicion of a serious complication such as abscess formation, necrosis or bacteraemia.

abscess formation, necrosis or bacteraemia.

It is also important to form a view of the patient's social situation, understanding of and ability to undertake footcare, cognitive state, and any relevant comorbidities. These are all likely to affect adherence to the treatment regimen (including enforced rest), thus influencing the decision to hospitalise the patient.

### Limb and foot

Assessment now needs to shift to the level of the limb and foot, establishing the extent of cellulitis, necrosis, or ischaemia. If foot pulses are not palpable, further assessment is important, using ankle-brachial pressure indices, toe pressures, or transcutaneous oxygen tensions as available. Input from a vascular surgeon may be necessary either for assessment or for subsequent treatment.

Hypoxia has adverse effects on wound healing and reduces the effectiveness of neutrophil phagocytosis and killing. It also alters the growth rates, and hence susceptibility to antibiotics of many bacteria, while favouring the growth of destructive anaerobes.

The biomechanics of the foot must also be considered. Wound healing is not essential for cure of infection, but healing of the ulcer will remove the portal of entry for further infections. Preventing ongoing repetitive trauma to the infected ulcer by adequate offloading will reduce the amount of injured tissue at risk.

### Ulcer and extent of infection

The ulcer or wound itself should now be assessed, together with the extent of surrounding inflammation or obvious infection. This includes attention to the amount of spreading cellulitis, discharge or drainage, necrosis, and exposure of bone or joint structures.

In the presence of superficial necrosis or slough, it is frequently difficult to be certain of the depth of ulceration or the amount of deep tissue necrosis or infection. To establish this, the wound should ideally undergo sharp debridement as part of its assessment.

Probing the ulcer with a sterile metal probe is also advised. The so-called 'probe to bone' test, if positive, is moderately

predictive of underlying osteomyelitis (Grayson et al, 1995). It is also possible to demonstrate involvement of a joint by entering the cavity and palpating cartilage, to identify deep sinuses and to detect foreign bodies or exfoliated pieces of dead bone. Tissue that may initially appear to be slough, but that is in fact of greater significance, e.g. infected fascia, tendon or joint capsule, may be identified.

### Microbiological samples

This is also the ideal time to send specimens from the base of the debrided ulcer for culture. Such cultures yield fewer different organisms than swabs of the undebrided ulcer, which, because of colonisation have a more complex and varied microbial population (Wheat et al, 1986).

All but early presentations of mild infection in antibiotic-naive patients should be cultured, to provide a guide for definitive antibiotic therapy. A previous untreated mild infection need not be cultured, as their flora reliably consists of aerobic Gram-positive cocci (Lipsky et al, 1990). Preferred samples are tissue and aspirates of purulent material, which should be sent to the laboratory without delay to improve the recovery of anaerobes. Good communication with the laboratory is important, as the methods by which a sample is cultured, and the results given out, depend on the quality of the sample and clinical data received.

These assessments can now be combined to build up a picture of the overall severity of the infection, which can be classed as mild, moderate or severe.

Mild infections pose minimal immediate risk. They are confined to the skin in the immediate vicinity of the ulcer (<2 cm radius of erythema), do not involve the deep tissues, have no accompanying necrosis. The patient is systemically well with a well-perfused foot (Figure 1).

Moderate infections pose a significantly greater level of risk to the foot. Involvement of tissue around the ulcer extends for >2 cm radius and may penetrate superficial fascia to involve bone, joint or tendon or cause abscesses. The patient will, however, be systemically well. There is frequently a

### PAGE POINTS

1 All but early presentations of mild infection in antibiotic-naive patients should be cultured, to provide a guide for definitive antibiotic therapy.

2 Good communication with the laboratory is important, as the methods by which a sample is cultured, and the results given out, depend on the quality of the sample and clinical data received.

3 These assessments can now be combined to build up a picture of the overall severity of the infection, which can be classed as mild, moderate or severe.

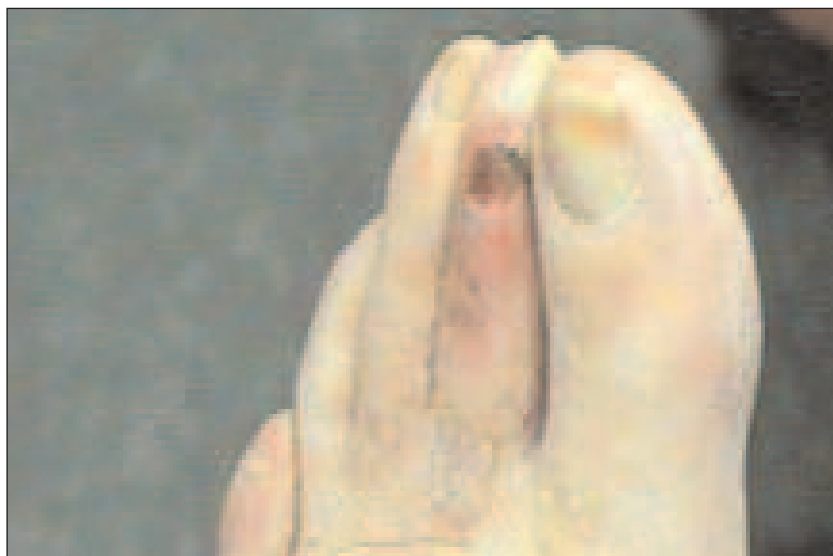


Figure 1. Mild infection, with a superficial ulcer, mild cellulitis, oedema and minimal purulence. Photograph courtesy of Mr L King.

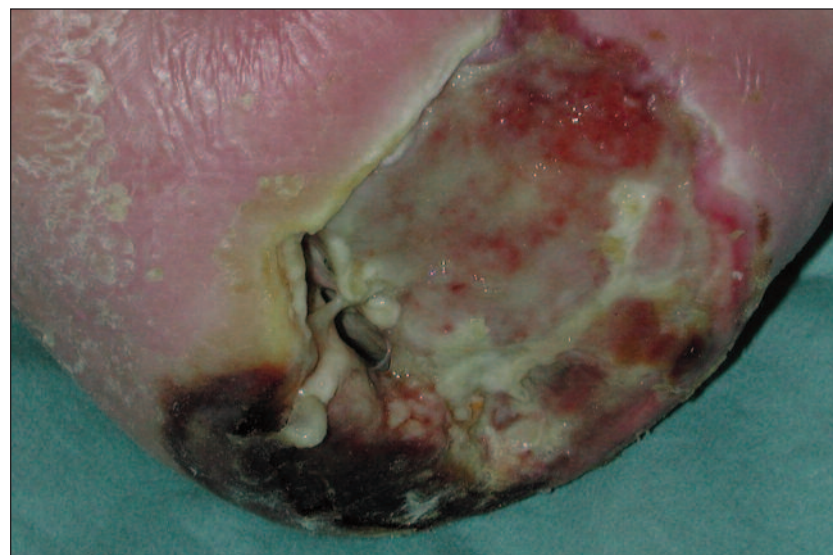

Figure 2. Severe infection, with extensive soft tissue loss and necrosis, including exposed and osteomyelitic bone, and systemic symptoms.

greater diversity of pathogens in these cases to include aerobic Gram-negative rods and anaerobes.

Severe infections pose an immediate threat to the foot or to life (Figure 2). This may be because ischaemia complicates an otherwise mild or moderate infection, or because, despite adequate perfusion, there is a marked degree of local or systemic involvement. Severe infections include any in the context of critical ischaemia or systemic illness (fever, hypotension, vomiting, suggestive of bacteraemia), or with specific local conditions, such as fasciitis or gas gangrene. Bacterial flora may include *Pseudomonas aeruginosa* and  $\beta$ -

lactamase-producing aerobic Gram-negative rods and anaerobes.

### Forming a treatment plan

Once the infection has been staged for severity, the need for surgery must be considered. Surgery may be necessary to remove necrotic soft tissue or bone, to drain pus under pressure or to restore adequate perfusion.

Although, ideally, revascularisation should precede debridement, limited resources may make this impractical. It is often necessary to perform emergency drainage and debridement first, and then move on to revascularisation as soon as possible.

At this point, it is finally appropriate to select the type, mode of administration and duration of antibiotic therapy. These can be chosen according to the degree of severity; a number of choices for the UK setting are outlined in Table 2. The principles governing antibiotic selection are as follows:

- Choose an antibiotic on the basis of the likely biology and pathogens – not at random. Remember to consider the local prevalence and nature of antibiotic resistance in the patient population.
- For mild infections, where the 'stakes are low', start with narrow-spectrum oral therapies and broaden up for treatment failure.
- For severe infections, where the 'stakes are high', start with broad-spectrum intravenous antibiotics and narrow down as culture and sensitivity results permit.
- Send cultures in all but mild infections, and whenever the microbiology cannot be easily predicted. This will allow the use of the narrowest spectrum regimen from the earliest moment possible.
- Keep antibiotic use to a minimum to reduce costs, side-effects and antibiotic resistance.

### Uninfected ulcers

The use of antibiotics on clinically uninfected ulcers is controversial (Chantelau et al, 1996; Foster et al, 1998). Concerns that some ulcers often carry a very substantial burden of bacteria that interfere with wound healing have underpinned one view that argues for using

**Table 2. Choices of antibiotic for empiric treatment of diabetic foot infection**

Severity of infection	Empiric antibiotic regimen*
Uninfected	<b>Do not treat</b>
Mild	Flucloxacillin 500 mg–1 g qds orally Cefalexin 500 mg tds orally Clindamycin 300 mg qds orally
Moderate	Co-amoxiclav 625 mg tds orally Clindamycin 300 mg qds and ciprofloxacin 500 mg bd Cefuroxime 1.5 g tds IV (add metronidazole 500 mg tds IV or 400 mg tds orally if ulcer is sloughy)
Severe	Cefuroxime 1.5 g tds IV, metronidazole 500 mg tds IV and gentamicin 5mg/kg daily IV (usually for 24 hours only) Meropenem 500 mg tds IV Piperacillin–Tazobactam 4.5G tds i.v.

\*Add vancomycin 1 g bd to any of these regimens if there is a significant likelihood of methicillin-resistant *Staphylococcus aureus*

antibiotics on any ulcer until it is healed.

We believe that the evidence, though contradictory, does not yet support this practice, which inevitably selects for antibiotic-resistant secondary pathogens, and leads to increased side-effects and cost. This question needs to be addressed in a large randomised controlled trial.

**Oral versus intravenous therapy**

There are few data comparing oral and intravenous therapies. Intravenous therapy has been a historical standard of care for most manifestations of severe infection, including osteomyelitis.

Intravenous therapies should definitely be used in severe and some moderate infections, in the following situations:

- When high levels of antibiotic must be ensured immediately.
- When there are concerns about patient adherence to an oral regimen
- When bacteria are resistant to oral therapy
- If there is coincident malabsorption, heart failure, gastric stasis or bowel pathology.

A number of studies have shown successful conversion from intravenous to oral therapy, provided that the oral drugs are highly bioavailable, the organisms are susceptible and the patient will adhere to the treatment (Lipsky et al, 1997; MacGregor et al, 1997).

Examples of highly bioavailable drugs are clindamycin, ciprofloxacin, cefalexin, rifampicin, trimethoprim and linezolid. The last drug in this list is new and currently extremely expensive, but is active against both MRSA and vancomycin-resistant enterococci (VRE). It offers promise in the treatment of diabetic foot infections, especially in the context of MRSA infection.

**How long should therapy last?**

One to two weeks’ therapy should suffice for mild infections (Lipsky et al, 1990) and 2 weeks (repeated once) for moderate infections.

Soft tissue infections do not usually need more than 4 weeks’ therapy unless there is osteomyelitis, in which case dead bone will act as a focus for recurrence. If infection appears still to be active after 4 weeks of treatment in an adequately perfused and offloaded ulcer, consider the possibility of osteomyelitis or abscess.

**Osteomyelitis**

Infection of bone poses particular problems, partly because of the difficulties in achieving soft tissue cover (i.e. wound healing) once bone has become exposed (Lipsky et al, 1997). Loss of the soft tissue envelope interrupts the periosteal blood supply to the bone; this leads to death of the outer cortex, thereby establishing a foothold for infection. It is notoriously difficult for granulation tissue to form over bone especially when the bone is dead.

Without intervention, wounds of this kind frequently heal only when the dead portion of bone sequesters and is exfoliated through the wound. This leaves granulation tissue (which forms beneath the dead bone through active bone resorption triggered by bacterial products and inflammatory cytokines) covering healthy bone.

In addition to the problem of wound healing, infection in bone is also particularly difficult to control because of areas of necrosis and hypoxia, which allow microbes to persist in the face of antibiotic treatment. Add to this the tendency of intramedullary oedema to compromise the endosteal circulation of the bone (once infection tracks through the cortex) and

**PAGE POINTS**

**1** Duration of antibiotic therapy should be kept to a minimum, to ensure against increasing antibiotic resistance in the community.

**2** Infection of bone poses particular problems, partly because of the difficulties in achieving wound healing once bone is exposed.

**3** Infection in bone results in areas of dead and hypoxic bone, which allow microbes to persist in the face of antibiotic treatment.

the scene is set for a potentially highly aggressive process characterised by bone death, resorption of living infected bone, and further local and systemic sepsis.

Osteomyelitis can be difficult to diagnose because of confusion with diabetic neuro-osteopathy. This is best resolved by bone biopsy. Biopsy permits culture and histological examination, assisting in decisions on duration and choice of antibiotic. Bone imaging studies can be hard to interpret. Magnetic resonance imaging, has emerged as the optimal investigation, with superior sensitivity and specificity to plain radiography or isotope scanning. Plain films can, however, be useful for detecting the extent of destruction and for monitoring progression; X-rays are highly likely to be different after a 3-4 week interval if osteomyelitis is present.

Historically it has been considered that osteomyelitis must be treated with surgical excision of dead and infected bone. This undoubtedly produces the best results in most areas of the skeleton; for the most reliable cure of infection with the shortest duration of antibiotics, the surgical approach would also be favoured in the diabetic foot. However, certain factors must be considered before deciding upon surgery, including:

- Vascularity, and hence the expected degree of wound healing after surgery.
- The current level of function and the likely impact of the planned surgery on function and foot biomechanics.
- Will the patient still be able to walk?
- Will new pressure areas be generated that again lead to ulceration?

These factors, taken alongside the relative lack of pain that neuropathy often confers, sometimes result in a decision not to operate.

Fortunately, surgery may not always be necessary. Several centres have reported good success rates using antibiotic therapy alone in chronic osteomyelitis (Venkatesan et al, 1997; Pittet et al, 1999; Senneville et al, 2001). It is difficult to compare the findings of these studies with other reports of treatment outcomes, or with each other, because of the lack of consensus definitions of osteomyelitis. Since most of the studies

were retrospective, there is no intention-to-treat analysis of patients or details of how many patients dropped out because of intolerance of the antibiotic regimen, which needs to be very much more prolonged than in cases managed with surgery.

Nonetheless, these studies do indicate that up to 70% of patients with chronic osteomyelitis associated with a diabetic ulcer may be successfully treated without radical surgery. It is not clear what role podiatry plays in such cases, but by facilitating the removal or expulsion of fragments of sequestered bone from the wound, it could be considerable.

The optimal duration of antibiotic therapy for osteomyelitis is still uncertain. Our practice is to factor in the extent of bone involvement and the extent of resection, together with the blood supply and soft tissue cover, as follows:

- If the entire involved bone is excised, leaving behind uninfected bone and uninfected soft tissue, antibiotics are needed for only 48–72 hours.
- If infected soft tissue remains, but the entire infected bone has been removed, antibiotics should be used for 2–4 weeks, as dictated by the soft tissues.
- If dead bone is fully resected, but infected bone remains (e.g. transmetatarsal amputation for metatarsal head osteomyelitis, when residual infection is often present in the shaft of the metatarsal), at least 4–6 weeks' therapy is advised.
- Finally, if surgery is not carried out, or is incomplete in the removal of dead bone, treatment needs to be given for at least 3 months. Even more prolonged therapy may be needed to suppress infection.

While some authorities advocate 6 weeks of intravenous therapy at the start of treatment, others treat with largely oral regimens. The relative merits of these strategies have not yet been put to the test.

### Future directions

There is an urgent need for consensus definitions of infection and osteomyelitis as well as standard classifications of infected

### PAGE POINTS

**1** Historically, it has been considered that osteomyelitis must be treated with surgical excision of dead and infected bone.

**2** However, several centres have reported good success rates using antibiotic therapy alone in chronic osteomyelitis.

**3** The optimal duration of antibiotic therapy for osteomyelitis is still uncertain.

**4** Our practice is to factor in the extent of bone involvement and the extent of resection, together with the blood supply and soft tissue cover.

PAGE POINTS

1 Constant vigilance is necessary to prevent the worst consequences of infection in the diabetic foot.

2 The duration and selection of antibiotic therapy should be kept to a minimum, maximising the cost-effectiveness of antibiotics, while minimising selection pressure towards antibiotic resistance at a patient and community level.

ulcers. Large randomised controlled trials on the use of antibiotics for uninfected ulcers, the duration and route of administration of antibiotic therapy, especially in osteomyelitis, and the medical treatment of diabetic foot osteomyelitis are also needed.

These important issues will be highlighted in guidelines due to be published later this year by both the International Consensus on the Diabetic Foot and the Infectious Diseases Society of America.

Conclusions

Constant vigilance is necessary to prevent the worst consequences of infection in the diabetic foot. Should we use antibiotics? Certainly, but not routinely, our use should be rational, sparing and with a strong sense of the underlying biology and microbiology of each case. If the decision is not based on the results of clinical trials, then it should at least be based on sound principles.

Empiric regimens should be based on an assessment of the severity of the infection, which can then be modified according to the clinical response and any cultures that become available. The duration and selection of antibiotic therapy should be kept to a minimum, maximising the cost-effectiveness of antibiotics, while minimising selection pressure towards antibiotic resistance at a patient and community level. ■

Acknowledgments

We wish to thank the members of the Diabetic Foot Infections Guideline Committee of the IDSA and the Infection Subgroup of the International Consensus on the Diabetic Foot for many helpful and stimulating discussions that have shaped our thinking.

American Diabetes Association (1992) Consensus development conference on diabetic foot wound care. *Diabetes Care* **22**: 1354-60

Armstrong DG, Lavery LA, Harkless LB. Validation of a diabetic wound classification system. The contribution of depth, infection, and ischemia to risk of amputation. *Diabetic Medicine* 1998; **21**: 855-59

Chantelau E, Tanudjaja T, Altenhöfer F et al (1996) Antibiotic treatment for uncomplicated neuropathic forefoot ulcers in diabetes: a

controlled trial. *Diabetic Medicine* **13**: 156-9

Edelson GW, Armstrong DG, Lavery LA, Caicco G (1996) The acutely infected diabetic foot is not adequately evaluated in an inpatient setting. *Archives of Internal Medicine* **156**: 2373-8

Eneroth M, Apelqvist J, Stenstrom A (1997) Clinical characteristics and outcome in 223 diabetic patients with deep foot infections. *Foot & Ankle International* **18**(11): 716-22

Foster AVM, Bates M, Doxford M, Edmonds ME (1998) Should oral antibiotics be given to 'clean' foot ulcers with no cellulitis? Abstracts of the 3rd International Symposium of The Diabetic Foot, Noordwijkerhout, The Netherlands, May 6: Abstract O13

Grayson ML, Gibbons GW, Balogh K et al (1995) Probing to bone in infected pedal ulcers. A clinical sign of underlying osteomyelitis in diabetic patients. *Journal of the American Medical Association* **273**: 721-3

International Working Group on the Diabetic Foot (1999) *International Consensus on the Diabetic Foot, May 1999*. Amsterdam: 1-96

Lipsky BA (1997) Osteomyelitis of the foot in diabetic patients. *Clinical Infectious Diseases* **25**:1318-26

Lipsky BA, Pecoraro RE, Larson SA, Ahroni, JH (1990) Outpatient management of uncomplicated lower-extremity infections in diabetic patients. *Archives of Internal Medicine* **150**:790-97.

Lipsky BA, Baker PD, Landon GC, Fernau R (1997) Antibiotic therapy for diabetic foot infections: comparison of two parental-to-oral regimens. *Clinical Infectious Diseases* **24**:643-48

MacGregor RR, Graziani AL (1997) Oral administration of antibiotics: A rational alternative to the parenteral route. *Clinical Infectious Disease* **24**: 457-67

Pecoraro RE, Ahroni JH, Boyko EJ, Stencil, VL (1991) Chronology and determinants of tissue repair in diabetic lower-extremity ulcers. *Diabetes* **40**: 1305-13

Pittet D, Wyssa B, Herter-Clavel C, Kursteiner K, Vaucher J, Lew PD (1999) Outcome of diabetic foot infections treated conservatively. A retrospective cohort study with long-term follow-up. *Archives of Internal Medicine* **159**: 851-56

Reiber GE, Pecoraro RE, Koepsell TD (1992) Risk factors for amputation in patients with diabetes mellitus. A case control study. *Annals of Internal Medicine* **117**: 97-105

Senneville E, Yazdanpanah Y, Cazaubiel M, et al (2001) Rifampicin-ofloxacin oral regimen for the treatment of mild to moderate diabetic foot osteomyelitis. *Journal of Antimicrobial Chemotherapy* **48**:927-30

Tentolouris N, Jude EB, Smirnof I, Knowles EA, Boulton AJM (1999) Methicillin-resistant *Staphylococcus aureus*: an increasing problem in a diabetic foot clinic. *Diabetic Medicine* **16**: 767-771

Venkatesan P, Lawn S, Macfarlane RM, Fletcher EM, Finch RG, Jeffcoate WJ.(1997) Conservative management of osteomyelitis in the feet of diabetic patients. *Diabetic Medicine* **14**: 487-90

Wheat LJ, Allen SD, Henry M, et al. Diabetic foot infections (1986) Bacteriologic analysis. *Archives of Internal Medicine* **146**: 1935-40