

The role of senescence in the pathogenesis and treatment of diabetic foot ulcers

Citation: Wilkinson HN, Hardman MJ (2020) The role of senescence in the pathogenesis and treatment of diabetic foot ulcers. *The Diabetic Foot Journal* 23(3): 64–9

Article points

- 1 Cellular senescence is a major contributor to age-related disease and diabetic pathology.
- 2 Senescent cells secrete potent inflammatory mediators that drive local inflammation and tissue damage.
- 3 Diabetic foot ulcers are characterised by high levels of inflammation and senescence that directly impairs wound healing.
- 4 Therapies targeting senescent cells, so called “senolytics”, may be a viable future option for improving diabetic wound outcome.

Key words

- Diabetes
- Diabetic foot ulcer
- Senescence
- Senolytics
- Wounds

Authors

Holly N. Wilkinson is a Research Fellow in Wound Healing, Hull York Medical School, The University of Hull, Hull, UK; Matthew J. Hardman is a Professor in Wound Healing and Director of Research, Hull York Medical School, The University of Hull, Hull, UK

Holly N. Wilkinson and Matthew J. Hardman

The incidence of diabetic foot ulcers (DFUs) continues to increase, and while some patients respond well to current best practice care, up to 40% do not (Guest et al, 2017). A fuller understanding of the complexity of diabetes-induced cellular defects will be essential to addressing this significant clinical hurdle. Cellular senescence, a common factor across many age-related diseases, including diabetes, has recently been suggested to be important for DFU outcome. Indeed, senescence-linked local inflammation is now thought to provide a functional relationship between hyperglycaemia and vascular damage, and even wider tissue dysfunction. This review will outline the key cellular aspects of diabetic wound repair where senescence appears to play a role, and discuss potential future therapeutic opportunities for senescence-targeted treatments.

Diabetic foot ulcers (DFUs) are a severe consequence of type I and type II diabetes mellitus (T1DM; T2DM). Obesity and advanced age are primary risk factors for developing T2DM, characterised by sustained hyperglycaemia, which leads to insulin resistance and associated secondary complications, including ischaemia and neuropathy. Interestingly, the presence of neuropathy significantly increased the risk of first-time DFU in both T1DM and T2DM, while other risk factors for DFU are more specific to T1DM (Hangaard et al, 2019). Diabetes in general has a large societal and economic impact, with T2DM patients over 65 costing healthcare providers on average twice as much as the same age group without T2DM (O’Shea et al, 2013). One in four patients with diabetes develop at least one DFU, with prospective studies indicating that 14–26% of these require amputations due to wound infection and osteomyelitis (Guest et al, 2018).

Wound management begins with assessing the

patient and wound aetiology, followed by tailored intervention. These often start with debridement, offloading and carefully selected dressings then, if required, move onto more advanced modalities, such as negative pressure wound therapy (Amin and Doupis, 2016). Despite technological advances and improved understanding of diabetic pathophysiology, current treatments almost exclusively address secondary complications of chronicity, rather than the cause. As a result, diabetic ulcers frequently persist or recur, with figures of up to 66% recalcitrance quoted (Hunt, 2011). Accordingly, there remains a clinical need to develop effective therapies that are financially, physiologically and practically viable.

Diabetic skin is predisposed to poor healing

Curiously, changes are observed in diabetic skin prior to ulceration, with up to a third of people

with diabetes experiencing a wide range of skin complications (reviewed in Quondamatteo, 2014). Compared to aged skin, where the physiological changes are well documented, the structure and function of diabetic skin has been greatly understudied. Nevertheless, a few key observations have been reported. For example, people with diabetes with high fasting blood glucose are more likely to develop xerosis, and skin blistering (bullous diabeticorum) is observed in around 0.5% of people with diabetes (reviewed in Quondamatteo, 2014).

The structural stability of diabetic dermis is decreased, with lower elasticity and reduced mean breaking strength, due in part to increased production of advanced glycation end-products (AGEs; Argyropoulos et al, 2016). In diabetes, HbA_{1c} is strongly linked to early glycation (Hb-AGE), a reliable measure of long-term glycaemic control (Turk et al, 1998). AGEs in peripheral tissues occur naturally when the body's proteins are glycated over time. However, this process is accelerated on a background of sustained hyperglycaemia in diabetes, where years of natural AGE accumulation can occur in a matter of months (Quondamatteo, 2014; Argyropoulos et al, 2016). While hyperglycaemia (high HbA_{1c}) is a major contributor to AGE formation, there will be other environmental factors that modulate the rate of AGE accumulation (e.g. ultraviolet radiation exposure). These AGEs then trigger inflammation-mediated pathways, which induce cellular free-radical release and oxidative stress. This cascade has profound effects in diabetic pathophysiology, leading to vascular and neurological damage that drives nephropathy, retinopathy, neuropathy and atherosclerosis (Huijberts et al, 2008).

In addition to the changes to our own cells, diabetic skin is characterised by microbiota dysbiosis. This includes higher than normal abundance of opportunistic pathogens (e.g. *Staphylococcus aureus*) in plantar regions (Redel et al, 2013). Indeed, it has recently been shown that low virulent forms of *S. aureus* preferentially establish infection in diabetic hosts (Tuchscher et al, 2018), reinforcing the concept that diabetic tissues are intrinsically compromised. Together, these characteristic changes predispose diabetic skin to poor healing by: a) attenuating sensation, which increases the risk of injury; b) altering cellular

capacity to repair the injury and; c) modifying tissue properties in favour of pathogenic colonisation.

Cellular basis of wound healing

The skin is a highly regenerative organ that has evolved a tightly regulated series of events to return to a normal state following damage. At the cellular level, the wound healing stages consist of blood clotting, inflammation, re-epithelialisation, angiogenesis, matrix deposition and remodelling (reviewed in Landén et al, 2016). Upon injury, platelets aggregate to prevent blood loss and provide a temporary scaffold of fibrin for wound cells to migrate into. Immune cells, mainly neutrophils and macrophages, then pervade the wound within hours. They remove bacteria and necrotic tissue, releasing soluble signalling factors to communicate with resident skin cells and other infiltrating cells (Singh et al, 2017).

Epidermal keratinocytes respond to these signals, undergoing collective migration to close the wound gap. Endothelial cells also begin to invade the wound, sprouting new vasculature to progress angiogenesis, a process that provides oxygen and nutrients to meet the requirements of the highly metabolic regenerating tissue. Fibroblasts correspondingly proliferate and deposit new matrix to replace the temporary fibrin scaffold (Landén et al, 2016). As healing progresses, inflammation abates, the epidermis reforms and the dermis remodels into a scar.

Diabetic wounds demonstrate impaired cellular behaviours

In acute healing, the molecular and cellular regulation of wound cell behaviours, from epidermal regeneration (Dekoninck and Blanpain, 2019), to extracellular matrix production (Wilkinson et al, 2019c), is well understood. Yet how these processes become dysregulated in the context of diabetic healing remains less well established. In diabetic ulcers, wound edge keratinocytes are known to lose their ability to migrate, instead adopting a hyperproliferative phenotype, marked by abnormal c-myc and beta-catenin expression (Stojadinovic et al, 2005). The epidermal wound edge becomes hyperkeratotic and parakeratotic, with keratinocytes unable to close the open wound. The epidermis surrounding DFUs has also been shown to

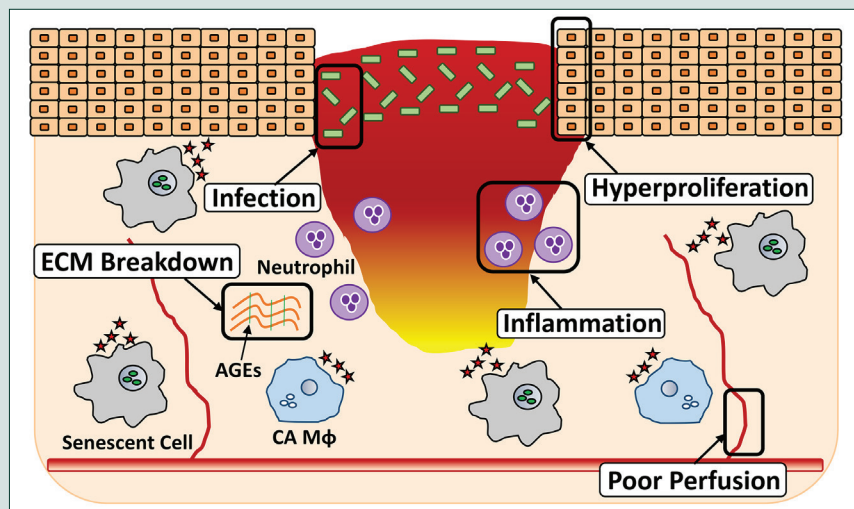


Figure 1. Impaired wound processes that may be exacerbated by senescence in diabetic foot ulcers.

contain abundant Langerhans cells (Galkowska et al, 2005), which may cause elevated wound matrix metalloproteinase (MMP) levels. MMPs contribute to excessive tissue breakdown, degrading collagen and other dermal proteins (Argyropoulos et al, 2016).

Despite an excessive inflammatory response, diabetic wounds become easily infected. Infiltrating macrophages, neutrophils and T cells have all been shown to be dysfunctional in diabetic tissue (Galkowska et al, 2005; Moura et al, 2017; Wilkinson et al, 2019b). This defective immune cell response adds to an inability to clear infection. Interestingly, antimicrobial peptide production is also altered in DFUs. For example, little to no expression of the cathelicidin antimicrobial peptide, LL-37, is observed in DFU epithelium (Rivas-Santiago et al, 2012). LL-37 is multi-functional, beneficially promoting keratinocyte migration in diabetic mice, as well as inhibiting bacterial growth (Carretero et al, 2008). Thus, damaged defence mechanisms provide an opportunity for pathogen invasion, while simultaneously impairing the function of important wound cells.

Cellular senescence promotes diabetic wound pathology

All cells in the body have a finite lifespan, undergoing programmed cell cycle arrest primarily to prevent the propagation of harmful mutations. Over time, these senescent cells accumulate and contribute to age-related tissue pathology (Wilkinson and Hardman, 2020). The observation

that DFUs harbour senescent fibroblasts was made over 20 years ago (Hehenberger et al, 1998). Few studies, however, have investigated the functional implications of these cells in diabetic pathology. We recently extended these findings to demonstrate that diabetic wounds contain senescent macrophages that impair healing (Wilkinson et al, 2019a). Though incapable of dividing, senescent cells remain highly active, secreting a wide range of cytokines, chemokines and proteases, collectively known as the senescence associated secretory phenotype (SASP). This SASP can influence the healing environment by altering the behaviours of local wound cells. SASP factors also appear to promote “bystander senescence” in neighbouring cells (as observed in Wilkinson et al, 2019a), hence, perpetuating cellular senescence and further impairing tissue function.

It is likely that local aspects of the diabetic environment increase the propensity of cells to senesce. DFUs are characterised by tissue hypoxia, a result of decreased tissue perfusion (Amin and Doupis, 2016). This contributes to inflammation and reactive oxygen species production, promoting a hostile tissue environment that impacts on cellular senescence. Hyperglycaemia can also directly and indirectly provoke replicative and stress-induced senescence (Prattichizzo et al, 2018). Indeed, chronic wound fibroblasts display an impaired stress response, rendering them more susceptible to senescence than normal fibroblasts (Wall et al, 2008).

Local bacteria may also augment host cell senescence. For example, pyocyanin, a virulence factor of *Pseudomonas aeruginosa* found in infected wounds, was shown to induce fibroblast senescence *in vitro* (Muller et al, 2009). Infection likely exacerbates local inflammation and drives oxidative stress to cause senescence, while persistent infection and immune cell dysfunction will potentiate senescence. These studies emphasise that senescent cell burden may significantly contribute to impaired diabetic wound healing (Figure 1), however, further experimental and clinical investigations are needed to elucidate the molecular, cellular and tissue level impacts of wound senescence.

Manipulating senescence to improve diabetic foot ulcer outcome?

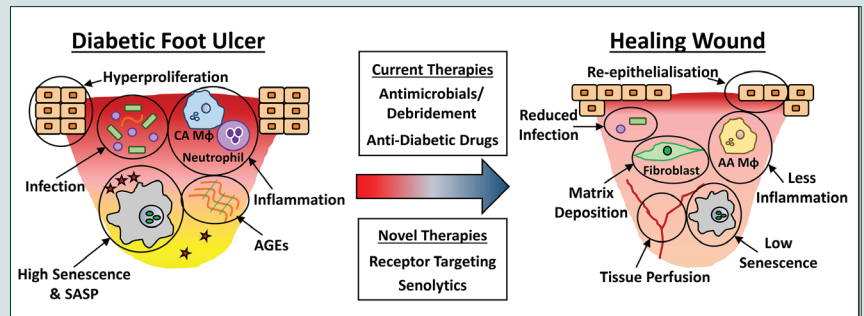
Given the clear mechanistic link between cellular

senescence and age-related disease, there has been considerable recent interest in modulating senescence for therapeutic benefit. Senescence-targeted drugs, often referred to as senolytics, are starting to show potential in the clinic. For example, limiting senescent cell burden in the adipose tissue of patients with diabetic kidney disease (Hickson et al, 2019).

Though not specifically directed at senescence, current wound treatments, such as debridement and antimicrobial dressings, will offer a degree of senescent cell reduction. For instance, removing necrotic tissue and alleviating infection will dampen local inflammation and further tissue damage that would otherwise promote senescence in wound cells. Of particular note, the widely used anti-diabetic drug, Metformin, has been suggested as a potential senolytic owing to its hypoglycaemic and anti-SASP effects (Ochoa-Gonzalez et al, 2016). Metformin decreases hyperglycaemia by inhibiting liver gluconeogenesis. The resulting drop in blood glucose levels should directly inhibit AGE production, dampen inflammation and oxidative stress, and prevent subsequent tissue damage. Indeed, diabetic mice treated with Metformin show improved wound closure (Han et al, 2017) and people with diabetes given Metformin experienced fewer DFU-related amputations (Ochoa-Gonzalez et al, 2016). This effect was specific to Metformin, as patients on other anti-diabetic drugs (e.g. insulin, sulfonylurea and glybenclamide) showed no difference in DFU-related amputations.

To suggest using one of the most commonly prescribed drugs for diabetes to treat DFUs may sound paradoxical; however, the reality is that, while Metformin successfully treats early stages of diabetes, long-term adherence is poor (McGovern et al, 2018). Thus, by the time DFUs develop, relatively few patients will still be using Metformin. It is also important to note that almost all senolytic therapy development to date has been in the area of cardiovascular and renal disease. However, senolytics, such as Resveratrol and Quercetin, are now showing promising anti-diabetic effects, which may well extend to clinical endpoints (e.g. DFUs).

Therapeutics with wide-ranging biological actions have traditionally been avoided, due the high risk of off-target effects (side effects). An alternative, possibly more fruitful, approach may be to develop



senolytic treatments with local, on-target effects. One option would be to target senescence-linked receptors on wound-relevant cells. For example, we recently demonstrated that the chemokine receptor, CXCR2, potentiates senescence in diabetic wound macrophages (Wilkinson et al, 2019a). Targeting antagonism of CXCR2 accelerated wound repair in diabetic mice by reducing senescence and inflammation. Interestingly, the safety of CXCR2 antagonists has already been evaluated in clinical trials (Kirsten et al, 2015), likely simplifying the route to repurposing for wound applications. Potential senescence-linked therapeutic strategies are summarised in *Figure 2*.

Conclusion

Hyperglycaemia is known to cause widespread tissue damage, particularly to the vasculature, via AGE production and subsequent local inflammation. From a clinical perspective, long-term effective management of HbA_{1c} is essential to limit early and advanced glycation products. Senescence is appearing as a key cellular process linking this glycation to the widespread tissue pathology observed in diabetes. This has important therapeutic implications. For example, experimental evidence suggests that targeting prescription of and adherence to Metformin (known to have senolytic activity) in patients with active DFUs may directly promote wound healing. Indeed, emerging clinical data point towards the benefit of topical senolytic treatments (Gallelli et al, 2020), with other trials under way. ■

- Amin N, Doupis J (2016) Diabetic foot disease: from the evaluation of the "foot at risk" to the novel diabetic ulcer treatment modalities. *World J Diabetes* 7(7): 153–64
- Argyropoulos AJ, Robichaud P, Balimunkwe RM et al (2016) Alterations of dermal connective tissue collagen in diabetes: Molecular basis of aged-appearing skin. *PLoS One* 11(4): e0153806
- Carretero M, Escámez MJ, García M et al (2008) In vitro and in vivo wound healing-promoting activities of human cathelicidin LL-37. *J Invest Dermatol* 128(1): 223–36

Figure 2. Proposed mechanisms whereby current and novel therapies dampen senescence and promote healing.

- Dekoninck S, Blanpain C (2019) Stem cell dynamics, migration and plasticity during wound healing. *Nat Cell Biol* 21(1): 18–24
- Galkowska H, Wojewodzka U, Olszewski WL (2005) Low recruitment of immune cells with increased expression of endothelial adhesion molecules in margins of the chronic diabetic foot ulcers. *Wound Repair Regen* 13(3): 248–54
- Gallelli G, Cione E, Serra R et al (2020) Nano-hydrogel embedded with quercetin and oleic acid as a new formulation in the treatment of diabetic foot ulcer: A pilot study. *Int Wound J* 17(2): 485–90
- Guest JF, Fuller GW, Vowden P (2018) Diabetic foot ulcer management in clinical practice in the UK: costs and outcomes. *Int Wound J* 15(1): 43–52
- Guest JF, Vowden K, Vowden P (2017) The health economic burden that acute and chronic wounds impose on an average clinical commissioning group/health board in the UK. *J Wound Care* 26(6): 292–303
- Han X, Tao Y, Deng Y et al (2017) Metformin accelerates wound healing in type 2 diabetic db/db mice. *Mol Med Rep* 16(6): 8691–8
- Hangaard S, Rasmussen A, Almdal T et al (2019) Standard complication screening information can be used for risk assessment for first time foot ulcer among patients with type 1 and type 2 diabetes. *Diabetes Res Clin Pract* 151: 177–86
- Hehenberger K, Kratz G, Hansson A et al (1998) Fibroblasts derived from human chronic diabetic wounds have a decreased proliferation rate, which is recovered by the addition of heparin. *J Dermatol Sci* 16(2): 144–51
- Hickson LJ, Prata LGPL, Bobart SA, et al (2019) Senolytics decrease senescent cells in humans: Preliminary report from a clinical trial of Dasatinib plus Quercetin in individuals with diabetic kidney disease. *EBioMedicine* 47: 446–56
- Huijberts MS, Schaper NC, Schalkwijk CG (2008) Advanced glycation end products and diabetic foot disease. *Diabetes Metab Res Rev* 24(S1): S19–24
- Hunt DL (2011) Diabetes: foot ulcers and amputations. *BMJ Clin Evid* 2011: 0602
- Kirsten A, Förster K, Radeckzy E et al (2015) The safety and tolerability of oral AZD5069, a selective CXCR2 antagonist, in patients with moderate-to-severe COPD. *Pulm Pharmacol Ther* 31: 36–41
- Landén NX, Li D, Ståhle M (2016) Transition from inflammation to proliferation: a critical step during wound healing. *Cell Mol Life Sci* 73(20): 3861–85
- McGovern A, Tippu Z, Hinton W et al (2018) Comparison of medication adherence and persistence in type 2 diabetes: A systematic review and meta-analysis. *Diabetes Obes Metab* 20(4): 1040–3
- Moura J, Rodrigues J, Gonçalves M et al (2017) Impaired T-cell differentiation in diabetic foot ulceration. *Cell Mol Immunol* 14(9): 758–69
- Muller M, Li Z, Maitz PK (2009) Pseudomonas pyocyanin inhibits wound repair by inducing premature cellular senescence: role for p38 mitogen-activated protein kinase. *Burns* 35(4): 500–8
- Ochoa-Gonzalez F, Cervantes-Villagrana AR, Fernandez-Ruiz JC et al (2016) Metformin induces cell cycle arrest, reduced proliferation, wound healing impairment in vivo and is associated to clinical outcomes in diabetic foot ulcer patients. *PLoS One* 11(7): e0159468
- O'Shea M, Teeling M, Bennett K (2013) The prevalence and ingredient cost of chronic comorbidity in the Irish elderly population with medication treated type 2 diabetes: a retrospective cross-sectional study using a national pharmacy claims database. *BMC Health Serv Res* 13: 23
- Prattichizzo F, De Nigris V, Mancuso E et al (2018) Short-term sustained hyperglycaemia fosters an archetypal senescence-associated secretory phenotype in endothelial cells and macrophages. *Redox Biol* 15: 170–81
- Quondamatteo F (2014) Skin and diabetes mellitus: what do we know? *Cell Tissue Res* 355(1): 1–21
- Redel H, Gao Z, Li H et al (2013) Quantitation and composition of cutaneous microbiota in diabetic and nondiabetic men. *J Infect Dis* 207(7): 1105–14
- Rivas-Santiago B, Trujillo V, Montoya A et al (2012) Expression of antimicrobial peptides in diabetic foot ulcer. *J Dermatol Sci* 65(1): 19–26
- Singh S, Young A, McNaught CE (2017) The physiology of wound healing. *Surgery (Oxford)* 35(9): 473–7
- Stojadinovic O, Brem H, Vouthounis C (2005) Molecular pathogenesis of chronic wounds: the role of beta-catenin and c-myc in the inhibition of epithelialization and wound healing. *Am J Pathol* 167(1): 59–69
- Tuchscherer L, Korpos É, van de Vyver H et al (2018) Staphylococcus aureus requires less virulence to establish an infection in diabetic hosts. *Int J Med Microbiol* 308(7): 761–9
- Turk Z, Mescic R, Benko B (1998) Comparison of advanced glycation endproducts on haemoglobin (Hb-AGE) and haemoglobin A1c for the assessment of diabetic control. *Clin Chim Acta* 277(2): 159–70
- Wall IB, Moseley R, Baird DM et al (2008) Fibroblast dysfunction is a key factor in the non-healing of chronic venous leg ulcers. *J Invest Dermatol* 128(10): 2526–40
- Wilkinson HN, Clowes C, Banyard KL, et al (2019a) Elevated local senescence in diabetic wound healing is linked to pathological repair via CXCR2. *J Invest Dermatol* 139(5): 1171–81
- Wilkinson HN, Hardman MJ (2020) Wound senescence: A functional link between diabetes and ageing? *Exp Dermatol* [Online ahead of print]
- Wilkinson HN, Roberts ER, Stafford AR et al (2019b) Tissue iron promotes wound repair via M2 macrophage polarization and the chemokine (CC motif) ligands 17 and 22. *Am J Pathol* 189(11): 2196–208
- Wilkinson HN, Upson SE, Banyard KL et al (2019c) Reduced iron in diabetic wounds: An oxidative stress-dependent role for STEAP3 in extracellular matrix deposition and remodeling. *J Invest Dermatol* 139(11): 2368–77

Online CPD activity

Visit www.diabetesonthenet.com/course to record your answers and gain a certificate of participation

Participants should read the preceding article before answering the multiple choice questions below. There is ONE correct answer to each question. After submitting your answers online, you will be immediately notified of your score. A pass mark of 70% is required to obtain a certificate of successful participation; however, it is possible to take the test a maximum of three times. A short explanation of the correct answer is provided. Before accessing your certificate, you will be given the opportunity to evaluate the activity and reflect on the module, stating how you will use what you have learnt in practice. The new CPD centre keeps a record of your CPD activities and provides the option to add items to an action plan, which will help you to collate evidence for your annual appraisal.

- According to Guest et al (2018), what approximate proportion (%) of people with diabetes will develop a diabetic foot ulcer (DFU)? Select ONE option only.
 - 10
 - 25
 - 50
 - 66
 - 75
- People with diabetes and high fasting blood glucose are more likely to develop xerosis of the skin.

Which is the most appropriate definition of 'xerosis'? Select ONE option only.

 - Blistered
 - Dry
 - Hard
 - Moist
 - Split
- The structural stability of the dermis is reduced in many people with diabetes, in part due to the increased production of advanced glycation end-products (AGEs; Agryopoulos et al, 2016).

Which single one of the following risk factors, if uncontrolled, is specifically linked to increased AGE production? Select ONE option only.

 - Blood pressure
 - BMI
 - Cholesterol
 - HbA_{1c}
 - Proteinuria
- According to Redel et al (2013), which one of the following pathogens is linked to microbiota dysbiosis in diabetic skin? Select ONE option only.
 - Chlamydia trachomatis*
 - Escherichia coli*
 - Haemophilus influenzae*
 - Neisseria meningitidis*
 - Staphylococcus aureus*
- Cells within the epidermal layer collectively migrate to close a wound gap in response to soluble signalling factors.

Which one of the following cells respond to such signalling factors? Select ONE option only.

 - Endothelial
 - Fibroblasts
 - Keratinocytes
 - Macrophages
 - Platelets
- Which cells replace the initial, temporary fibrin scaffold formed by platelets in response to acute tissue injury? Select ONE option only.
 - Endothelial
 - Fibroblasts
 - Keratinocytes
 - Macrophages
 - Neutrophils
- According to Stojadinovic et al (2005), which dysregulated cells in diabetic foot ulcers become hyperproliferative? Select ONE option only.
 - Endothelial
 - Fibroblasts
 - Keratinocytes
 - Macrophages
 - Neutrophils
- Which one of the following is secreted as part of the senescence associated secretory phenotype (SASP)? Select ONE option only.
 - Beta-catenin
 - Cytokines
 - Free radicals
 - LL-37
 - Pyocyanin
- Diabetic foot ulcers have impaired wound processes that may be exacerbated by senescence.

Which one of the following is not part of these impaired processes? Select ONE option only.

 - Angiogenesis
 - ECM breakdown
 - Hyperproliferation
 - Infection
 - Inflammation
- According to Muller et al (2009), which one of the following organisms has been shown to produce virulence factors that induce fibroblast senescence? Select ONE option only.
 - Beta-haemolytic streptococcus*
 - Haemophilus influenzae*
 - Corynebacterium*
 - Pseudomonas aeruginosa*
 - Staphylococcus aureus*

