

The orthopaedic contribution to modern diabetic foot care

Ngwe H Phyto, Venu Kavarthapu and Michael Edmonds

Citation: Phyto NH, Kavarthapu V, Edmonds M (2019) The orthopaedic contribution to modern diabetic foot care. *The Diabetic Foot Journal* 22(2): 12–6

Article points

1. The orthopaedic surgeon is an important member of the multidisciplinary diabetic foot team.
2. Orthopaedic surgeons surgically manage diabetic and Charcot foot deformities and infected foot ulcers.
3. Improvements in surgical procedures have improved the outcome for patients with neuropathic complications.

Key words

- Charcot deformity
- Foot reconstruction
- Orthopaedic management
- Multidisciplinary treatment

Authors

Ngwe H Phyto is Foot and Ankle Trauma Fellow, Department of Trauma and Orthopaedics, King's College Hospital NHS Foundation Trust, London, UK; Venu Kavarthapu is Associate Professor of Orthopaedic Surgery and Consultant Orthopaedic Surgeon, Department of Trauma and Orthopaedics, King's College Hospital NHS Foundation Trust, London, UK; and Michael Edmonds is Professor of Diabetic Foot Medicine, Diabetic Foot Clinic, King's College Hospital NHS Foundation Trust, London, UK

Orthopaedic surgery has a crucial role in the management of diabetic foot ulceration and Charcot foot. There is a need to raise awareness of the orthopaedic surgeon as an important member of the multidisciplinary team in the surgical treatment of these diabetic foot complications. This article describes three vital roles of the orthopaedic surgeon: surgical management of deformity; treatment of neuropathic diabetic foot infection; and management of Charcot foot deformity. With high-quality surgical care provided by dedicated orthopaedic surgery, the outcomes of diabetic foot ulceration and Charcot foot can be very favourable.

Orthopaedic surgery has a crucial role in the management of the diabetic foot, especially in the treatment of ulceration and Charcot foot. The orthopaedic surgeon is an important member of the multidisciplinary diabetic foot team, working closely with other team members including plastic and vascular surgeons. This article describes three of the most important roles of the orthopaedic surgeon:

- Surgical management of deformity in the prevention and treatment of diabetic foot ulcers
- Treatment of neuropathic diabetic foot infection
- Management of Charcot foot deformity.

Surgical management of deformity in diabetic foot ulcers

The lifetime risk for a foot ulcer among persons with diabetes has recently been estimated at between 19% and 34% (Armstrong et al, 2017). Lack of sensation in the foot secondary to diabetic neuropathy predisposes patients to foot ulceration. The precipitating cause is often mechanical forces caused by forefoot deformity, where the skin is at risk of ulceration in normal footwear. Deformities include high-grade hallux valgus, claw toes, cavus foot and hallux rigidus with reduced mobility. Such abnormal toe conditions are associated with increased risk of elevated foot pressures and subsequent foot ulceration. They

should be accommodated in properly-fitting footwear and may require bespoke footwear if the deformity is severe.

If footwear or custom orthosis fails to prevent the development of a primary ulcer or the recurrence of an ulcer, surgical correction of the deformity or resection of metatarsal head may be required, see *Figure 1*. Orthopaedic procedures can be divided into first ray procedures and lesser metatarsal procedures (Kilicoglu et al, 2018). Regarding first ray procedures, hallux valgus deformity can be treated with standard metatarsal osteotomy or arthrodesis procedure whereas, dorsal cheilectomy or metatarsophalangeal joint resection arthroplasty can be performed to treat hallux rigidus (Tamir et al, 2015). In the treatment of lesser toe and metatarsal deformities, procedures such as plantar condylectomy or metatarsal osteotomy to reduce plantar pressure can be considered. Resection arthroplasty is mainly reserved for cases where underlying osteomyelitis is present. It can also be considered if the metatarsal head prominence is associated with chronic plantar ulceration. One should be cautious about resecting the metatarsal head, as the risk of ulceration in neighbouring metatarsal areas is high.

Consideration should be given to protecting the foot postoperatively in neuropathic patients, with immobilisation in a total contact cast for a period

of time to allow full soft tissue healing and prevent the development of acute Charcot neuroarthropathy (CN). Following full ulcer healing, the patient should mobilise in custom-made insoles in order to avoid adjacent metatarsal heads bearing undue pressure, leading to plantar skin breakdown.

Less invasive procedures, such as toe flexor tenotomy to correct claw toe deformity with a supple interphalangeal joint, can be safely performed in an outpatient or day surgery setting. Percutaneous flexor tenotomy, see *Figure 2*, is very effective. A systematic review performed by Scott et al (2016) found it to be associated with a healing rate of 92–100% and recurrence rate of 0–18%. A 97% healing rate and 6% recurrence rate were found by Bonanno and Gillies (2017). Structural abnormality can exist in the Achilles tendon in patients with diabetes, leading to ulceration due to increased plantar forefoot pressures (Batista et al, 2008), which can be reduced by Achilles tendon lengthening (Armstrong et al, 1999). Achilles tendon lengthening can also be performed as an outpatient procedure.

Ulcers in the midfoot region are usually secondary to a bony prominence due to Charcot midfoot deformity and often demand exostectomy or surgical reconstruction. Mechanical ulcers of the hindfoot are due to underlying Charcot hindfoot deformity. If there is no response to offloading measures, corrective surgical reconstruction will be required. Plantar heel ulcers may start with an unnoticed skin puncture wound or pressure sore in patients with poor mobility. These demand a very complex orthopaedic management strategy, possibly involving calcaneal debridement and plastic surgery.

Management of neuropathic diabetic foot infection

Over 50% of diabetic foot ulcers become infected and can present as either acutely infected feet or as a chronic infected ulcer complicated by osteomyelitis (Prompers et al, 2007). There are three important steps when managing acutely infected diabetic feet:

1. Diagnose the presence of infection and start antibiotic therapy rapidly
2. Select appropriate initial antibiotic therapy
3. Determine whether the patient needs surgical debridement to remove infected tissue.

Often the latter is a very difficult decision for the multidisciplinary team and the orthopaedic surgeon

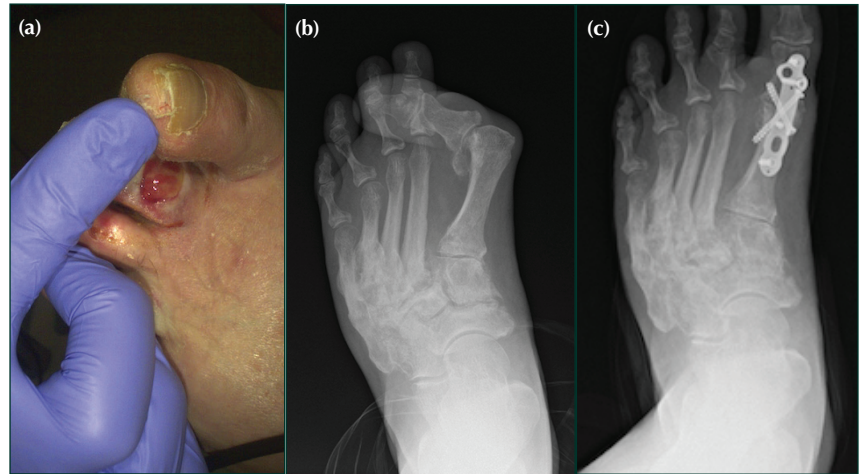


Figure 1. (a, b) Severe hallux valgus deformity causing ulceration of the adjacent toe. (c) Post-operative X-ray following first metatarsophalangeal joint fusion to correct the deformity.

is crucial in making this decision. The definite indications for urgent surgical intervention in the neuropathic foot complicated by ulcers with deep infection are:

- Large area of infected sloughy tissue
- Localised fluctuance and expression of pus
- Crepitus with gas in the soft tissues on X-ray
- Purplish discolouration of the skin, indicating subcutaneous necrosis.

Furthermore, in the neuropathic foot, operative debridement is almost always indicated for wet necrosis. Although such necrosis may not be associated with a definite collection of pus, there is usually sloughing of subcutaneous and fascial tissue that needs to be removed with the necrotic tissue. It is important for the orthopaedic surgeon to carry out meticulous wound exploration with removal of the infected sloughy tissue, including tendons and fascia. The surgeon also needs to open all of the sinuses down to healthy, bleeding tissue.

Multidisciplinary postoperative management is important. This should incorporate negative wound pressure therapy coordinated by the surgeon, podiatrist, microbiologist, nurse and diabetologist (Bateman et al, 2015).

‘Time is tissue’ has emerged as an important concept in the management of diabetic foot infections, and severe infection must be treated as a medical and surgical emergency. Urgent debridement in the non-ischæmic neuropathic foot is ideally carried out by an orthopaedic surgeon

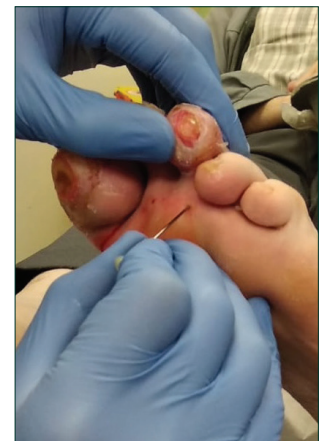


Figure 2. Percutaneous needle flexor tenotomy.

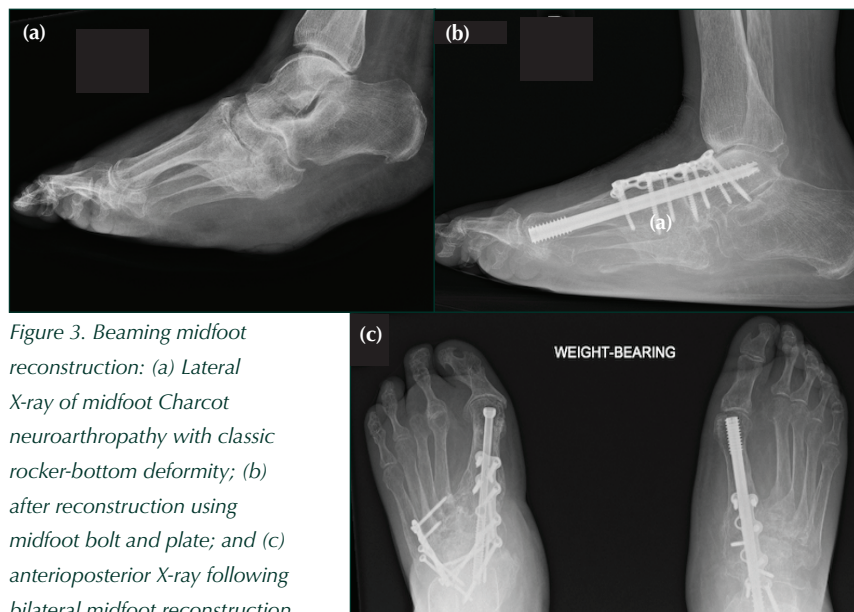

Figure 3. Beaming midfoot reconstruction: (a) Lateral X-ray of midfoot Charcot neuroarthropathy with classic rocker-bottom deformity; (b) after reconstruction using midfoot bolt and plate; and (c) anteroposterior X-ray following bilateral midfoot reconstruction.

but may also be performed by other specialties, including vascular, podiatric and plastic surgeons. Conversely, the infected ischaemic foot should ideally be debrided by a vascular surgeon. In overwhelming foot infection, often referred to as a ‘foot attack’ (Vas et al, 2018), debridement can be carried out by other surgical specialties, including the orthopaedic surgeon, when a vascular surgeon is not immediately available. Detailed vascular assessment and management must be carried out subsequently. Delays due to questions over which team, orthopaedic or vascular, will take ownership of management should be avoided (Joint Specialty Recommendations, 2016).

The orthopaedic surgeon also performs vital elective surgery in chronically-infected diabetic feet when foot ulcers with underlying osteomyelitis are failing to show signs of improvement in healing despite extensive conservative treatment. The nature of the surgery will depend on the location of the ulcer and underlying mechanical factors, as well as the extent of the osteomyelitis.

Surgical management of Charcot foot deformity

Although the orthopaedic surgeon has an important role in the diagnosis and initial management of acute active Charcot foot with casting, he or she has an increasingly vital role in the management of mid- and hindfoot Charcot foot deformity. Indications for surgery include instability of the foot or ankle and impending or actual ulceration precipitated by the

deformity. There is no consensus on the ideal timing of surgery, but most procedures are performed in the chronic non-active stage. One study described the outcome of intervention in acute Eichenholtz stage I, reporting patients’ ability to return to unassisted weight bearing at an average of 15 weeks (Simon et al, 2000).

Surgical options for CN include: exostectomy; reconstructive arthrodesis, using either internal or external fixation method or both; and amputation. Exostectomy reduces or removes the deformity causing plantar ulceration and is useful in patients who are not fit for more invasive reconstruction surgery (Broadsky and Rouse, 1993). Historically, limited surgical options for reconstruction and high risk of complications did not support the regular use of such procedures (Pinzur et al, 1993; Fabrin, et al, 2000). However, positive outcomes from a number of case series (Papa et al, 1993; Simon et al, 2000; Stone and Daniels, 2000; Mittlmeier et al, 2010) encouraged foot and ankle surgeons to take on more challenging reconstructive surgery, leading to a better understanding of surgical techniques, the development of better implants and streamlined postoperative rehabilitation in the multidisciplinary setting. Moreover, the quality of evidence guiding surgical treatment strategy has improved (Schneekloth et al, 2016).

Internal and external fixation methods have been used to treat Charcot midfoot deformity, with varying clinical outcomes (Wiewiorski et al, 2013; Hegewald et al, 2016). The concept of the ‘super-construct’ was introduced in 2010 and advocates four key factors (Sammarco and Chevillet, 2010):

- Extending fusion beyond the zone of injury to include unaffected joints to improve fixation
- Performing bone resection to shorten the limb and allow for adequate reduction of deformity without undue tension on the soft tissue envelope
- Using the strongest device tolerated by the soft tissue envelope
- Applying the devices in a position that maximises mechanical stability.

Surgical techniques have evolved over time and newer techniques — such as beaming for midfoot reconstruction, where intraosseous screw fixation spans the area of bone dissolution and fixes the proximal to the distal segment akin to long bone

intramedullary nailing in diaphyseal fracture — have become popular, see *Figure 3*. Early papers reported varying outcomes with complications such as bolt migration, fracture and loosening, requiring further surgery (Cullen et al, 2013; Wiewiorski et al, 2013; Eschler et al, 2014). This undesirable hardware issue, especially loosening, has been overcome by improvements in thread design and surgical techniques. In a recent systematic review, the estimated bony union after surgical treatment of midfoot Charcot deformity, using internal or external fixation or both, was 91% (Safavi et al, 2017).

It is interesting to note that the trend in surgical intervention has changed. Hindfoot is now the most common site requiring surgical intervention (Schneekloth et al, 2016); whereas in earlier findings midfoot was the most common location of surgery (Lowery et al, 2012). This may be because hindfoot CN deformity often leads to structural instability, inevitably risking the development of ulcer formation; whereas midfoot deformity is more amenable to bracing and other non-operative measures. Surgical approaches for Charcot hindfoot deformity include the use of an intramedullary hindfoot nail, ring external fixator or a combination of both, with or without simultaneous lengthening of the Achilles tendon. The use of an intramedullary nail for tibiotalocalcaneal arthrodesis in hindfoot reconstruction offers a stable column for fixation and weight bearing, see *Figure 4*. Promising results have been reported in the literature: one study achieved 100% limb salvage, with almost all patients regaining independent mobility (Siebachmeyer et al, 2015); another achieved an 85% salvage rate (Chraim et al, 2018). Tibiotalocalcaneal arthrodesis has also become a more common procedure for hindfoot CN (Schneekloth et al, 2016).

Use of external fixation has also been well established in the treatment of hindfoot Charcot with or without ulceration, see *Figure 5*. El-Gafary et al reported their early results in 2009, with all 20 patients achieving bony union and deformity correction. Pin site infection was common but did not require removal of the frame before bone union was achieved. Fabrin et al (2007) achieved realignment and independent walking in a brace in 95% of patients (11 out of 12 feet).

There is no substantial evidence in the literature to suggest one surgical method is superior to another.

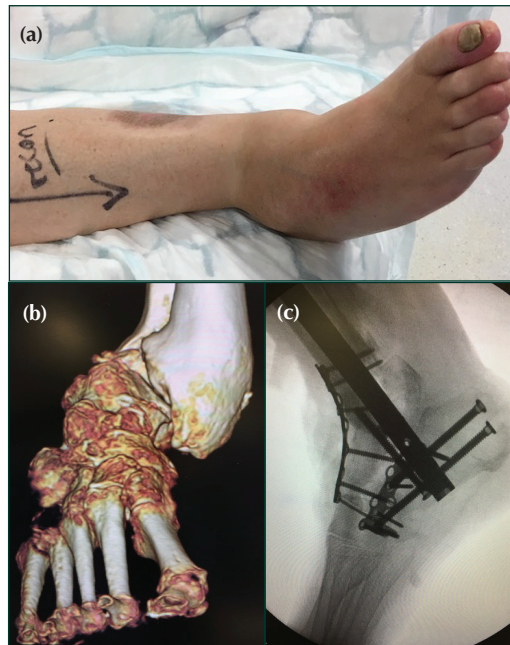


Figure 4. Hindfoot Charcot treated with intramedullary nailing: (a) Clinical photograph showing severe ankle and hindfoot deformity secondary to Charcot neuroarthropathy (b) CT 3 dimensional reconstruction showing bony deformity of hindfoot (c) Intra-op fluoroscopic image showing lateral view of reconstructed hindfoot.

Richman et al (2017) reported similar fusion rates in a comparative study of intramedullary nail *versus* ring external fixator in the management of Charcot hindfoot. However, they noted that compared to

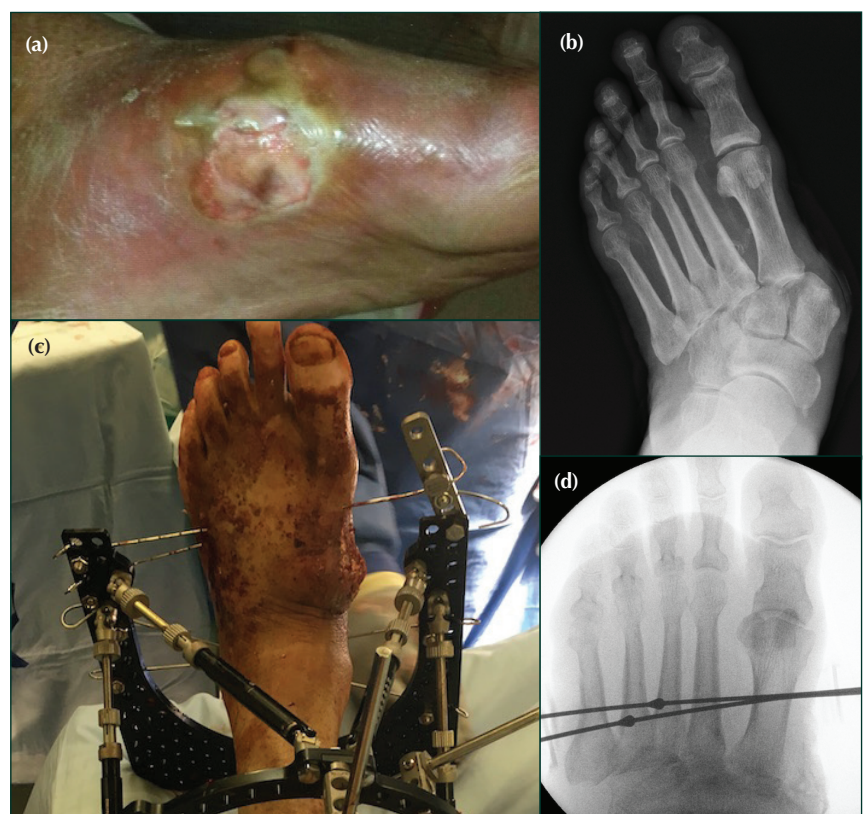

Figure 5. External fixation of deformity. (a, b) Acute midfoot Charcot deformity resulting in medial skin failure. (c, d) Stabilisation using a ring external fixator.

the ring fixator group, the nail group required more revision surgery due to deep infection and hardware issues. Interestingly, in a further comparative study of external fixator *versus* intramedullary nailing, a better union rate was found despite a greater complication rate (pin site infection, hardware loosening and surgical wound infection) in the external fixator group (ElAlfy et al, 2017).

Patients with CN may have underlying peripheral arterial disease and critical limb ischaemia (Palena et al, 2013). Therefore, it is prudent to investigate the quality of arterial flow in all cases of Charcot, regardless of palpable foot pulse. A vascular opinion should be sought in all cases where arterial supply to the limb is questionable.

Conclusion

The role of the orthopaedic surgeon has evolved to become an important part of the management of diabetic foot infections and deformity. Trainee surgeons need adequate exposure to various diabetic foot disease presentations to develop confidence and gain appropriate skills to deal with such cases. It may become desirable for future foot and ankle consultants to undergo a period of training in diabetic foot disease management. With the success of the multidisciplinary approach incorporating orthopaedic expertise into diabetic foot disease management, the outcomes for patients who suffer neuropathic complications is now very favourable. ■

Armstrong D, Boulton A, Bus S (2017) Diabetic foot ulcers and their recurrence. *N Engl J Med* 376(24): 2367–75

Armstrong D, Stacpoole-Shea S, Nguyen H, Harkless L (1999) Lengthening of the Achilles tendon in diabetic patients who are at high risk for ulceration of the foot. *J Bone Joint Surg Am* 81(4): 535–8

Bateman A, Bradford S, Hester TK, Tremlett J et al (2015) Modern orthopedic inpatient care of the orthopedic patient with diabetic foot disease. *Int J Low Extrem Wounds* 14(4): 384–92

Batista F, Nery C, Pinzur M et al (2008) Achilles tendinopathy in diabetes mellitus. *Foot Ankle Int* 29(5): 498–501

Bonanno D, Gillies E (2017) Flexor tenotomy improves healing and prevention of diabetes-related toe ulcers: a systematic review. *J Foot Ankle Surg* 56(3): 600–4

Broadsky J, Rouse A (1993) Exostectomy for symptomatic bony prominences in diabetic Charcot feet. *Clin Orthop Relat Res* (296): 21–6

Chraim M, Krenn S, Arabai H et al (2018) Mid-term follow-up of patients with hindfoot arthrodesis with retrograde compression intramedullary nail in Charcot neuroarthropathy of the hindfoot. *Bone Joint J* 100-B(2): 190–6

Cullen B, Weinraub G, Van Gompel G (2013) Early results with use of the midfoot fusion bolt in Charcot arthropathy. *J Foot Ankle Surg* 52(2): 235–8

ElAlfy B, Ali A, Fawzy S (2017) Ilizarov External Fixator versus retrograde intramedullary nailing for ankle joint arthrodesis in diabetic Charcot neuroarthropathy. *J Foot Ankle Surg* 56(2): 309–13

El-Gafary K, Mostafa K, Al-Adly W (2009) The management of

Charcot joint disease affecting the ankle and foot by arthrodesis controlled by an Ilizarov frame. *J Bone Joint Surg Br* 91-B(10): 1322–5

Eschler A, Wussow A, Ulmar B et al (2014) Intramedullary medial column support with the Midfoot Fusion Bolt (MFB) is not sufficient for osseous healing of arthrodesis in neuroosteoarthropathic feet. *Injury* 45(Suppl 1): 38–43

Fabrin J, Larsen K, Holstein P (2007) Arthrodesis with external fixation in the unstable or misaligned Charcot ankle in patients with diabetes mellitus. *Int J Low Extrem Wounds* 6(2): 102–7

Fabrin J, Larsen K, Holstein P (2000) Long-term follow-up in diabetic Charcot feet with spontaneous onset. *Diabetes Care* 23(6): 796–800

Hegewald K, Wilder M, Chappell T, Hutchinson B (2016) Combined internal and external fixation for diabetic Charcot reconstruction: a retrospective case series. *J Foot Ankle Surg* 55(3): 619–27

Joint Specialty Recommendations (2016) *Operational Delivery of the Multi-Disciplinary Care Pathway for Diabetic Foot Problems*. Diabetes UK. Available at: <https://bit.ly/2VqbWQl> (accessed 24 April 2019)

Kilicoglu O, Demirel M, Aktas S (2018) New trends in the orthopaedic management of diabetic foot. *EFORT Open Rev* 3(5): 269–77

Lowery N, Woods J, Armstrong D, Wukich D (2012) Surgical management of Charcot neuroarthropathy of the foot and ankle: a systematic review. *Foot Ankle Int* 33(2): 113–21

Mittlmeier T, Klaue K, Haar PB (2010) Should one consider primary surgical reconstruction in Charcot arthropathy of the feet? *Clin Orthop Relat Res* 468(4): 1002–11

Palena L, Brocco E, Ninkovic S et al (2013) Ischaemic Charcot foot: difference disease with different treatment. *J Cardiovasc* 54(5): 561–6

Papa J, Myerson M, Girard P (1993) Salvage, with arthrodesis, in intractable diabetic neuropathic arthropathy of the foot and ankle. *J Bone Joint Surg Am* 75(7): 1056–66

Pinzur M, Sage R, Stuck R et al (1993) A treatment algorithm for neuropathic (Charcot) midfoot deformity. *Foot Ankle Int* 14(4): 189–97

Prompers L, Huijberts M, Apelqvist J, Jude E et al (2007) High prevalence of ischemia, infection and serious comorbidity in patient with diabetic foot disease in Europe. Baseline results from the Eurodiale study. *Diabetologia* 50(1): 18–25

Richman J, Cota A, Weinfeld A (2017) Intramedullary Nailing and External Ring Fixation for Tibiotalocalcaneal Arthrodesis in Charcot Arthropathy. *Foot Ankle Int* 38(2): 149–52

Safavi P, Jupiter D, Panchbhavi V (2017) A systematic review of current surgical interventions for Charcot neuroarthropathy of the midfoot. *J Foot Ankle Surg* 56(6): 1249–52

Sammarco V, Chevillet J (2010) The role of internal fixation in surgery of the Charcot foot and the evolution of 'super-construct' techniques. *Current Orthopaedic Practice* 21(3): 233–9

Schneekloth B, Lowery N, Wukich D (2016) Charcot neuroarthropathy in patients with diabetes: an updated systematic review of surgical management. *J Foot Ankle Surg* 55(3): 586–90

Scott J, Hendry G, Locke J (2016) Effectiveness of percutaneous flexor tenotomies for the management and prevention of recurrence of diabetic toe ulcers: a systematic review. *J Foot Ankle Res* 9: 25

Siebachmeyer M, Boddu K, Bilal A et al (2015) Outcome of one-stage correction of deformities of the ankle and hindfoot and fusion in Charcot neuroarthropathy using a retrograde intramedullary hindfoot arthrodesis nail. *Bone Joint J* 97-B(1): 76–82

Simon S, Tejwani S, Wilson D et al (2000) Arthrodesis as an early alternative to nonoperative management of Charcot arthropathy of the diabetic foot. *J Bone Joint Surg Am* 82-A(7): 939–50

Stone N, Daniels T (2000) Midfoot and hindfoot arthrodeses in diabetic Charcot arthropathy. *Can J Surg* 43(6): 449–55

Tamir E, Tamir J, Beer YK, Finestone A (2015) Resection arthroplasty for resistant ulcers underlying the hallux in insensate diabetics. *Foot Ankle Int* 36(8): 969–75

Vas P, Edmonds M, Kavarthapu V et al (2018) The diabetic foot attack: "Tis too late to retreat!". *Int J Lower Extrem Wounds* 17(1): 7–13

Wiewiorski M, Yasui T, Miska MF, Valderrabano V (2013) Solid bolt fixation of the medial column in Charcot midfoot arthropathy. *J Foot Ankle Surg* 52(1): 88–94