

Case report: treatment of a diabetic foot ulcer with rare sesamoid osteomyelitis complicated by bacteraemia

Rebecca A Burmeister, Brian M Schmidt and Sari J Priesand

Citation: Burmeister RA, Schmidt BM, Priesand SJ (2020) Case report: treatment of a diabetic foot ulcer with rare sesamoid osteomyelitis complicated by bacteraemia. *The Diabetic Foot Journal* 23(3): 14–9

Article points

1. Diabetic foot ulcers with underlying sesamoid osteomyelitis are uncommon.
2. Localised sesamoid osteomyelitis associated with a diabetic foot ulcer can present challenges in diagnosis and treatment.
3. In this case, surgical resection of the osteomyelitis was needed to heal the diabetic foot ulcer.

Key words

- Diabetic foot complications
- Diabetic foot ulcer
- Diabetic limb salvage
- Osteomyelitis
- Sesamoid

Authors

Rebecca A Burmeister is Podiatry Fellow, Brian M Schmidt is Clinical Assistant Professor and Sari J Priesand is Clinical Assistant Professor all at Michigan Medicine, Department of Internal Medicine, Division of Metabolism, Endocrinology, and Diabetes, University of Michigan Medical School, Ann Arbor, MI, US.

Diabetic foot ulcers are a common complication in patients with diabetes. Diabetic foot ulcers with underlying sesamoid osteomyelitis are less commonly reported in the literature. A 48-year-old man with diabetes and complicated cardiac history warranting a new aortic valve replacement had been managed with a small, chronic diabetic foot ulcer to the plantar aspect of the left first metatarsal head and sesamoid apparatus. The diabetic foot ulcer was present for >13 consecutive months. Due to the chronicity with repetitive episodes of cellulitis, and concerning infectious changes of a bone scan to the medial sesamoid area, there was high concern for underlying sesamoid osteomyelitis. Localised sesamoid osteomyelitis associated with a diabetic foot ulcer can present challenges in diagnosis and treatment. In this case, antibiotic therapy was insufficient and surgical resection of the osteomyelitis was needed to heal the diabetic foot ulcer in a timely fashion so the patient could proceed with replacement of his bioprosthetic aortic valve.

Diabetic foot ulcers (DFUs) place a heavy burden on health systems globally (Hicks et al, 2016). The global prevalence of DFUs is 6.3%, and in the US, DFU prevalence is approximately 13% (Zhang et al, 2017). DFUs are the leading cause of a major lower-extremity amputations, such as below-knee or above-knee amputations (Hicks et al, 2016). Approximately 85% of all major lower-extremity amputations are preceded by a DFU (Hicks et al, 2016).

The financial burden of DFUs accounts for approximately one-third of all diabetes-related care costs (Driver et al, 2010; Hicks et al, 2016). DFUs are the leading diabetes complication requiring hospitalisation (Armstrong et al, 2017). Furthermore, more severe DFUs have been found to cost eightfold more to treat, compared to less severe ulcers (Driver et al, 2010). It is also well-known that DFUs have a high rate of recurrence, with 40% reoccurring within 1 year and approximately 65% reoccurring within 5 years (Armstrong et al, 2017).

Diabetic foot osteomyelitis (DFO) is the most

common infection associated with DFUs (Lázaro-Martínez et al, 2017). Osteomyelitis is present in about 10–15% of moderately infected DFUs, and about 50% of severely infected ulcers (Lipsky et al, 2006). Underlying osteomyelitis of a DFU makes diagnosis and treatment more difficult (Lipsky et al, 2012a; Lázaro-Martínez et al, 2017; Monteiro-Soares et al, 2020). Diagnosis can be complicated due to the varied presentations of DFO (Lázaro-Martínez et al, 2017).

Probe-to-bone testing, plain radiographs, and inflammatory markers, such as erythrocyte sedimentation rate (ESR) and C-reactive protein (CRP), are first-line tests that can help in diagnosing osteomyelitis, but false negatives are common (Lavery et al, 2007, 2019; Lázaro-Martínez et al, 2017). Advanced imaging, such as magnetic resonance imaging (MRI), can be more specific and sensitive to early osteomyelitis changes compared to plain films (Schwegler et al, 2008; Mandell et al, 2018). MRI has also been reported to be superior to positron emission tomography

(PET) and bone scintigraphy for diagnosing DFO, especially in DFU without underlying signs of osteomyelitis (Schwegler et al, 2008). Currently, the gold standard for DFO is a bone biopsy analysed with histopathology and microbiology (Bonham, 2001; Lipsky et al, 2012b; 2016).

For localised DFO that is not life- or limb-threatening, medical management with antibiotics with or without surgical resection of the infected bone are the available treatment options (Giurato et al, 2017). Sometimes, only part of the infected bone can be removed; in such cases, a combination of surgery and antibiotics are utilised (Giurato et al, 2017).

A previous study found 66% of non-ischaemic DFO was successfully treated with antibiotics and no surgery (Tone et al, 2017). This study also found little difference in treatment of osteomyelitis with 6 weeks compared to 12 weeks of antibiotic therapy.

Other studies have also demonstrated the benefits of a conservative surgical resection of the DFO prior to attempting long-term antibiotics. A conservative surgical resection of the DFO in conjunction to antibiotics alone demonstrated more success at treating the infection (78% versus 57%), with shorter use of antibiotics, and shorter time to being fully healed, compared to antibiotics alone (Ha Van et al, 1996). There is a plethora of research supporting these different options for DFO, and currently the treatment plan is still considered on an individual case basis (Ha Van et al, 1996; Giurato et al, 2017; Tone et al, 2017).

Localised sesamoid osteomyelitis from a DFU is rare, and it is more common for osteomyelitis of the sesamoid to be caused by a puncture wound (Karasick and Schweitzer, 1998). A study of isolated sesamoid osteomyelitis without metatarsal head involvement took 13 years to acquire 18 patients with sesamoid osteomyelitis (Mauler et al, 2017). Osteomyelitis was diagnosed with imaging changes (i.e. MRI, computed tomography, or plain radiographs) in conjunction with an ulcer that probed to bone. All 18 patients were first treated non-surgically with wound care, offloading and antibiotics. The non-surgical therapy ranged from 4 weeks to 9 months. Ultimately, 15 of the 18 patients required surgical excision or amputation of the osteomyelitis to heal their associated ulcer. This study alludes to the difficulty of treating

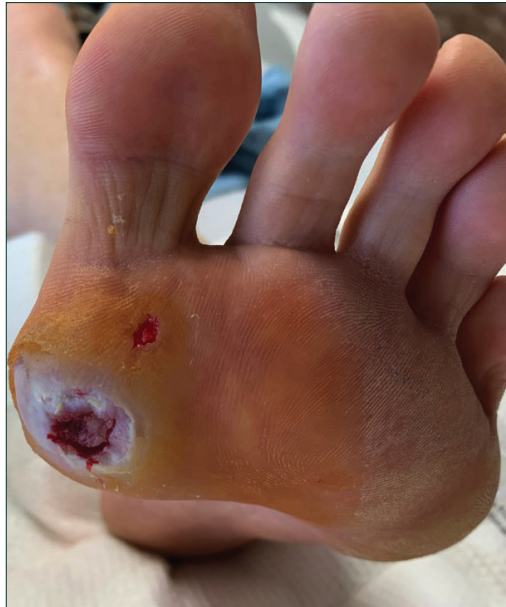

Figure 1: Left foot DFU after debridement on day one of hospital admission.

sesamoid osteomyelitis, compared to osteomyelitis of other areas of the foot that are more responsive to antibiotic treatment (Mauler et al, 2017).

Case presentation

A 48-year-old man was admitted to a tertiary hospital for acute cellulitis associated with a chronic right foot DFU at the plantar aspect of the first metatarsal head. The DFU had been present for 13 months. The ulcer was never >2 cm in diameter and never probed to bone on clinical examination.

The DFU contributed to four hospital admissions for acute signs of associated infection. During his first hospitalisation, 10 months after ulcer onset, the DFU had associated cellulitis with no suspected osteomyelitis. A deep tissue culture grew clindamycin-sensitive *Streptococcus anginosus*. During this first admission, he required 3 days of IV clindamycin, followed by 5 days of oral clindamycin.

At the second hospitalisation (11 months after DFU onset), he was prescribed 14 days of oral clindamycin. In the third hospitalisation (12.5 months after DFU onset), he received IV clindamycin for 25 hours and then oral clindamycin for an additional 14 days. Seven days after this hospital discharge, he had worsening signs of infection associated with the DFU, despite oral clindamycin. He presented to the emergency

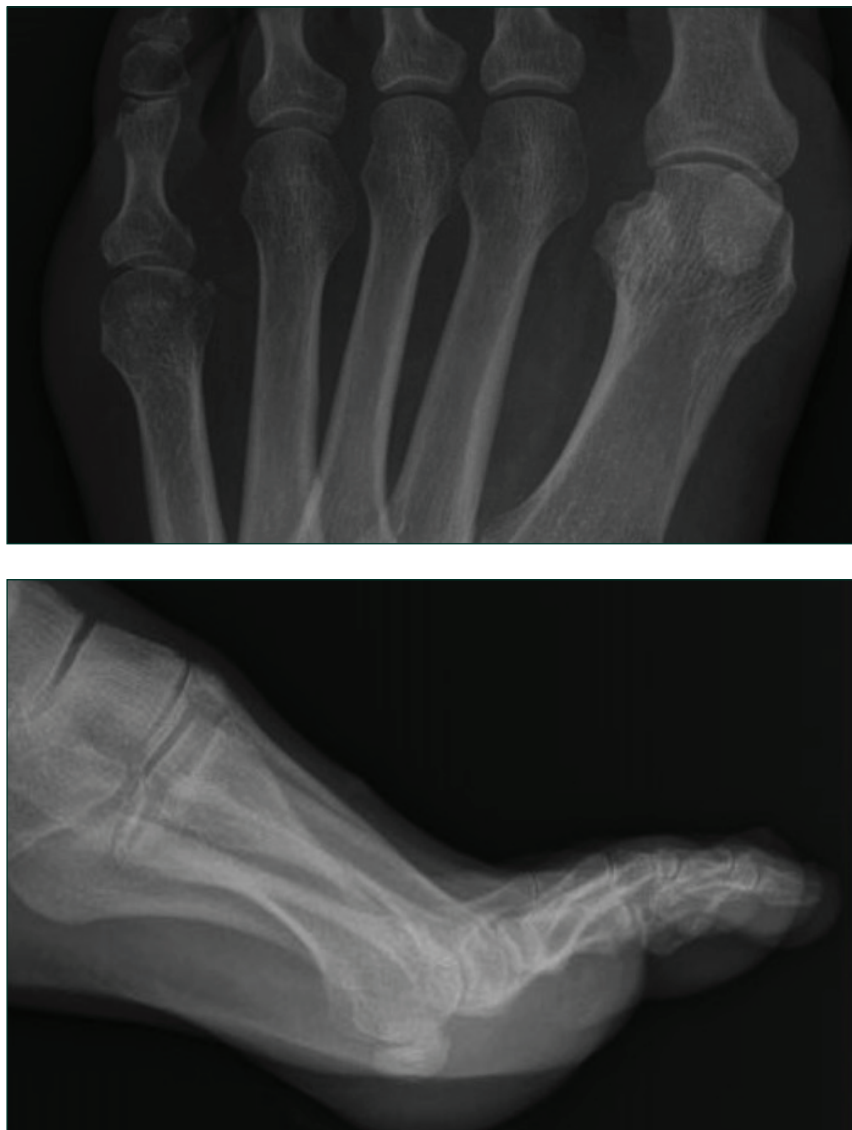

Figure 2: Left foot X-rays showed no signs of osteomyelitis or soft tissue gas.

department and was admitted for the fourth time (approximately 13 months after DFU onset).

In the outpatient setting, his ulcer was being treated at a comprehensive wound clinic with regular debridement, local wound care and offloading. Throughout the course of the DFU, the wound care consisted of an antimicrobial alginate dressing when no signs of infection were present and betadine with a dry dressing when acute signs of infection were present. Offloading was difficult for the patient since he was younger and active. He was reluctant to attempt total contact casting and primarily used his offloading wound shoe when ambulating.

His medical and surgical history included type 2 diabetes (T2D) with peripheral neuropathy and retinopathy, aortic valve replacement for congenital aortic stenosis, implantable cardioverter-defibrillator (ICD) for non-sustained ventricular tachycardia, atrial fibrillation, tricuspid regurgitation, aortic stenosis, congestive heart failure, oesophageal adenocarcinoma in remission and previous stroke with no residual deficits. Of note, he had an allergy to penicillin. His T2D was poorly controlled with an HbA_{1c} of 10.4%. At the time of the fourth admission, his T2D was being treated with metformin, insulin lispro and empagliflozin, alongside lifestyle efforts.

At presentation, he displayed systemic signs of infection, including nausea, chills, malaise and weakness. He was haemodynamically stable and afebrile. The DFU was a full thickness ulcer to the plantar first metatarsal head of the left foot. It had a granular base that did not probe to bone. There was an increase of non-purulent, serosanguinous drainage from the DFU, with increased pain in his otherwise baseline insensate foot due to neuropathy. There was minimal erythema <2cm in diameter around the DFU and very minimal oedema to the left forefoot. There was no crepitus, malodour, fluctuance, or other acute signs of infection associated with the DFU. He had palpable pedal pulses and brisk capillary refill time to the toes bilaterally. Previous ankle brachial index and toe brachial index studies demonstrated no peripheral vascular occlusive disease.

A bedside DFU debridement was performed, including subcutaneous tissue. A deep tissue culture was obtained during this debridement. There was no appreciable deeper abscess. After debridement, the DFU still did not probe to bone. The DFU base was granular and bleeding after the debridement. The DFU measured 10 mm × 8 mm and was 2 mm deep. There was a superficial wound just distal and lateral to the main DFU. This was a new blister at this presentation and was also debrided. The blister and DFU did not communicate. The blister measured 2 mm × 2 mm and was 1 mm deep. *Figure 1* shows the DFU after debridement.

The patient had a normal white blood cell count at 8.6K/ul. His inflammatory markers were subthreshold for osteomyelitis (Lavery et al, 2019). ESR was 36 mm/h and CRP was 3.3 mg/dl. He had

one set of blood cultures positive for *Streptococcus mitis*, with single resistance to clindamycin. The deep tissue wound culture was positive for *S. anginosus*, which had multi-drug resistance to clindamycin and tetracycline. The plain X-rays of the left foot showed no signs of osteomyelitis or soft tissue gas (Figure 2). Due to the patient's ICD, he was unable to have an MRI of the left foot. A technetium 99 hexamethylpropylene amine oxime (Tc-99 HMPAO) bone scan was performed and displayed a focal uptake of radiotracer at the medial sesamoid bone and was inconclusive for uptake at the first metatarsal head (Figure 3). He was then started on IV vancomycin.

The patient was also having worsening congestive heart failure and bioprosthetic aortic valve degeneration with severe aortic stenosis and regurgitation. Transoesophageal echocardiogram, echocardiogram and cardiac PET scan did not have findings suggestive of infectious endocarditis. However, due to the worsening cardiac status, the cardiology and thoracic surgery teams felt the prosthetic aortic valve and ICD would need to be replaced over the next few months. The replacement of these cardiac implants was not a safe option until the DFU and associated infection was resolved.

The patient was discharged home with a peripherally inserted central catheter (PICC) for ceftriaxone administration. He had been given the options of trying 6 weeks of ceftriaxone through the PICC or surgical resection of the infection. He was also given the options of a medial sesamoidectomy or partial first ray amputation, since the Tc-99 HMPAO had been inconclusive for osteomyelitis of the first metatarsal head. Due to the chronicity of the DFU, repetitive cellulitis events associated with the DFU, positive blood cultures with no other sources, and the localised changes the sesamoid region on Tc-99 HMPAO, it was presumed there was osteomyelitis of the sesamoids.

After 3 weeks of ceftriaxone, the patient was still not noticing any improvement in the ulcer size and he decided to proceed with a partial first ray amputation. The more aggressive resection would minimise the need for potential additional surgery due to any residual underlying osteomyelitis. The partial first ray amputation was performed at an outpatient surgical centre and he was discharged home the same day. He had an uncomplicated post-

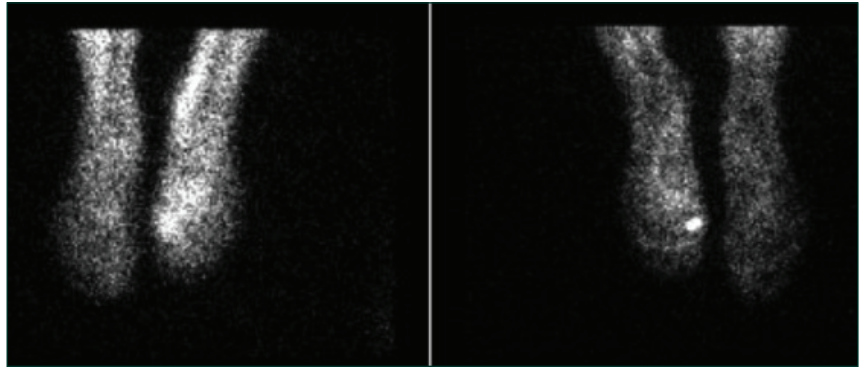


Figure 3: Tc-99 HMPAO white cell bone scan showed focal radiotracer uptake in the left foot at the medial sesamoid and possibly the first metatarsal head.

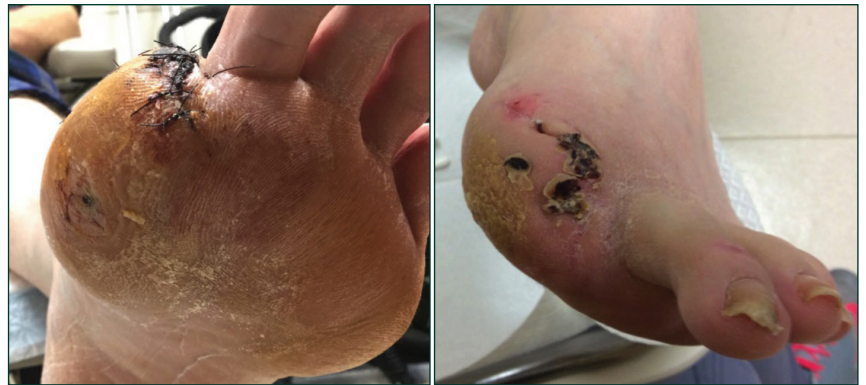

Figure 4. Healed DFU and partial first ray amputation at post-operative day 26.

operative course and the amputation site and DFU healed in 26 days (Figure 4). He continued and completed the 6 weeks of ceftriaxone through a PICC in the peri-operative period. The ceftriaxone was not help for collection of surgical cultures

No organism growth was found on the first metatarsal proximal bone margin. Pathology examination of the sesamoids concluded they were benign bone, and the first metatarsal was reactive with no active osteomyelitis.

At 1 year after the amputation, he has not had any recurrence of the initial ulcer or new DFUs to the left foot. Within 3 months of healing his left foot DFU and amputation site, he required three different cardiac catheterisation procedures and, ultimately, his bioprosthetic aortic valve replaced. His ICD was replaced 7 months after complete left foot healing.

Discussion

The sesamoid anatomy may contribute to some of the difficulty in treating osteomyelitis with

antibiotic therapy alone, as indicated in the study by Mauler et al (2017). Sesamoids naturally have limited blood supply (Sims and Kurup, 2014). The limited blood flow enters at the proximal aspect of the bone, and is diminished further at the distal aspect (Sims and Kurup, 2014). The tenuous blood flow to the sesamoid has been attributed to the often delayed, or non-unions that occur to fractured sesamoids (Rath, 2009).

The chronicity of this patient's DFU, the resistance to clindamycin, in conjunction with the repetitive bouts of cellulitis that required hospitalisation and antibiotics raised clinical suspicion for underlying DFO. The DFU remained <4cm² in surface area over the 13 months. There was no significant change in the size of the DFU throughout the non-surgical treatment course.

A DFU not decreasing in surface area of at least 50% throughout the first 4 weeks has less than a 10% healing rate at 12 weeks (Sheehan et al, 2006). The lack of DFU improvement was concerning for potential underlying osteomyelitis, or could indicate that the patient was not offloading as instructed.

This DFU was 5 mm at its deepest and never probed to bone. A previous study of 247 patients with a DFU, found that the probe to bone test was highly sensitive (0.87), specific (0.91), with a high negative predictive value (0.98), but a modest positive predictive value (0.57) (Lavery et al, 2007).

Throughout the course of the patient's DFU, he never had inflammatory markers elevated to levels concerning for osteomyelitis. An ESR >60 mm/h has a sensitivity of 74% and specificity of 56% of osteomyelitis (Lavery et al, 2019). A CRP >7.9 mg/dl has a sensitivity of 49% and specificity of 80% for DFO (Lavery et al, 2019). An ESR <30 mm/h has a very low probability of DFO (Lavery et al, 2019). The highest levels of the patient's ESR and CRP throughout the course of the DFU were 36 mm/h and 3.3 mg/dl, respectively. However, inflammatory markers alone are not sufficient to diagnose DFO. A study by Van Asten et al (2017) found ESR and CRP levels did not significantly differ in patients with a DFU and osteomyelitis compared to patients with a DFU and no underlying osteomyelitis.

Plain X-rays were taken regularly throughout the course of the patient's DFU. There were never significant changes to the sesamoids or the first metatarsal head on plain X-rays. Periodic sesamoid

axial view may have been helpful for monitoring the sesamoids for changes. Osteomyelitis changes to bone can take 2–3 weeks to show on plain X-rays, and usually at least 50% of cortical destruction is needed for these changes to be visible on radiographs (Mandell et al, 2018).

Due to the limited nature of plain X-rays, advanced imaging is a non-invasive measure to help in the diagnosis of osteomyelitis (Mandell et al, 2018). MRI has demonstrated superiority for detecting DFO compared to other imaging techniques, such as PET or bone scans (Schwegler et al, 2008; Mandell et al, 2018). However, the patient's cardiac implants meant he could not have an MRI. The Tc-99 HMPAO was used to assess for osteomyelitis, but was inconclusive for involvement of the first metatarsal head. An MRI would have been able to distinguish the marrow changes more readily than Tc-99 HMPAO, the authors' chosen imaging option.

However, after not seeing clinical improvement with medical management, offloading, and local wound care, and given his cardiac issues necessitating resolution of his infection, more aggressive surgical options were recommended.

Previous research has demonstrated that residual osteomyelitis after amputation for DFO resulted in 2.6 times more hospital readmissions and more post-operative complications (Schmidt et al, 2019). There was also a concern for DFO remission that could potentially be a source of infection for his needed new cardiac implants if the DFU healed fully while on antibiotics. While antibiotics are an effective treatment option for DFO, the duration of osteomyelitis remission is currently not predictable based on current studies. White blood cell-single photon emission computed tomography has been found to be helpful for determining that remission has been reached, but there is no current study that has determined how long the DFO will remain in remission (Vouillarmet et al, 2017).

The histopathology found benign bone of the sesamoid and reactive first metatarsal head bone. The microbiology cultures of the first metatarsal head were negative for bacterial growth, and served as a clear margin. Microbiology cultures were not performed on the sesamoids since they were fully resected, and could no longer serve as a source of infection. Lack of microbiology testing

on the sesamoids was a limitation and should have been performed for research purposes. However, we feel strongly that the pre-operative chronic nature of the DFU was caused by the underlying sesamoid osteomyelitis and the fact he has remained DFU free after the partial first ray amputation is rather convincing of the pre-operative sesamoid osteomyelitis diagnosis.

Conclusion

Localised sesamoid osteomyelitis from a DFU is a rare finding and can complicate DFU healing. In this case the DFU surface area remained small <4 cm² and at its deepest was 5 mm. The chronicity of the wound with the reoccurring cellulitis were concerning, and heightened the suspicion of underlying osteomyelitis despite preliminary tests such as clinical appearance, probe to bone, plain radiographs and inflammatory markers were negative for osteomyelitis. The Tc-99 HMPAO bone scan was helpful in finding reactive changes to the medial sesamoid. An MRI may have offered more information, but was contraindicated due to the patient's cardiac implants.

DFU with sesamoid osteomyelitis should be considered for recalcitrant DFU at the first metatarsal head. If osteomyelitis is present to the sesamoid, successful DFU healing without surgery has a low success rate, and in this case antibiotics were not sufficient at clearing the underlying osteomyelitis. For our patient, wide surgical resection was indicated to clear all underlying infected bone, to minimise risk of postoperative complications, given his pressing cardiac issues with pending surgical valve replacement. ■

- Armstrong DG, Boulton AJM, Bus SA (2017) Diabetic foot ulcers and their recurrence. *N Engl J Med* 376(24): 2367–75
- Bonham P (2001) A critical review of the literature: part II: antibiotic treatment of osteomyelitis in patients with diabetes and foot ulcers. *J Wound Ostomy Continence Nurs* 28(3): 141–9
- Driver VR, Fabbi M, Lavery LA, Gibbons G (2010) The costs of diabetic foot: the economic case for the limb salvage team. *J Vasc Surg* 52(3 Suppl): 17S-22S
- Giurato L, Meloni M, Izzo V, Uccioli L (2017) Osteomyelitis in diabetic foot: A comprehensive overview. *World J Diabetes* 8(4): 135–42
- Ha Van G, Siney H, Danan JP et al (1996) Treatment of osteomyelitis in the diabetic foot. Contribution of conservative surgery. *Diabetes Care* 19(11): 1257–60
- Hicks CW, Selvarajah S, Mathioudakis N et al (2016) Burden of infected diabetic foot ulcers on hospital admissions and costs. *Ann Vasc Surg* 33: 149–58
- Karasick D, Schweitzer ME (1998) Disorders of the hallux sesamoid complex: MR features. *Skeletal Radiol* 27(8): 411–8
- Lavery LA, Ahn J, Ryan EC et al (2019) What are the optimal cutoff values for ESR and CRP to diagnose osteomyelitis in patients with diabetes-related foot infections? *Clin Orthop Relat Res* 477(7): 1594–602
- Lavery LA, Armstrong DG, Peters EJ, Lipsky BA (2007) Probe-to-bone test for diagnosing diabetic foot osteomyelitis: reliable or relic? *Diabetes Care* 30(2): 270–4
- Lázaro-Martínez JL, Tardáguila-García A, García-Klepzig JL (2017) Diagnostic and therapeutic update on diabetic foot osteomyelitis. *Endocrinol Diabetes Nutr* 64(2): 100–8
- Lipsky BA, Berendt AR, Deery HG et al (2006) Diagnosis and treatment of diabetic foot infections. *Plast Reconstr Surg* 117(7 Suppl): 212s–38s
- Lipsky BA, Peters EJ, Berendt AR et al (2012a) Specific guidelines for the treatment of diabetic foot infections 2011. *Diabetes Metab Res Rev* 28(Suppl 1): 234–5
- Lipsky BA, Berendt AR, Cornia PB et al (2012b) 2012 Infectious Diseases Society of America clinical practice guideline for the diagnosis and treatment of diabetic foot infections. *Clin Infect Dis* 54(12): e132–73
- Lipsky BA, Aragón-Sánchez J, Diggle M et al (2016) IWGDF guidance on the diagnosis and management of foot infections in persons with diabetes. *Diabetes Metab Res Rev* 32(Suppl 1):45–74
- Mandell JC, Khurana B, Smith JT et al (2018) Osteomyelitis of the lower extremity: pathophysiology, imaging, and classification, with an emphasis on diabetic foot infection. *Emerg Radiol* 25(2): 175–88
- Mauler F, Wanivenhaus F, Böni T, Berli M (2017) Nonsurgical treatment of osteomyelitis of the hallux sesamoids: a case series and literature review. *J Foot Ankle Surg* 6(3): 666–9
- Monteiro-Soares M, Russell D, Boyko EJ et al (2020) Guidelines on the classification of diabetic foot ulcers (IWGDF 2019). *Diabetes Metab Res Rev* 36(Suppl 1): e3273
- Rath B, Notermans HP, Frank D et al (2009) Arterial anatomy of the hallux sesamoids. *Clin Anat* 22(6): 755–60
- Schmidt BM, McHugh JB, Patel RM, Wrobel JS (2019) Prospective analysis of surgical bone margins after partial foot amputation in diabetic patients admitted with moderate to severe foot infections. *Foot Ankle Spec* 12(2): 131–7
- Schwegler B, Stumpe KD, Weishaupt D et al (2008) Unsuspected osteomyelitis is frequent in persistent diabetic foot ulcer and better diagnosed by MRI than by 18F-FDG PET or 99mTc-MOAB. *J Intern Med* 263(1): 99–106
- Sheehan P, Jones P, Giurini JM et al (2006) Percent change in wound area of diabetic foot ulcers over a 4-week period is a robust predictor of complete healing in a 12-week prospective trial. *Plast Reconstr Surg* 117(7 Suppl): 239S–44S
- Sims AL, Kurup HV (2014) Painful sesamoid of the great toe. *World J Orthop* 5(2): 146–50
- Tone A, Nguyen S, Devemy F et al (2015) Six-week versus twelve-week antibiotic therapy for nonsurgically treated diabetic foot osteomyelitis: a multicenter open-label controlled randomized study. *Diabetes Care* 38(2):302–7
- Van Asten SA, Nichols A, La Fontaine J et al (2017) The value of inflammatory markers to diagnose and monitor diabetic foot osteomyelitis. *Int Wound J* 14(1): 40–5
- Vouillarmet J, Moret M, Morelec I et al (2017) Application of white blood cell SPECT/CT to predict remission after a 6 or 12 week course of antibiotic treatment for diabetic foot osteomyelitis. *Diabetologia* 60(12): 2486–94
- Zhang P, Lu J, Jing Y et al (2017) Global epidemiology of diabetic foot ulceration: a systematic review and meta-analysis. *Ann Med* 49(2): 106–16