

Enteric hyperoxaluria and oxalate nephropathy in an individual taking orlistat

Joanna Kennedy, Lucinda Summers, David New

Citation: Kennedy J, Summers L, New D (2013) Enteric hyperoxaluria and oxalate nephropathy in an individual taking orlistat. *Diabetes in Practice* 2: 88–90

Article points

1. Orlistat is a weight reduction medication that is recommended for use in obese people who are unable to achieve weight loss through lifestyle modifications.
2. Orlistat is an inhibitor of gastro-pancreatic lipases and induces fat mal-absorption. Previous studies have linked increased intestinal oxalate absorption to fat mal-absorption.
3. The authors describe a case report of an obese individual with type 2 diabetes, who displayed a deterioration in renal function and raised urinary oxalate with orlistat therapy.

Key words

- Obesity
- Orlistat
- Oxalate crystal nephropathy

Authors

Author details can be found at the end of the article.

Orlistat, marketed worldwide as Xenical® or Alli®, is a weight reduction medication. This case report describes an obese individual with type 2 diabetes who was treated with orlistat and presented with deterioration in renal function and raised urinary oxalate, which normalised when orlistat was discontinued. Renal biopsy confirmed calcium oxalate nephropathy. Orlistat, a gastro-pancreatic lipase inhibitor, causes fat mal-absorption. Increased intestinal oxalate absorption, known as enteric hyperoxaluria, can be caused by fat mal-absorption. Oxalate nephropathy is a potential and serious side effect of orlistat, an increasingly prescribed and easily obtainable medication.

Oxalate nephropathy is an unusual condition characterised by hyperoxaluria and kidney damage due to oxalate crystal deposition. Secondary hyperoxaluria is more common than the rare autosomal recessive primary hyperoxaluria. Increased absorption of oxalate, named enteric hyperoxaluria, occurs in mal-function of the small intestine or in defective fat absorption (Courtney et al, 2007). When obese people are unable to achieve weight loss through lifestyle modifications, orlistat, an inhibitor of gastro-pancreatic lipases, is used to induce fat mal-absorption.

Case report

A 47-year-old Caucasian male with a history of hypertension, type 2 diabetes and obesity lost 22 kg, reducing his HbA_{1c} from 69 mmol/mol (8.5%) to 54 mmol/mol (7.1%), over 1 year of orlistat therapy. Five months into treatment, he presented with deteriorating renal function; his estimated glomerular filtration rate (eGFR) had decreased from a baseline of 62 mL/min/1.73 m² to 19 mL/min/1.73 m² with a corresponding increase in serum creatinine (113 µmol/L to 308 µmol/L). Despite this, he felt well. His examination was

unremarkable; he was normotensive and there were no heart murmurs, renal bruits, splinter haemorrhages or rashes. Liraglutide, ranitidine and metformin were discontinued and the dose of furosemide was reduced. However, dihydrocodeine, pregabalin, simvastatin, irbesartan, atenolol, amlodipine, citalopram, aspirin, orlistat and insulin were continued.

ANCA, ANA, anti-GBM antibody, serum electrophoresis hepatitis B sAg and hepatitis B antibody were negative. Urinalysis revealed trace protein but no blood. Ultrasound showed no abnormalities of the kidneys, prostate or bladder. Given his high BMI and partial improvement in renal function after discontinuation of the listed medications, a kidney biopsy was not performed. He was presumed to have underlying diabetic hypertensive nephropathy with possible drug-related interstitial nephritis. Three months after the initial presentation, creatinine was still 144 µmol/L and eGFR was 47 mL/min/1.73 m². A kidney biopsy subsequently showed tubulointerstitial nephritis with oxalate crystals in the tubular interstitium, lumina and epithelial cells (*Figure 1*). Given the possibility of orlistat-induced oxalate nephropathy, 24-hour urinary oxalate was measured and found to be elevated at 750 (normal:

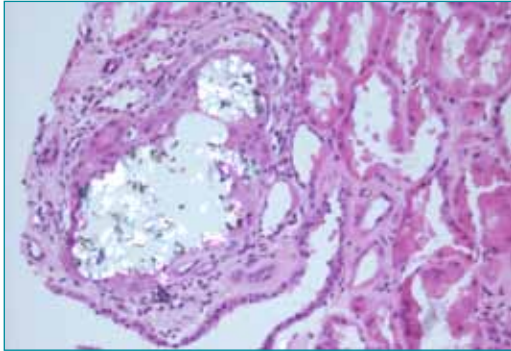


Figure 1. Renal biopsy stained with haematoxylin and eosin under partly polarised light showing oxalate crystal deposition in the giant cells of the tubulo-interstitium associated with scarring. Similar crystals are present in the cytoplasm of tubular lumina and epithelial cells.

80–490 $\mu\text{mol}/24$ hours) with decreased citrate, 0.461 (normal: 1.680–6.450 mmol/24 hours). Orlistat was discontinued. A high fluid intake (>3 L/day), restriction of dietary oxalate and discontinuation of over-the-counter multivitamins were advised. Six weeks later, eGFR was 40 mL/min/1.73 m^2 (Figure 2) and urinary oxalate had improved (384 $\mu\text{mol}/24$ hours).

Discussion

We present the case of an obese individual with early diabetic nephropathy who developed hyperoxaluria and renal impairment during orlistat therapy. After discontinuation of treatment, urinary oxalate levels normalised and renal function recovered partially. A renal biopsy

showed crystal nephropathy with severe scarring, suggestive of oxalate nephropathy. Orlistat, shown to increase urinary oxalate excretion in humans and animals respectively (Singh et al, 2007; Sarica et al, 2008), is associated with oxalate nephropathy (Ferraz et al, 2004; Courtney et al, 2007; Singh et al, 2007; Karamadoukis et al, 2008; Karamadoukis et al, 2009; Korzets et al, 2009; Ahmed, 2010). A retrospective study of 855 renal biopsies found that of 20 cases of acute tubular necrosis (ATN), two, showing oxalate crystals and ATN, were taken from people receiving orlistat (Karamadoukis et al, 2008). In another case report (Singh et al, 2007), acute-on-chronic kidney dysfunction (CKD) and biopsy positive oxalate nephropathy was observed in an individual 2 months into orlistat therapy. Upon its discontinuation, renal function returned to baseline. Repeat biopsy confirmed resolution of oxalate crystals. Renal function did not recover in two cases (Courtney et al, 2007; Karamadoukis et al, 2009). In the first, a person with CKD developed irreversible renal failure necessitating permanent haemodialysis after 5 months of orlistat therapy (Courtney et al, 2007). Renal biopsy showed intra-tubular calcium oxalate and tubulo-interstitial inflammation. The second (Karamadoukis et al, 2009) describes the case of a 66-year-old person with type 2 diabetes, who, 3 months into orlistat therapy, presented with acute kidney injury necessitating haemodialysis, resulting in eventual death. Renal biopsy

“We were able to confirm the presence of oxalate-type crystals, which are brightly birefringent in polarised light. Whilst oxalate deposition occurs in acute tubular necrosis, given the distribution pattern, we postulate that oxalate toxicity to tubule epithelial cells resulted in interstitial nephritis and deposition of crystals in the interstitium.”

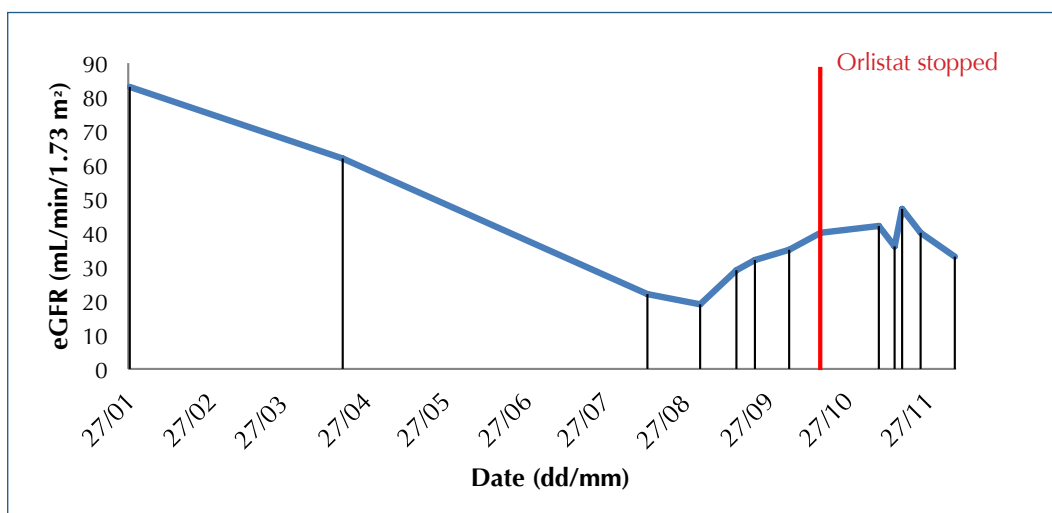


Figure 2. Drop in eGFR over 8 months of orlistat therapy. Orlistat discontinuation resulted in some improvement.

“Overall, the high urinary oxalate, biopsy findings and improvement in urinary oxalate upon withdrawal of orlistat support the diagnosis of oxalate nephropathy associated with orlistat therapy.”

Authors

Joanna Kennedy is a Foundation Doctor at North Middlesex University Hospital, London; Lucinda Summers is a Consultant in Endocrinology and Honorary Senior Lecturer at Salford Royal Foundation Trust and Associate Clinical Lead for the Diabetes and Obesity Research Network, Manchester; and David New is Clinical Lead for Haemodialysis Governance, Salford Royal Foundation Trust.

confirmed ATN and oxalate crystals. In all of these cases, acute kidney injury due to ATN was deemed secondary to orlistat-induced oxalate nephropathy.

Orlistat therapy induces fat mal-absorption. Excess fat reacts with and carries calcium to the large bowel, reducing the formation of calcium oxalate-insoluble compounds. This process and the presence of free bile salts enhance the absorption of free oxalate. When the urine becomes supersaturated, crystals form. We were able to confirm the presence of oxalate-type crystals, which are brightly birefringent in polarised light. Whilst oxalate deposition occurs in ATN, given the distribution pattern, we postulate that oxalate toxicity to tubule epithelial cells resulted in interstitial nephritis and deposition of crystals in the interstitium. The low citrate, which chelates calcium and reduces supersaturation, favoured crystal formation. Supplementation of vitamin C, which is excreted by the kidneys, converted to oxalate and aids absorption of oxalate (Massey et al, 2005), could have intensified the hyperoxaluria

Multivitamins are prescribed in the context of weight reducing diets or following bariatric surgery. We argue that vitamin C should not be taken in situations where enteric hyperoxaluria is likely (Weiss, 2010). Overall, the high urinary oxalate, biopsy findings and improvement in urinary oxalate upon withdrawal of orlistat

support the diagnosis of oxalate nephropathy associated with orlistat therapy. We advocate that there should be more frequent monitoring of renal function in orlistat use. As obesity is becoming more prevalent, orlistat is increasingly used with availability over-the-counter. There needs to be a greater awareness of the possibility of oxalate nephropathy and its consequences in orlistat use. ■

Ahmed MH (2010) Orlistat and calcium oxalate crystalluria: an association that needs consideration. *Ren Fail* **32**: 1019–21

Courtney AE, O'Rourke DM, Maxwell AP (2007) Rapidly progressive renal failure associated with successful pharmacotherapy for obesity. *Nephrol Dial Transplant* **22**: 621–3

Ferraz RR, Tiselius HG, Heiberg IP (2004) Fat malabsorption induced by gastrointestinal lipase inhibitor leads to an increase in urinary oxalate excretion. *Kidney Int* **66**: 676–82.

Karamadoukis L, Ludeman L, Williams AJ (2008) Is there a link between calcium oxalate crystalluria, orlistat and acute tubular necrosis? *Nephrol Dial Transplant* **23**: 1778–9

Karamadoukis L, Shivashankar GH, Ludeman L (2009) An unusual complication of treatment with orlistat. *Clin Nephrol* **71**: 430–2

Korzets A, Gafter U, Tobar A (2009) Furosemide, orlistat and non-steroidal anti-inflammatory agents—too much for the kidneys to handle! *Nephrol Dial Transplant Plus* **2**: 167–70

Massey LK, Liebman M, Kynast-Gales SA (2005) Ascorbate increases human oxaluria and kidney stone risk. *J Nutr* **135**: 1673–7

Sarica K, Akarsu E, Erturhan S (2008) Evaluation of urinary oxalate levels in patients receiving gastrointestinal lipase inhibitor. *Obesity* **16**: 1579–84

Singh A, Sarkar SR, Gaber LW (2007) Acute oxalate nephropathy associated with orlistat, a gastrointestinal lipase inhibitor. *Am J Kidney Dis* **49**: 153–7

Weiss D (2010) Bariatric surgery, vitamin C, and kidney stones. *Cleve Clin J Med* **77**: 844