

Regional anaesthesia with ankle block for acute diabetic foot surgery

Natasha Chinai, Mohamed Saleem Noormohamed, Ian Crabb, Jonathan J Earnshaw

Citation: Chinai N, Noormohamed MS, Crabb I, Earnshaw JJ (2016) Regional anaesthesia with ankle block for acute diabetic foot surgery. *The Diabetic Foot Journal* 19: 10–3

Article points

1. People with diabetes and vascular disease frequently require minor foot surgery, often as an emergency.
2. In many hospitals such procedures are done under general anaesthetic, which exposes patients, who are often septic, to potential complications.
3. Two surgical registrars learned how to do an ankle block, and then undertook 25 consecutive, urgent debridement procedures using the technique, with good patient satisfaction and no complications.
4. Most minor diabetic foot surgery could be done under regional analgesia, sparing patients the risk of general anaesthesia.

Key words

- Ankle block
- Diabetes
- Gangrene of toe
- Infection of toe

Authors

Natasha Chinai is a Vascular Specialist Trainee, Mohamed Saleem Noormohamed is a Specialist Surgical Registrar; Ian Crabb is a Consultant Anaesthetist; and Jonathan J Earnshaw is a Consultant Vascular Surgeon. All are based at Gloucestershire Hospitals NHS Foundation Trust, Cheltenham, UK

The aim of the authors was to determine whether regional anaesthesia using an ankle block is a safe and effective alternative to a general anaesthetic during acute diabetic foot surgery. Two vascular registrars were trained to perform an ankle block by the lead consultant vascular anaesthetist and consecutive people with diabetes with a foot infection or necrosis that required drainage or digital amputation(s) were performed under ankle block undertaken by the vascular trainees. Twenty-five people with diabetes underwent foot debridement and/or digital amputation with an ankle block and the procedure success rate was 100%. All patients tolerated it well with, no systemic or physiological complications and no patient required supplemental local anaesthesia or conversion to general anaesthetic. Also, non of the patients required re-operation for inadequate tissue clearance. Ankle block was found to be a safe and effective method of providing anaesthesia for acute diabetic foot surgery. It has a number of clinical advantages compared to routine general anaesthesia. The technique is simple to learn and could be easily incorporated into a modern vascular practice.

The number of people with diabetes is increasing dramatically (Whiting et al, 2011). With this development, many more people are developing vascular complications, such as diabetic neuropathy and peripheral vascular disease. Infection and ulceration of the foot among people with diabetes is common, and frequently requires urgent inpatient treatment for intravenous antibiotics, abscess drainage, debridement and even amputation. The lifetime risk of developing a diabetic foot infection is up to 15% (Boulton et al, 2005). In addition to diabetes and its associated macro- and micro-vascular complications, many of these people have significant comorbidities making them high-risk candidates for general anaesthesia.

Regional anaesthesia for foot surgery is not a new concept. It can avoid potential morbidity (and even mortality) associated with general anaesthesia (Schurman, 1976; Rudkin et al, 2005;

Foot et al, 2012), yet this form of anaesthesia has not achieved widespread use in the treatment of acute diabetic foot problems. Many vascular surgeons use regional anaesthesia as an adjunct to general anaesthesia for postoperative pain relief, but an ankle block on its own is a safe and effective alternative to general anaesthesia for most forefoot surgery, particularly in people with diabetes who often have a neurosensory deficit around the toes already. Furthermore, an ankle block provides no motor blockade, allowing early postoperative remobilisation.

There are a number of potential barriers to regional anaesthesia for acute foot surgery. First, there is a lack of knowledge concerning the technique among surgeons who consent patients for acute foot surgery. Most ankle blocks are administered by an anaesthetist, and many junior anaesthetists are also unfamiliar with the technique. In the absence of such

information and expertise, patients often prefer not to see or feel anything, therefore opting for a general anaesthetic.

The primary aim of this study was to determine whether vascular surgical trainees could learn the ankle block technique, and whether it was safe and effective for analgesia during acute foot surgery in people with diabetes.

Patients and methods

Two trainee surgeons were trained to perform a safe and effective ankle block over the course of a week by an experienced senior anaesthetist. The trainees were trained specifically to use the anatomical landmark technique to perform ankle blocks. However, in the absence of a palpable foot pulse the trainees were well versed in using a hand-held Doppler probe to identify an arterial signal to locate the relevant pedal artery.

The components of the ankle block technique used here were originally described by Kofoed (1982) and have subsequently been referenced in several articles (Needoff et al, 1995; Reilley et al, 2004; Buckenmaier and Bleckner, 2008). An ankle block is essentially a block of five peripheral nerves: two deep nerves (posterior tibial and deep peroneal) and three superficial nerves (saphenous, sural, and superficial peroneal). This concept is important for success of the block because the two deep nerves are anaesthetised by injecting local anaesthetic under the fascia, whereas the three superficial nerves are anaesthetised by a simple subcutaneous injection of local anaesthetic.

In the present study, the ankle block was performed in a standard manner with the patient supine using a 23-gauge hypodermic needle to inject a mixture 20 mL 1% lidocaine with 20 mL 0.5% bupivacaine for rapid onset, durable analgesia (*Figure 1*). The blocks were performed in the anaesthetic room, 20–30 minutes before surgery and the adequacy was tested with a scalpel prior to incision.

Consecutive patients undergoing acute foot debridement or amputation of digits as a result of complications of diabetic foot disease between October 2013 and February 2014 were included. All were approached for consent to undergo ankle block, after discussion of other anaesthetic

options. The absolute contraindications to performing an ankle block were patient refusal and infection at any of the injection sites. Relative contraindications included systemic anticoagulation, bleeding disorders or systemic infection (Chin et al, 2011).

Variables recorded as part of the study included patient age and sex, discomfort during the ankle block, procedure(s) performed, requirement for local anaesthetic ‘top-up’ and post-procedure complications. On discharge, patients were also asked if they would agree to have any future procedures required under regional anaesthesia. The data were subjected to descriptive analysis.

Results

Twenty-five consecutive patients who required emergency or urgent foot surgery had their procedure under ankle block, without sedation or general anaesthesia. This group comprised 23 men and two women, with a mean age of 69 years. All 25 patients had diabetes for which they were taking insulin, oral anti-hyperglycaemic tablets, or both. Other comorbidities included ischaemic heart disease, hypertension, chronic kidney disease (one patient had end-stage renal failure requiring haemodialysis three times a week) and chronic obstructive pulmonary disease.

Table 1 lists the procedures completed under ankle block. No patient required further local

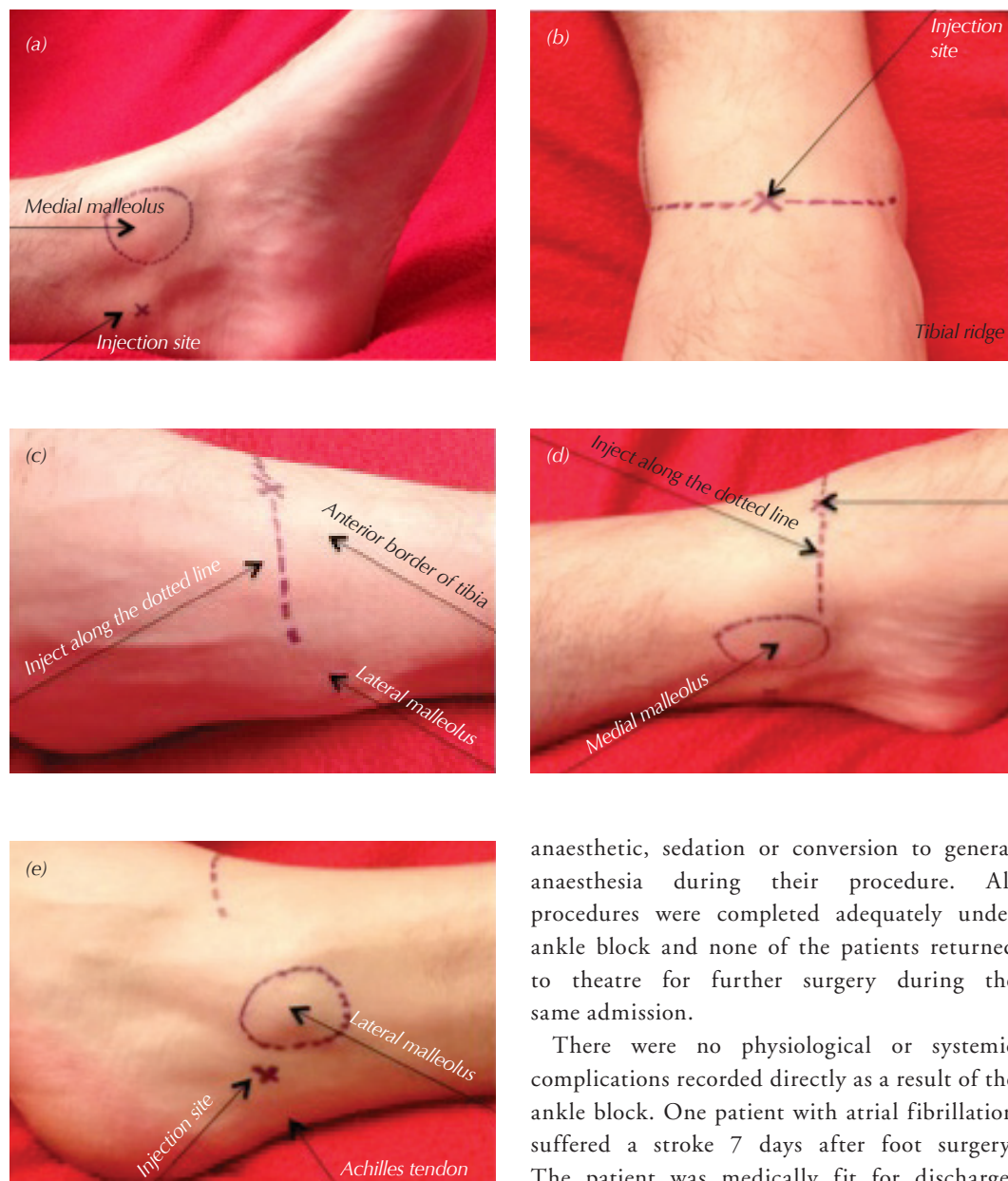
Table 1. Procedures performed under ankle block.

Procedure	Patients (n)
Ray amputation of hallux	4
Ray amputation of other toe	7
Amputation of toe	7
Multiple toes amputated	3
Drainage and/or debridement	3
Multiple procedures	1

Table 2. Patient comfort levels during administration of their ankle block and procedure.

Patients' descriptors (n)	Administration of ankle block (n)	Procedure (n)
Tolerable	15	0
Tolerable with discomfort	7	0
Comfortable	3	25
Intolerable	0	0
Total patients	25	25

Figure 1. Anatomical landmark technique used to deliver ankle block. (a) The tibial nerve is located posterior to the posterior tibial artery at the level of the medial malleolus. Palpate the artery and insert the needle posterior to the artery. The needle will typically contact the medial malleolus; after this contact occurs, slightly withdraw the needle. Inject 5 mL of local anaesthetic. (b) The deep peroneal nerve runs lateral to the dorsalis pedis artery and the tendon of the extensor hallucis longus muscle at the level of the foot. Palpate the artery and insert the needle lateral to the artery. If unable to feel the artery, either use a Doppler to locate it or ask the patient to dorsiflex their toes to accentuate the tendon of extensor hallucis longus and insert the needle lateral to the tendon. If bone is contacted, withdraw the needle slightly before injecting 5 mL of local anaesthetic. (c) For the superficial peroneal nerve, inject a subcutaneous wheal of local anaesthetic (5 mL) from the anterior border of the tibia to the lateral malleolus. (d) For the saphenous nerve, inject a subcutaneous wheal of local anaesthetic, directing it posteriorly from the tibial ridge to the medial malleolus. (e) For the sural nerve, insert the needle between the Achilles tendon and the lateral malleolus, and subcutaneously infiltrate 5 mL of local anaesthetic along this course.



anaesthetic, sedation or conversion to general anaesthesia during their procedure. All procedures were completed adequately under ankle block and none of the patients returned to theatre for further surgery during the same admission.

There were no physiological or systemic complications recorded directly as a result of the ankle block. One patient with atrial fibrillation suffered a stroke 7 days after foot surgery. The patient was medically fit for discharge,

but was awaiting a community bed due to social circumstances. Another patient with poorly controlled diabetes and unstable angina developed flash pulmonary oedema requiring admission under the cardiologists on the day of discharge (day 3, post-procedure).

Patients were asked about comfort levels during administration of ankle block and procedure (Table 2). Overall, the patients gave positive feedback and were all prepared to undergo any future foot surgery under ankle block.

Discussion

This small study suggests that regional anaesthesia using an ankle block is an effective alternative to general anaesthesia for acute diabetic foot surgery. The procedure was not associated with any relevant major side-effects or direct complications, and was effective in providing procedural and postoperative analgesia. The technique was easily learned by two trainees, and could be adopted in any vascular practice. People with diabetes who need acute foot surgery are often low priority on emergency operating lists, and may be on a waiting list for many hours before a slot becomes available.

By contrast to surgery under general or neuroaxial anaesthesia, patients treated under ankle block are not required to be starved preoperatively. This is particularly beneficial for people with diabetes, since fasting invariably makes them feel unwell, and makes good glycaemic control difficult to achieve. Patients treated in the present study were allowed to eat and drink normally preoperatively, and their regular diabetes medication was not altered.

Patients in this study tolerated the procedure well, and were happy to have further surgery, if required, under ankle block. Patients were counselled explicitly during the consent process that the ankle block would eliminate the sensation of pain but that they would still feel the touch, pushing and pulling. The patients

were also given standard advice about the sounds and smells of an operating theatre, and treated in the same way as anyone undergoing a local anaesthetic procedure.

Although not investigated in this article, there could be cost savings for routine use of ankle block for acute surgery. It is advisable to have continued anaesthetic input while the service is started, to enable supplemental sedation or conversion to general anaesthesia. Once expertise is established, routine presence of an anaesthetist may not be necessary, and may allow them to be assessing other patients for the emergency list while the foot surgery proceeds.

Conclusion

The technique of ankle block for foot surgery has obvious clinical advantages. Here, the results of a 25-person series suggest ankle block to be a safe and effective technique for acute diabetic foot surgery. The ankle block technique is simple to learn and could be incorporated into a modern vascular practice. ■

- Boulton A, Vileikyte L, Ragnarson-Tennvall G, Apelqvist J (2005) The global burden of diabetic foot disease. *Lancet* **366**: 1719–24
- Buckenmaier C, Bleckner L (2008) Chapter 22: Ankle block. In: *The Military Advanced Regional Anesthesia and Analgesia Handbook*. The Henry M Jackson Foundation for the Advancement of Military Medicine, Rockville, MD. Available at: <http://bit.ly/20DBwuN> (accessed 02.02.16)
- Chin KJ, Wong NW, Macfarlane AJ, Chan VW (2011) Ultrasound-guided versus anatomic landmark-guided ankle blocks: A 6-year retrospective review. *Reg Anesth Pain Med* **36**: 611–8
- Foote J, Freeman R, Morgan S, Jarvis A (2012) Surgeon administered regional blocks for day case foot surgery. *Foot Ankle Surg* **18**: 141–3
- Kofoed H (1982) Peripheral nerve blocks at the knee and ankle in operations for common foot disorders. *Clin Orthop Relat Res* **168**: 97–101
- Needoff M, Radford P, Costigan P (1995) Local anaesthesia for postoperative pain relief after foot surgery: a prospective clinical trial. *Foot Ankle Surg* **16**: 11–3
- Reilley TE, Terebuh VD, Gerhardt MA (2004) Regional anaesthesia techniques for the lower extremity. *Foot Ankle Clin* **9**: 349–72
- Rudkin GE, Rudkin AK, Dracopoulos GC (2005) Ankle block success rate: a prospective analysis of 1,000 patients. *Canadian J Anaesthesia* **52**: 209–10
- Schurman DJ (1976) Ankle-block anaesthesia for foot surgery. *Anaesthesiology* **44**: 349–52
- Whiting DR, Guariguata L, Weil C, Shaw J (2011) IDF Diabetes Atlas: global estimates of the prevalence of diabetes for 2011 and 2030. *Diabetes Res Clin Pract* **94**: 311–21