

A clinical evaluation of Woulgan® Biogel in the management of non-infected diabetic foot ulcerations

Donna Welch

Despite optimum treatment, some diabetic foot ulcers remain hard to heal. Diabetic foot ulcer progression may be delayed due to altered neutrophil function and dysfunctional macrophages with respect to the production of cytokines and growth factors essential for wound healing. Woulgan Biogel® is a sterile gel consisting of water, glycerol, carboxymethylcellulose and soluble beta-glucan (SBG). SBG stimulates Macrophages and can accelerate healing. Two case studies were completed to evaluate the effectiveness of Woulgan Biogel in managing non-infected chronic diabetic foot ulcers. Both case studies demonstrated positive patient outcomes with the ulcers healing completely. Woulgan Biogel was found to be an effective dressing and appeared to promote healing of previously static diabetic foot ulcers.

Managing diabetic foot ulcerations can be a challenge due to the various complications that can affect the healing process (Basu and Shukla, 2012). Unlike other chronic wounds, diabetic foot ulcer progression may be delayed by altered neutrophil function, diminished tissue perfusion and or defective protein synthesis (Wounds International, 2013). Macrophages play a major role in wound healing, they boost host defences, promote and resolve inflammation, remove dead cells and support cell proliferation and tissue restoration (Koh and Dipietro, 2011). Zykova et al (2000; 2004) suggest that macrophages from diabetic mice and humans are dysfunctional with respect to the production of cytokines and growth factors that are essential for wound healing.

Best practice for the management of diabetic foot ulcers includes: addressing vascular issues, regular debridement and cleansing of wounds, offloading and managing acute infections (White and McIntosh, 2008). In addition, plantar pressures during weight-bearing activity, in conjunction with peripheral neuropathy, may lead to continued trauma and delayed healing in the diabetic foot. A thorough vascular and

neurological assessment, combined with a holistic management plan, is essential when managing diabetic foot ulcers. However, despite optimum treatment, some diabetic foot ulcers remain 'hard to heal' (White and McIntosh, 2008; 2009). Prompt healing of any wound, helps to reduce financial costs but, more importantly, minimises the physical and psychological effect to the individual patient. Clinicians have to consider the most appropriate dressing to optimise wound healing.

Woulgan® Biogel (H&R Healthcare) is a sterile gel consisting of water, glycerol, carboxymethylcellulose and soluble beta-glucan (SBG). SBG is a plant-derived compound that acts on cells to accelerate healing by stimulating macrophages (Engstad et al, 2002). In a randomised, double-blind, placebo-controlled study, Zykova et al (2013) concluded that SBG may accelerate healing in diabetic foot and leg ulcers. The results from the trial showed a tendency to induce a rapid action and promote a shorter healing time in chronic diabetic foot ulcers, compared to standard wound care.

The following two case studies demonstrate the effectiveness of Woulgan Biogel in the treatment of non-infected diabetic foot ulcers.

Citation: Welch D (2017) A clinical evaluation of Woulgan® Biogel in the management of non-infected diabetic foot ulcerations. *The Diabetic Foot Journal* 20(1): 43–7

Article points

1. These case studies evaluate the use of Woulgan Biogel to accelerate healing in chronic diabetic foot ulcers.
2. Despite optimum management, some diabetic foot ulcers remain hard to heal. Prompt healing of wounds reduces financial costs and the physical and psychological impact to the individual patient.
3. Woulgan Biogel produced positive outcomes. It was easy to apply, reduced pain and in both case studies, the wounds completely healed.

Key words

- Macrophages
- Soluble beta-glucan
- Woulgan Biogel

Author

Donna Welch is Advanced Podiatrist Diabetes, Humber NHS Foundation Trust, Hull

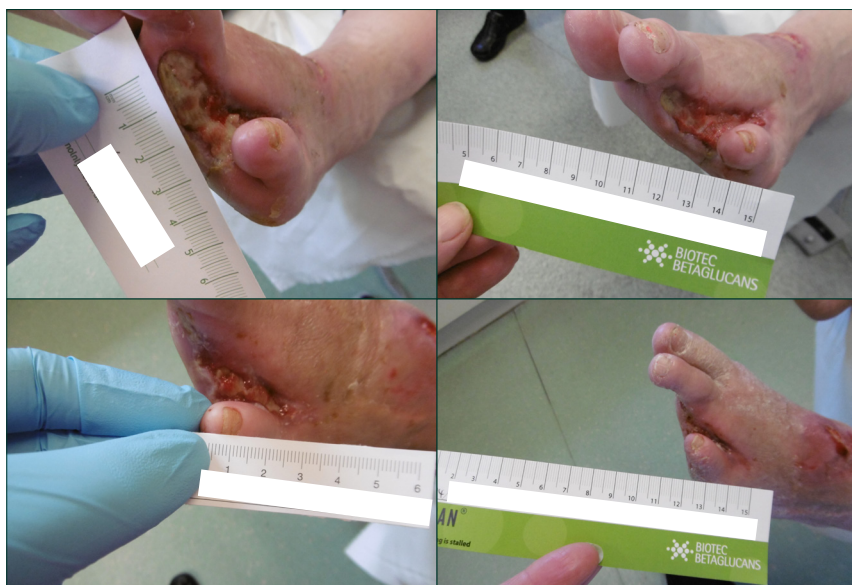

Figure 1. (a) Initial presentation of amputation site. (b) Wound at week 2. (c) Wound at week 4. (d) Wound at week 10.

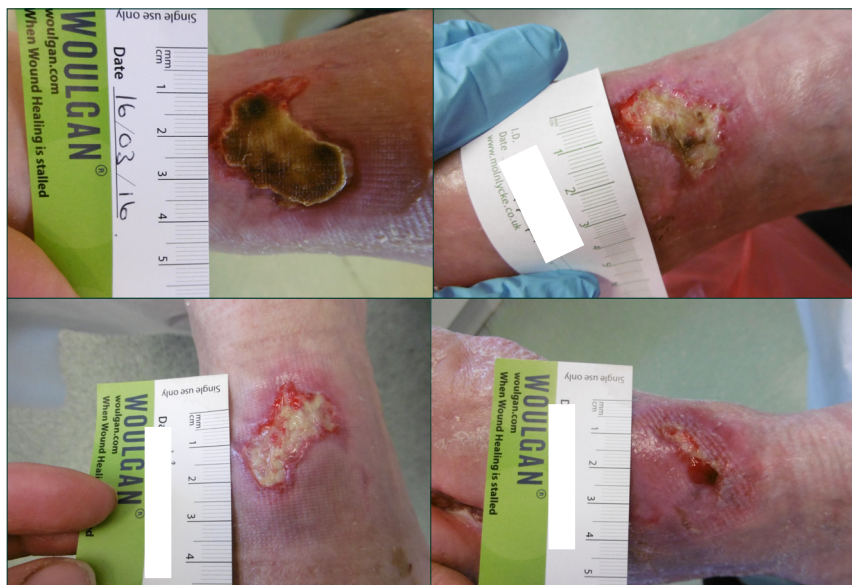


Figure 2. (a) Wound on presentation. (b) Wound at week 2. (c) Wound at week 4. (d) Wound at week 10.

Methods

Patients were selected to the evaluation meeting the following criteria:

- Wound measurements of between 1–30cm²
- Patients with a wound of least 4 weeks duration, which appeared to be static
- Wound exudate levels assessed as low to moderate
- Wound clinically assessed as being free from

classical signs of infection

- Patients presenting with a HbA_{1c} <86 mmol/mol.

Patients must have capacity, be able to give informed consent and be monitored throughout the evaluation period.

Patients consented to the use of Woulgan Biogel as a primary dressing. All secondary dressings were consistent with previous treatments and included; atrauman and secondary foam. Dressings were changed according to clinical need on average 2–3 times weekly. Appropriate sharp debridement and offloading was maintained throughout the evaluation period. Digital images were taken on a weekly or fortnightly basis. Data collected included: wound dimension, wound bed presentation, exudate levels and patient pain analogue score. The ease of application and response to treatment was also documented.

Case study 1

Background

A female patient aged 54 years and not previously known to podiatry, was admitted to hospital with critical limb ischemia. Hospital treatment included a left leg bypass graft and amputation of the left 3–4 necrotic toes. The patient was diagnosed with type 2 diabetes on admission, with a HbA_{1c} of 64 mmol/mol. The patient was reviewed by the podiatry team on the ward and then in the diabetic foot clinic following discharge.

The patient was considered appropriate for the Woulgan Biogel evaluation, 4 weeks post-surgery. At this time, the left foot dorsal ulceration measured 20 mm x 25 mm with adherent slough and necrosis to base and minimal granulation tissue to margins. The patient reported a pain scale of 3 and was unable to look at her foot. She was struggling to come to terms with the surgery and diagnosis.

After 2 weeks of Woulgan Biogel application, the dorsal wound had improved with reduced slough and necrosis. Pain scale was now recorded as 0 and the patient was very satisfied with the results. At week 2, the patient requested Woulgan Biogel be used on

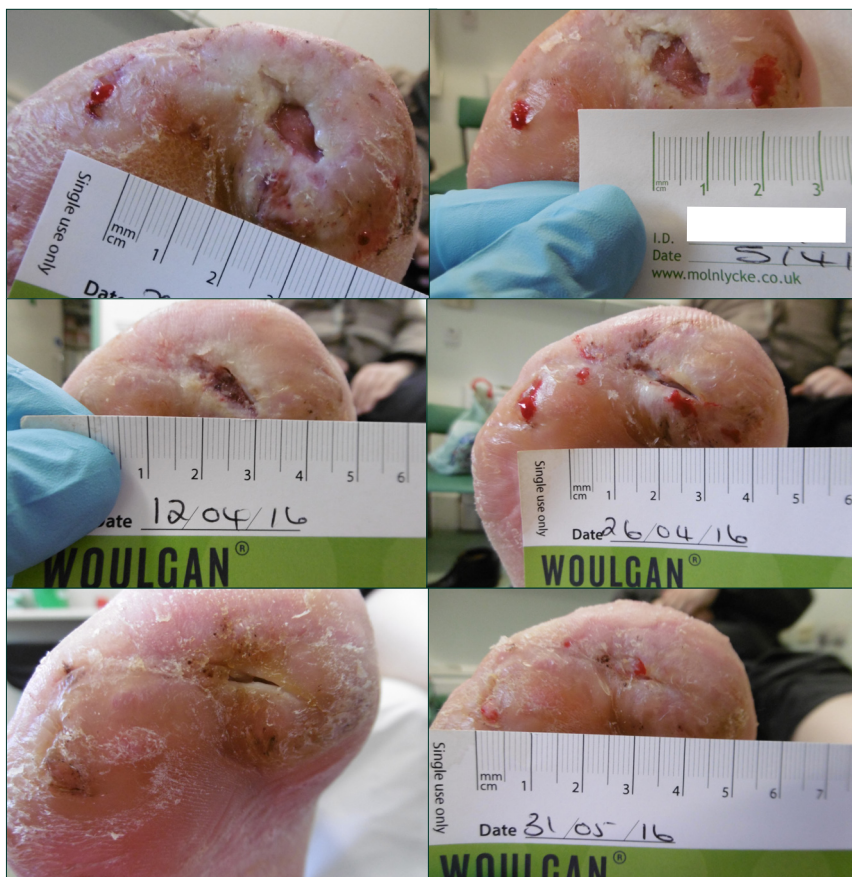

Figure 2. (a) Wound on initial presentation. (b) Wound at week 1. (c) Wound at week 2. (d) Wound at week 4. (e) Wound at week 7. (f) Wound at week 9.

her amputation site also, as the current alginate dressing was adhering and causing discomfort. The amputation site was assessed at this stage as being suitable for use of Woulgan Biogel as the exudate levels had reduced and were now considered moderate. Figure 1 details the wound healing process.

Case study 2

Background

A 49-year-old male with type 2 Diabetes diagnosed 6 years ago, with a HbA1c 67 mmol/mol. The patient had previously developed foot infection as a result of undiagnosed diabetes and had a right forefoot amputation 6 years previous, which had never completely healed. Previous management had included, optimum wound care, appropriate debridement, various dressing types including antimicrobials. The patient had previously been offloaded with a total contact cast and had subsequently been supplied bespoke footwear and forefoot filler by the orthotist. All alternative offloading options

had been exhausted and the patient was keen to remain in footwear as heavy casted devices were starting to give him hip pain. The patient had suffered repeated episodes of infection requiring antibiotic treatment and occasional admission to hospital. The patient attended the diabetic foot clinic every 1–2 weeks with additional weekly wound clinic appointments with community nurses for dressings.

The forefoot wound was assessed as appropriate for use of Woulgan gel measuring 5 mm x 10 mm with low exudate levels, no pain and no signs of infection. Both the patient and the advanced podiatrist considered the use of Woulgan Biogel was unlikely to make any difference to this chronic hard-to-heal wound. In fact, it would be reasonable to assert that Woulgan Biogel was used as a last resort with nothing to lose. This chronic hard-to-heal ulcer was considered a challenge to test the effectiveness of the product.

At week 1, the patient presented with minimal change to wound bed presentation, but surrounding tissue and wound margins looking healthier. The ulcer continued to progress until completely healed at week 9.

Furthermore, the foot has remained intact, not requiring any dressings for months following the Woulgan evaluation. The patient was very impressed with the outcome of the evaluation and the dressing regimen. He had been attending frequent dressing and podiatry appointments for the previous 6 years. He was pleased to be discharged to community podiatry for ongoing care and monitoring.

Results

The two case studies outlined in this article demonstrate completely different wound types and aetiology, however, both diabetic foot ulcerations healed and, more importantly, have remained intact to this date. Comfort on application and removal of dressing was reported as excellent and the pain levels were reduced in case study 1. No adverse reactions were reported by either patient. The Woulgan Biogel was reported as very easy to apply by all healthcare professionals involved in the care of these two patients.

Conclusion

Woulgan Biogel was found to be an appropriate dressing in the management of hard-to-heal, non-infected diabetic foot ulcers with low to moderate exudate levels. It appeared to promote healing in wounds that were previously static. It offers an alternative, safe, treatment option to clinicians, when all other contributing factors, such as infection, revascularisation and offloading, have been suitably addressed. The dressing produced positive patient outcomes. ■

Basu S, Shukla V (2012) Complications of Wound Healing. In: Mani R, Romanelli M, Shukla V (eds.) *Measurements in Wound Healing*. Springer, London 109–44

Engstad CS, Engstad RE, Olsen JO et al (2002) The effect of soluble beta-1,3-glucan and lipopolysaccharide on cytokine production and coagulation activation in whole

- blood. *Int Immunopharmacol* 2(11): 1585–97
- International Best Practice (2013) Wound Management in Diabetic Foot Ulcers. Wounds International, London. Available at: <http://bit.ly/2fV6oGT> (accessed 07.03.2017)
- Koh TJ, Dipietro LA (2011) Inflammation and wound healing: the role of the macrophage. *Expert Rev Mol Med* 13: e23
- White R, McIntosh C (2008) Topical therapies for diabetic foot ulcers; standard treatments. *J Wound Care* 17(10): 426,428–32
- White R, McIntosh C (2009) A Review of the literature on topical therapies for diabetic foot ulcers. Part 2: Advanced therapies. *J Wound Care* 18(8): 335–41
- Zykova SN, Jenssen TG, Berdal M et al (2000) Altered cytokine and nitric oxide secretion in vitro by macrophages from diabetic type2 – like db/db mice. *Diabetes* 49(9): 1451–8
- Zykova SN, Svartberg J, Seljelid R et al (2004) Release of TNF – alpha from in vitro-stimulated monocytes is negatively associated with serum levels of apolipoprotein B in patients with type 2 diabetes. *Scand J Immunol* 60(5): 535–42
- Zykova SN, Balandina KA, Vorokhobina NV et al (2013) Macrophage stimulating agent soluble yeast B-1,3/1,6-glucan as a topical treatment of diabetic foot and leg ulcers: A randomized double blind, placebo-controlled phase II study. *J Diabetes Investigation* 5(4): 392–9