

Appropriate use of larval debridement therapy in diabetic foot management: consensus recommendations

Paul Chadwick, Joanne McCardle, Elaine Ricci, Duncan Stang, Stella Vig

Recent evidence shows that larval debridement therapy (LDT) is a cost-effective, highly selective method of rapidly debriding diabetic foot ulcers (DFUs). Despite this, it is largely considered an adjunctive treatment or debridement method of last resort. A working group of key opinion leaders in diabetic foot care proposes that LDT should be considered alongside other debridement methods for DFUs and, when appropriate, be initiated early in the wound management process as part of an integrated care plan. The group's consensus recommendations for appropriate selection and use of LDT in this context are presented here.

Larval debridement therapy (LDT) is an established method of rapidly and effectively debriding and treating diabetic foot ulcers (DFUs; Sherman, 2014). It is suitable for a wide range of patients, including those considered too fragile for surgery (Gottrup and Jorgensen, 2011; Gilead et al, 2012). Studies show that LDT is associated with faster healing rates (Sherman, 2003; Armstrong et al, 2005; Tian et al, 2013), reduced amputation rates (Armstrong et al, 2005; Paul et al, 2009; Gottrup and Jorgensen, 2011) and reduced need for antibiotics (Armstrong et al, 2005; Paul et al, 2009), compared with other conventional debridement methods in patients with DFUs.

Despite the evidence, LDT is largely considered an adjunct to other debridement options, an interim measure by practitioners without training in sharp debridement or a last resort in non-healing wounds resistant to other debridement methods (Evans, 1997).

Authors

Paul Chadwick, Consultant Podiatrist, Salford Royal Foundation Trust

Joanne McCardle, Diabetes Foot Podiatry Research Fellow, NHS Lothian University Hospital Division
Elaine Ricci, Principal Podiatrist, Diabetes and Wound Care, City Hospitals Sunderland

Duncan Stang, Chief Podiatrist, Hairmyres Hospital, East Kilbride; National Diabetes Foot Coordinator for Scotland

Stella Vig, Consultant Vascular and General Surgeon, Croydon University Hospital

LDT targets devitalised tissue and may salvage healthy adjacent tissue. It may therefore be used in preference to sharp debridement in selected patients.

In November 2014, a working group of key opinion leaders in diabetic foot care met at the *Wounds UK* conference in Harrogate to discuss the consideration of LDT as a first-line debridement option, alongside other debridement methods, to be initiated early in the wound management process. This paper presents the group's consensus recommendations for the appropriate selection and use of LDT in DFUs.

What is LDT?

LDT uses larvae of the greenbottle blowfly (*Lucilia sericata*) to remove dead tissue, cellular debris and exudate present in moist, sloughy wounds (Gottrup and Jorgensen, 2011). The larvae break down this material by physical actions and by excreting proteolytic digestive enzymes. They ingest the resulting liquified substrate, including any bacteria it contains. The larvae may be applied in bagged (*Figure 1a*) or free-range form (*Figure 1b*), depending on wound characteristics and patient preference (All Wales Tissue Viability Nurse Forum [AWTVNF], 2013).

Indications for use

In a wound that requires rapid debridement

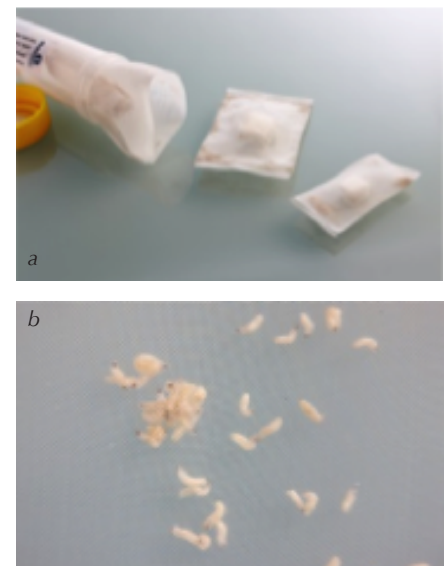


Figure 1a. BioBag larvae. Figure 1b. Free-range larvae.

of devitalised tissue that is delaying wound healing, consideration should be given to using LDT first-line, either as a stand-alone option or alongside other debridement methods (i.e. sharp, surgical, mechanical, hydrosurgical and ultrasonic). When deciding whether LDT is appropriate, practitioners should take into account wound factors and then patient factors (*Tables 1 and 2*), along with cost considerations.

The decision to use LDT should be independent of wound site or depth. The

Table 1. When to consider larval debridement therapy (LDT)*.	
Wound factors	Patient factors
<ul style="list-style-type: none"> • Moist, sloughy/necrotic wounds Including wounds that have re-sloughed after surgical debridement • Wounds with sloughy/necrotic tissue underlying thick eschar After first removing the hard ‘cap’ with another intervention (e.g. sharp debridement, hydrogel) • Wounds that are not on a satisfactory healing trajectory with other debridement measures • Infected wounds LDT is effective for managing wounds containing bacteria, including meticillin-resistant <i>Staphylococcus aureus</i> and beta haemolytic <i>streptococcus</i> that are difficult to kill with more conventional treatments (Bexfield et al, 2010). The larvae ingest and digest any bacteria present, reducing the bioburden within the wound. Oral antibiotic therapy may also be needed in these wounds 	<ul style="list-style-type: none"> • Patients not suitable for surgical debridement In patients medically unfit for surgery (e.g. older, bedbound or infirm patients), LDT offers a safe and effective alternative to surgical debridement (Paul et al, 2009) • Patients with pain (where surgical or sharp debridement is not acceptable)** Some patients have found that pain associated with infected wounds is reduced with LDT (All Wales Tissue Viability Nurse Forum [AWTVNF], 2013) • Patients with peripheral arterial disease where other debridement methods are excluded • Patients at the end of life Where surgical aggressive interventions are not indicated, larvae may improve quality of life by reducing bacterial burden and odour • Patients who have expressed a preference for LDT and it is clinically indicated
<p>*In all these situations it is important that the patient understands and accepts what LDT involves and is considered likely to be adherent. Informed verbal consent should be obtained and documented before proceeding with LDT (or local guidance followed where there is insufficient mental capacity) **Some patients, particularly those with a poor arterial blood supply, report an increase in pain during LDT. Treatment is still possible using appropriate analgesia as part of a pain management plan (AWTVNF, 2013)</p>	

Table 2. When not to consider larval debridement therapy (LDT).	
Wound factors	Patient factors
<ul style="list-style-type: none"> • Clean, granulating wounds • Wounds with dry, hard eschar/callus prior to removal of eschar or softening with hydrogel Consider LDT for any underlying moist, necrotic tissue • Wounds in close proximity to a large blood vessel 	<ul style="list-style-type: none"> • Patients suitable for surgery Surgical debridement can be carried out simultaneously with revascularisation or amputation • Patients poorly controlled on anticoagulants* Larval therapy may increase the risk of bleeding • Patients with insufficient home support Risk of occlusion if patients are not able to offload a plantar wound or use a walking aid • Patients at risk of falls This is due to the need for offloading and does not prevent use in patients in hospital • When LDT is not acceptable to patients Practitioners should explain clearly what LDT entails along with the risks and benefits • Patients with insufficient level of understanding or mental capacity Unless appropriate consent given by guardian/carer
<p>*LDT is not contraindicated if anticoagulation is well controlled and clotting markers are within an acceptable therapeutic range</p>	

larvae can tolerate direct pressure from a plantar wound if care is taken when packing the dressing and the wound is mostly offloaded. They can also withstand some submersion and may, therefore, be used on highly exuding wounds if measures are taken to avoid an occlusive environment, as they cannot survive lack of oxygen, such as frequent dressing changes and non-occlusive outer dressings.

Competencies for using LDT

Approval to administer LDT should be given by an appropriate advanced practitioner in consultation with the multidisciplinary team/foot protection service, according to local policy. However, subsequent application and management of LDT may be carried out by any qualified practitioner who has reached an appropriate level of competency through training and who has adequate clinical support. To ensure cost-effective use of LDT, these principles should be incorporated into your local diabetic foot protocol.

Every healthcare professional is responsible for maintaining his/her competence. One useful training tool is the BioMonde online academy (Box 1). A competency framework for debridement, outlining the skills and knowledge necessary to care for patients with DFUs, is given in Table 3.

Achieving optimal outcomes

As with other methods of debridement, LDT should be used as part of an integrated care plan involving effective pressure relief, infection control, revascularisation, glycaemic control and patient education (Waniczek et al, 2013).

The rationale for using LDT should be documented in the patient’s record and

Box 1: Online training tool for LDT.

- The Larval Academy is a free online accredited course, tailored specifically for healthcare professionals
- Provides information on how larval therapy works to debride wounds, how larvae can support wound management and how to apply larvae to a wound
- Register at: www.larvalacademy.com

Table 3. Competency framework for debridement (reproduced from FDUK, 2014 and adapted from TRIEPodD-UK, 2012).

Level F: Consultant level podiatrist or practitioner	<ul style="list-style-type: none"> • Provides clinical leadership in advanced wound debridement techniques • Leads in the establishment of working relationships with surgical staff responsible for surgical debridement • Provides expert opinion on debridement products, techniques and indications in local and national expert groups • Leads in the evaluation of novel wound care products
Level E: Advanced practitioner	<ul style="list-style-type: none"> • Able to carry out advanced debridement (with a range of debridement tools) of complex wounds within their scope of practice • Able to carry out advanced wound management techniques (e.g. negative pressure wound therapy) • Able to make complex decisions regarding choice of appropriate debridement method while considering individual patient circumstances • Recognises the need and refers the patient for surgical debridement appropriately • Supports less experienced colleagues in developing advanced debridement skills
Level D: Specialist practitioner	<ul style="list-style-type: none"> • Able to carry out general debridement of simple and complex wounds within their scope of practice • A broad knowledge of and experience in using debridement techniques other than sharp debridement (e.g. mechanical, larvae, hydrosurgical) • Appropriately recognises the need and refers the patient for advanced debridement • Critically analyses wound care interventions to develop evidence-based, individualised care plans • Carries out advanced wound management techniques with appropriate support and supervision
Level C: General/newly qualified practitioner	<ul style="list-style-type: none"> • Understands the principles of debridement in preventing foot complications (e.g. removal of callus to reduce plantar pressures and reduce likelihood of tissue damage) • Understands the principles of debridement and the association with wound management • Able to carry out sharp debridement in the intact foot • Able to carry out wound management techniques (e.g. general sharp/mechanical debridement, wound irrigation) in simple wounds, not complicated by systemic disease • Recognises the need and refers the patient for advanced wound management and multidisciplinary care (of any non-healing or complex wound) in line with national guidance

evaluated at each dressing change as part of an overall management plan.

Assessment

Before starting LDT, a holistic assessment should be undertaken by a qualified practitioner within the multidisciplinary foot clinic according to local policy and should include (AWTVNF, 2013):

- A full assessment of the patient, wound type and wound bed. This should be undertaken and the results documented prior to LDT, taking into account:
 - Ability to offload pressure
 - Results of vascular studies
- Patient consent
 - Provide simple, clearly written information about the nature, risks and benefits of treatment
 - Informed verbal consent should be obtained and documented where appropriate

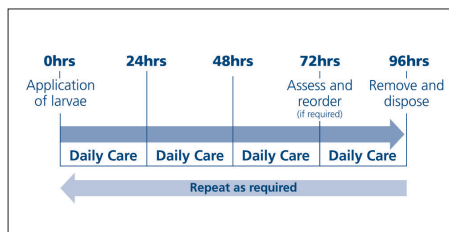


Figure 2. Recommended application cycle for bagged and free range larvae.

- If this is not possible (e.g. due to lack of capacity), practitioners should follow local guidance
- Information on LDT for patients and carers.

Wounds treated with LDT have a distinctive odour and this should be discussed with patients before the start of treatment to improve adherence.

Applying LDT

The aim of debridement is to achieve a clean, granulating wound bed. More

than one consecutive application may be necessary to attain this goal. The process described below should be carried out with the support of an appropriate advanced practitioner in the context of the multidisciplinary team to ensure all aspects of care are being addressed.

Each application of larvae (whether bagged or free-range) can be left in place for up to four days before removal. Outer dressings should be checked or changed daily (viable larvae are indicated by movement and the presence of a dark red exudate). At day three, the wound should be reviewed and the expected healing trajectory assessed. If a further application is needed, reordering the larvae at this point will allow treatment to continue without a break (Figure 2).

The consensus group agreed that if LDT is applied correctly, most wounds are effectively debrided after two or three

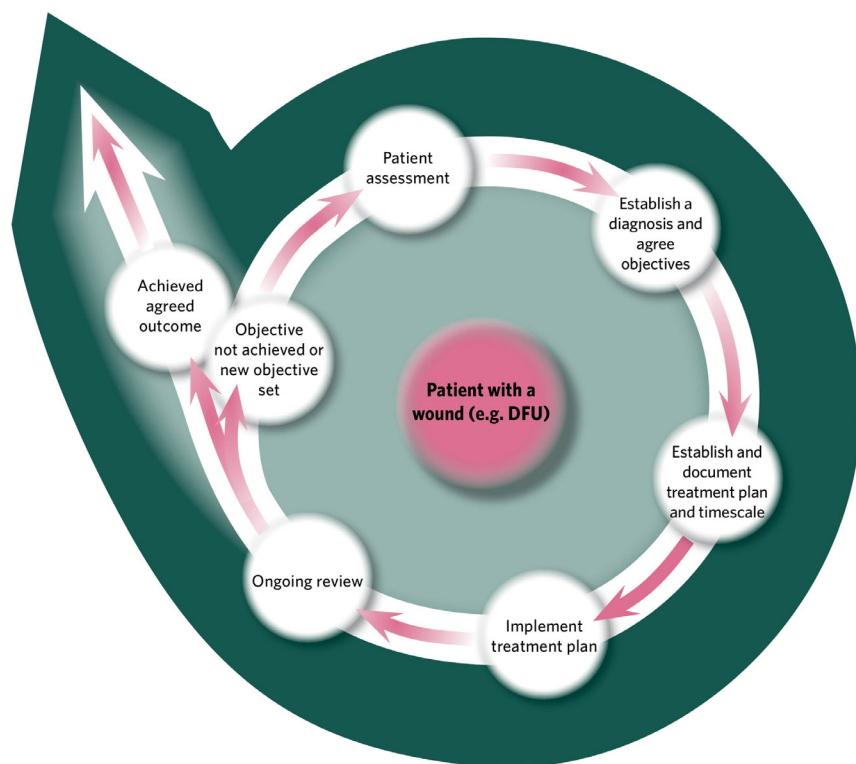


Figure 3. A debridement pathway underlining the importance of assessment, documentation, ongoing evaluation and reassessment (reproduced from Ricci and Chadwick, 2014 and adapted from Gray et al, 2011).

applications. If more than three applications are judged necessary, practitioners should consider whether other factors (e.g. infection) are affecting healing, whether LDT is being applied correctly and whether another debridement method is needed.

LDT should be stopped once the wound bed appears clean and granulating. If the wound re-sloughs, a thorough review of the patient and wound should establish why this has occurred. Offloading and diabetes control should be optimised. Further applications of LDT can be considered using the principles described above.

It is important to note that once the slough and non-viable tissue is removed, the volume of the wound often increases. This is normal and not a cause for concern. The

exudate during LDT will be a red/brown colour due to breakdown of tissue and this should not be confused with bleeding.

Antibiotics and antimicrobials

It is not necessary to stop systemic antibiotics before LDT. However, topical disinfectants, local anaesthetics and some hydrogels (i.e. those containing propylene glycol as a humectant and preservative) may have a negative effect on the growth and vitality of the larvae (AWTVNF, 2013). The wound should therefore be cleaned prior to LDT to remove any remnants that may remain.

Adjunctive therapies

For most patients, optimal outcomes will

“It is vital to maintain the healing momentum after debridement by continuing to follow the principles of wound bed preparation and good moist wound healing.”

be seen if LDT is combined with sharp or surgical debridement to debulk the wound and remove any callus border. This will give the larvae better access. LDT can, however, be applied directly to the wound if sharp debridement is not appropriate (e.g. patients with pain and those unfit for surgery). Where sharp debridement alone is selected as the first-line measure, consider LDT subsequently if a level of slough remains that would delay wound healing.

Other benefits of LDT

As well as providing a rapid and effective method of debridement, evidence is emerging that LDT is associated with secondary wound healing benefits (Box 2). These include:

- Possible antimicrobial effects (through ingestion of bacteria and excretion of antimicrobial substances; Andersen et al, 2010; Nigam, 2013; Cerovsky and Bem, 2014)
- Reduction in resistance to antimicrobials (Bexfield et al, 2010)
- Enhancement of treatment with systemic antibiotics (van der Plas et al, 2010)
- Possible promotion of tissue regeneration and restoration of normal wound healing processes (via excretion of active chemicals; Nigam, 2013)
- Possible role in biofilm disruption and formation (Nigam, 2013)
- Possible analgesic properties (AWTVNF, 2013).

Wound management following LDT

Effective debridement with LDT is not an endpoint, but part of the continuum of treatment. It is vital to maintain the healing momentum after debridement by continuing to follow the principles of wound bed preparation and good moist wound healing. LDT may be used in conjunction with interventions such as prior to negative pressure wound therapy. It is important that any decision about a wound involves a process of objective setting, assessment,

Box 2: Summary of potential benefits of larval therapy in diabetic foot ulcers (Wounds UK, 2013).

- Established method of debridement (Sherman, 2014)
- Secondary benefits may help to promote wound healing (Pritchard and Nigam, 2013)
- May improve healing rates, reduce amputation rates and antibiotic use (Tian et al, 2013)
- 50% reduction in wound area compared with hydrogel (Edwards and Stapley, 2010)
- May reduce short-term morbidity (Armstrong et al, 2005)
- Safe and effective alternative to surgical debridement in high-risk patients (Paul et al, 2009)
- More selective than surgical debridement (Gottrup and Jorgensen, 2011)
- Can be used in preparation for negative pressure wound therapy (Brin et al, 2007)
- May decrease overall treatment costs (Bennett et al, 2013)

documentation, evaluation and review (Figures 3 and 4).

Cost-effectiveness

The factors that impact on the cost of the different debridement methods are not confined to the cost of the materials alone, but include (AWTVNF, 2013):

- Unit cost of treatment
- Length of treatment
- Number of procedures required
- Cost and likelihood of infection
- Cost and likelihood of adverse events.

An evaluation carried out at the Swansea Centre for Health Economics at the University of Swansea across a range of wound types found that LDT is cost-effective when compared with other debridement methods including surgical, sharp, mechanical and autolytic interventions (Bennett et al, 2013).

Conclusion

LDT is a cost-effective, highly selective method of rapidly debriding a wide range of DFUs. As such, it may be considered as a first-line debridement option and, when appropriate, initiated early in the wound management process to achieve optimal results. Selection, application and ongoing

management of LDT should be carried out in the context of the multidisciplinary team/foot protection service, with initial approval to administer given by an appropriate advanced practitioner according to local policy.

New evidence is emerging that LDT has secondary antimicrobial effects. If borne out in further studies, LDT may have a future role as part of an antimicrobial strategy to reduce reliance on antibiotics. ■

“New evidence is emerging that LDT has secondary antimicrobial effects. If borne out in further studies, LDT may have a future role as part of an antimicrobial strategy to reduce reliance on antibiotics.”

All Wales Tissue Viability Nurse Forum (2013) *All Wales guidance for the use of larval debridement therapy*. Wounds UK, London

Andersen AS, Sandvang D, Schnorr KM et al (2010) A novel approach to the antimicrobial activity of maggot debridement therapy. *J Antimicrob Chemother* **65**: 1646–54

Armstrong DG, Salas P, Short B et al (2005) Maggot therapy in “lower extremity hospice” wound care: fewer amputations and more antibiotic-free days. *J Am Podiatr Med Assoc* **95**: 254–7

Bennett H, Sewell B, Anderson P et al (2013) Cost-effectiveness of interventions for chronic wound debridement: an evaluation in search of data. *Wounds UK* **9**: 3–11

Bexfield A, Gennard DE, Dixon RA (2010) An assessment of the antibacterial activity in larval excretion/secretion of four species of insects recorded in association with corpses, including *Lucilia sericata* Meigen as the marker species. *Bull Entomol Res* **22**: 1–6

Brin YS, Mumcuoglu KY, Massarwe S et al (2007) Chronic foot ulcer management using maggot debridement and topical negative pressure therapy. *J Wound Care* **16**: 111–3

Buchman J, Blair JE (1932) Maggots and their use in the treatment of chronic osteomyelitis. *Surg Gynecol Obstet* **55**: 177–90

Cerovsky V, Bem R (2014) Lucifensins, the insect defensins of biomedical importance: The story behind maggot therapy. *Pharmaceuticals* (Basel) **7**: 251–64

Edwards J, Stapley S (2010) Debridement of diabetic foot ulcers. *Cochrane Database Syst Rev* **20**: CD003556

Evans H (1997) A treatment of last resort. *Nurs Times* **93**: 62–5

Foot in Diabetes UK in association with the College of Podiatry (2014) *Principles of Debridement: The Diabetic Foot*. SB Communications. Available from: <http://bit.ly/106A3Th> (accessed 23.02.2015)

Gilead L, Mumcuoglu KY, Ingher A (2012) The use of maggot debridement therapy in the treatment of chronic wounds in hospitalised and ambulatory patients. *J Wound Care* **21**: 78, 80, 82–5

Gottrup F, Jorgensen B (2011) Maggot debridement: an alternative method for debridement. *Eplast* **11**: e33

Gray D, Acton C, Chadwick P et al (2011) Consensus guidance for the use of debridement techniques in the UK. *Wounds UK* **7**: 77–84

National Institute of Health and Care Excellence (2011) *Diabetic Foot Problems: Inpatient Management. Clinical Guideline CG119*. Available at: <http://guidance.nice.org.uk/CG119> (accessed 23.02.2015)

Nigam Y (2013) Evidence for larval debridement therapy in wound cleansing and healing. *Wounds UK* **9**: 12–6

Paul AG, Ahmad NW, Lee HL et al (2009) Maggot debridement therapy with *Lucilia cuprina*: a comparison with conventional debridement in diabetic foot ulcers. *Int Wound J* **6**: 39–46

Pritchard DI, Nigam Y (2013) Maximising the secondary beneficial effects of larval debridement therapy. *J Wound Care* **22**: 610–6

Ricci E, Chadwick P (2014) The use of larval debridement therapy in diabetic foot ulcer management. In: Stang D, O'Brien J, Ricci E, Chadwick P. *Larval debridement therapy: diabetic foot ulcer management*. Wounds UK, London

Sherman RA. (2003) Maggot therapy for treating diabetic foot ulcers unresponsive to conventional therapy. *Diabetes Care* **26**: 446–51

Sherman RA. (2014) Mechanisms of maggot induced wound healing: What do we know, and where do we go from here? *Evid Based Complement Alternat Med* **592419**. Available at: <http://bit.ly/1Ly9eud> (accessed 23.02.2015)

Tian X, Liang XM, Song GM et al (2013) Maggot debridement therapy for the treatment of diabetic foot ulcers: a meta-analysis. *J Wound Care* **22**: 462–9

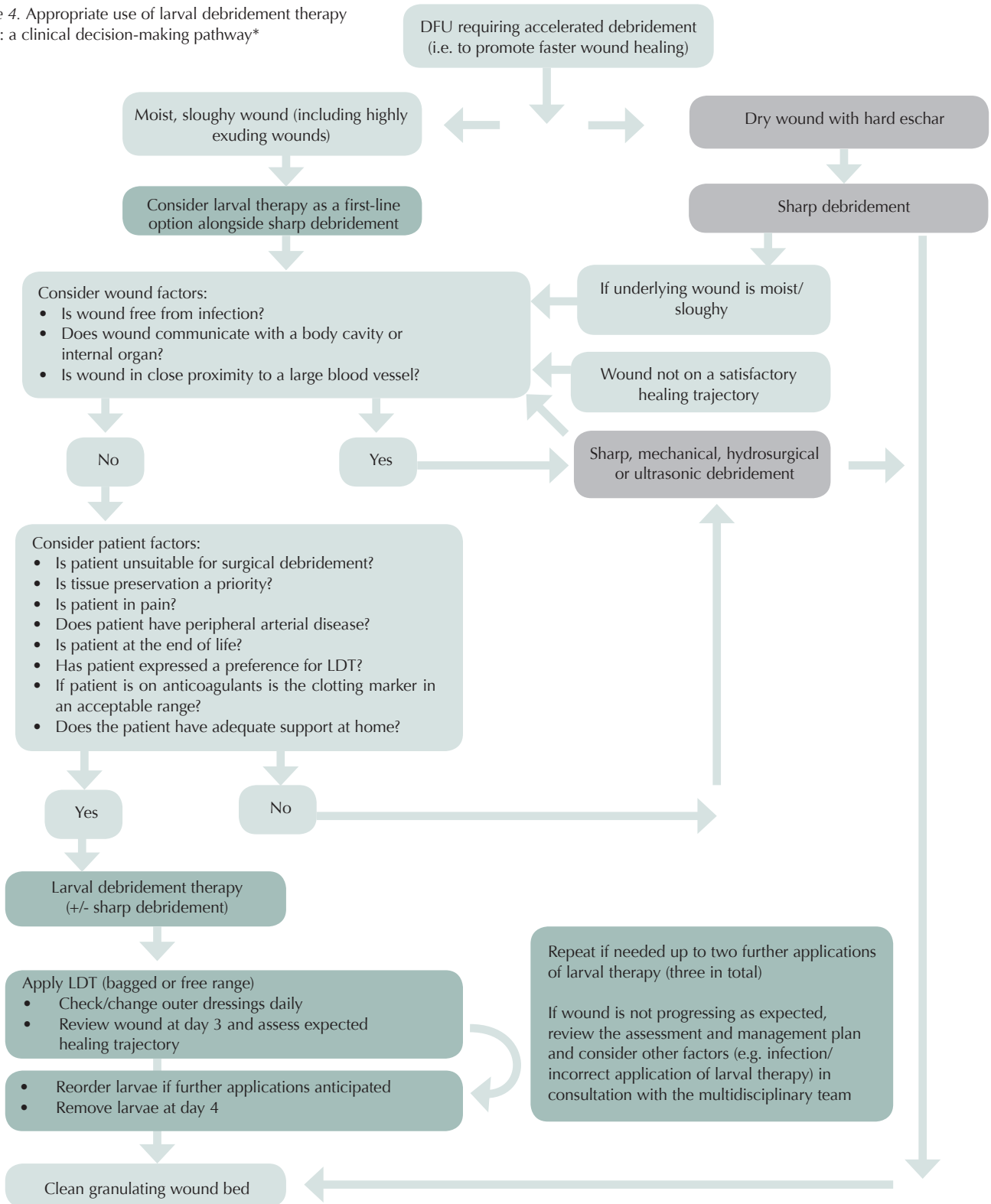
TRIEPoD-UK (2012) Podiatry competency framework for integrated diabetic foot care – a user's guide. TRIEPoD-UK, London

van der Plas MJ, Dambrot C, Dogterom-Ballering HC et al (2010) Combinations of maggot excretions/secretions and antibiotics are effective against *Staphylococcus aureus* biofilms and the bacteria derived therefrom. *J Antimicrob Chemother* **65**: 917–23

Waniczek D, Kozowicz A, Muc-Wierzgon M et al (2013) Adjunct methods of the standard diabetic foot ulceration therapy. *Evid Based Complement Alternat Med* **243568** [Epub June 2013]

Wounds UK (2013) Evidence-based Practice. Larval Debridement Therapy. An Economic, Scientific and Clinical Evaluation. *Wounds UK*. Available at: <http://bit.ly/1BqKsl> (accessed 23.02.2015)

Figure 4. Appropriate use of larval debridement therapy (LDT): a clinical decision-making pathway*



*The decision and approval to administer LDT should be taken by an appropriate advanced practitioner in consultation with the multidisciplinary team/foot protection service, according to local policy. However, subsequent application and management of LDT may be carried out by any qualified practitioner who has reached an appropriate level of competency through training and who has adequate clinical support.