

Advancing the gold standard in offloading the diabetic foot

Emily Sambrook, Tom Delpierre, Graham Bowen

Providing gold standard diabetic foot care is vital in order to reduce rising NHS costs of ulceration and amputation (Kerr, 2012). Offloading is key to preventing and healing plantar neuropathic foot ulcers in patients with diabetes. Total contact casting (TCC) is recommended as a first-line option for offloading; however, TCC is widely under-utilised and has poor patient adherence rates (Fife et al, 2010). TCC-EZ[®] is a casting device that can help to offset some of the challenges of TCC, as it is simpler to apply and found to be more comfortable than traditional TCC. This article will provide practical guidance and case studies to illustrate how TCC-EZ[®] can be incorporated into gold standard diabetic foot care. As TCC is the gold standard, all suitable patients with diabetes should be assessed for the use of TCC-EZ[®] and, if appropriate, this should be provided.

The prevalence of diabetes continues to rise in the UK. In 2013, the Quality Outcomes Framework (QOF) reported a diabetes prevalence of 6% in England and the known diagnosed population is now 3.2 million people in the UK. By 2025, it is estimated that at least five million people in the UK will have diabetes (QOF, 2013).

Foot complications remain one of the main health issues, with approximately 61,000 people with diabetes thought to have a foot ulcer at any given time (Kerr, 2012). Repetitive mechanical trauma is a key factor in the origin of neuropathic foot ulcers (Raspovic and Landorf, 2014). Although it is not possible to completely remove the effects of neuropathy, treatment and prevention relies on redistribution of pressure. Inadequate care of the diabetic foot may lead to amputation, with diabetes the most common cause of lower limb amputation in the UK (McInnes, 2012).

Around 6,000 people with diabetes have a leg, foot or toe amputated each year; this equates to over 100 amputations per week (Kerr,

2012). It is estimated that between £600–£700 million is spent each year on foot ulcers and amputations (Diabetes UK, 2012). Ulceration and amputation substantially reduce quality of life, and are associated with high mortality. Only around 56% of people with diabetes who have had an ulcer survive for five years (Kerr, 2012), while only 48% of patients with diabetes who have had an amputation survive for five years post amputation (Robbins et al, 2008; Wounds International, 2013).

Improving diabetic foot care

To address this growing problem, it is vital that UK clinical commissioning groups (CCGs) look at how they can improve foot care for people with diabetes and take urgent action to reduce preventable amputations. Treatment of diabetic foot ulcers aims to achieve wound closure as quickly as possible — the longer a diabetic foot ulcer (DFU) remains unhealed, the greater the risk of infection, hospitalisation and limb amputation (Edmonds, 2006).

Targeted prevention and rapid access to multidisciplinary footcare teams (MDFT) can lead to faster healing, fewer amputations and improved survival (Kerr, 2012). However, it is believed that around 20% of hospitals providing care for people with diabetes do not have a MDFT and in many parts of the

country there are no clear pathways for rapid referral and treatment of patients with new ulcers (Kerr, 2012). Furthermore, there is wide underutilisation of total contact casting (TCC), which is considered as ‘gold standard’ care for offloading DFUs (Fife et al, 2010; Synder et al, 2014; Armstrong et al, 2014).

Offloading evidence

Within its guidelines, National Institute for Health and Care Excellence (NICE, 2004) recommends offloading devices that reduce peak plantar pressures and redistribute pressure from the site of the ulceration in patients with acute foot problems. TCC has been used for offloading DFUs since the mid 1960s and has subsequently become regarded by practitioners as the ‘gold standard’ treatment for offloading the plantar surface of the foot (Boulton and Armstrong, 2004).

TCC is effective for a number of reasons. It has been shown to reliably reduce plantar pressure by 84–92% (Lavery et al, 1996), increase healing rates and time to healing in plantar ulcers (Armstrong et al, 2001) (*Figure 1*) and reduce complications such as infection (Mueller et al, 1989) and amputation (Fife et al, 2010).

When compared to removable offloading devices, improved healing outcomes with TCC are believed to be due to the fact that the patient

Authors

Emily Sambrook, Specialist Podiatrist At Risk Foot, Solent NHS Trust, Tom Delpierre, Specialist Podiatrist At Risk Foot, Solent NHS Trust, Graham Bowen, Head of Podiatry, Solent NHS Trust

is not able to remove the cast and adherence to treatment is enforced (Armstrong et al, 2001). Armstrong et al (2003) reported that patients treated with a removable device wore it for a total of 28% of their daily activity, with none achieving more than 60% (Armstrong et al, 2003).

TCC is also considered a cost-effective treatment; the average cost of treatment per patient is \$11,946 (£7,697*) versus \$22,494 (£14,493*) when TCC is not used (Fife et al, 2010).

However, while the evidence supports the use of TCC in the treatment of plantar ulcers, there is a gap in practice for adequate offloading. Fife et al (2010) using real-world data from a large wound care registry found that only 6% of DFU patients received TCC. In a five-year retrospective analysis in over 25,000 patients with diabetes, only 3.7% of eligible ulcers received TCC (Fife et al, 2014), while the most frequently used method of offloading (postoperative shoe) was the least effective.

Under-usage of TCC represents lost opportunities for healing wounds, improving patients' quality of life and maximising the efficiency of healthcare systems. However, there are numerous reasons why TCC may not be used:

- Time-consuming to apply
- Lack of skill or confidence in application of TCC
- Lack of availability of a specialist/cast technician with adequate training or experience to safely apply a TCC
- Fear of causing harm (e.g. further tissue damage)
- Impact on patient lifestyle
- Patient compliance (e.g. often prefer removable devices/previous negative experience with TCC).

These challenges mean that there are often variations in the use of TCC, leading to different degrees of gold standard service being offered across the UK. Therefore, the future of offloading treatments would appear to be in the use of TCCs that are easy to apply, do not require extensive training, and encourage patient concordance with treatment.

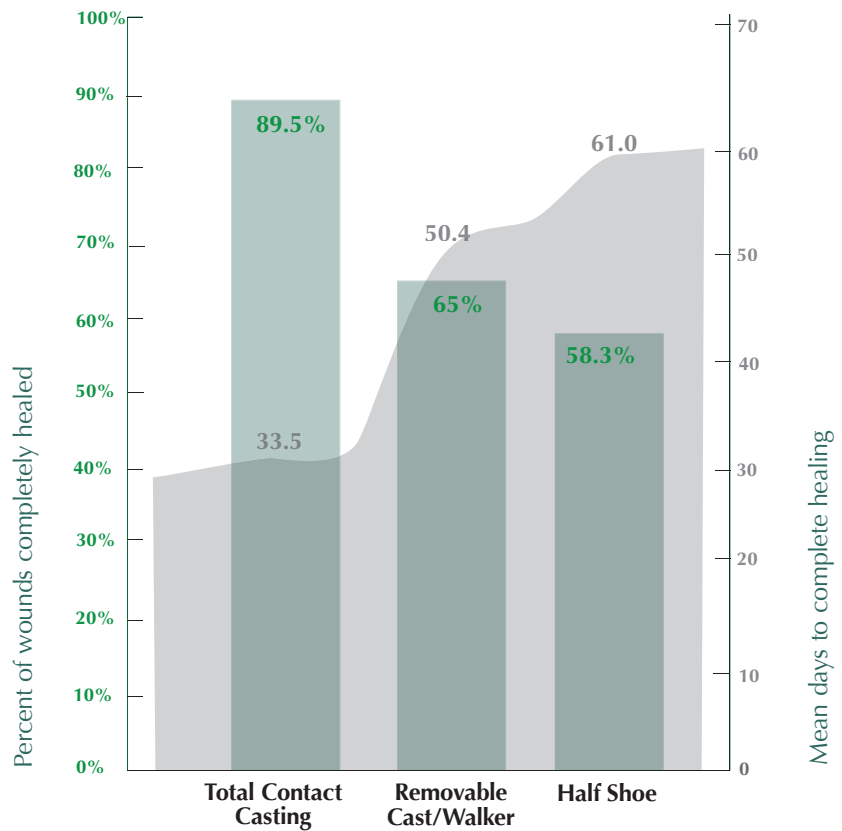


Figure 1. Comparison of wound healing using different offloading devices (from Armstrong et al, 2001).

Advancing the gold standard

TCC-EZ® (Derma Sciences) is a single-component kit for a roll-on, lightweight woven sock that creates an instant cast, which delivers offloading. It is combined with a

boot attachment that provides stability and strength, allowing weight bearing (Figure 2).

Application of TCC-EZ is easier and faster than traditional systems, taking a quarter of the time (under 10 minutes) to apply when compared to a traditional plaster cast (Bohn, 2009). In a study of 100 patients, clinicians were able to apply TCC-EZ in a busy clinic and the 'roll-on nature' of the cast required almost no learning curve prior to application. In addition, no patient had serious complications caused by application errors (Jensen et al, 2008).

Where TCC-EZ has been trialled in Solent NHS Trust, it has helped to get more patients into TCC and avoided delays in referral to the orthopaedic department. It can be applied by a practitioner who has received the relatively simple standard competency training — there is no need to refer on — allowing the patient to stay in the system, rather than being lost to another service. The TCC-EZ cast comes as an off-the-shelf pack and can

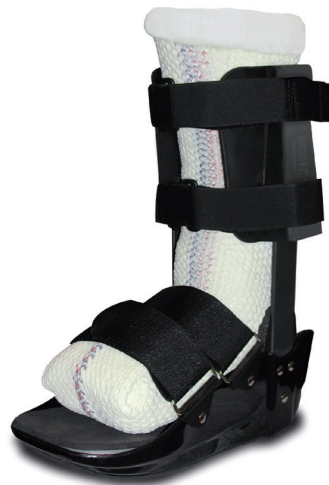

Figure 2. TCC-EZ casting device.

be consistently applied by different, similarly trained practitioners in different settings. By not being tied to plaster casting, the device can be made more portable, with patients able to be seen closer to home in clinics across the trust.

Patient concordance is the key to effective offloading. Due to its lightweight nature, patients find the TCC-EZ cast to be more comfortable than traditional TCC. Patients can be more mobile (the detachable walking boot avoids the need for crutches) and can continue with daily activities, giving them greater independence. People with balance issues are often not suitable for TCC, but can be put into the TCC-EZ cast. However, as with any offloading device, patients are advised to rest as much as possible to assist healing.

Amputation is always preceded by ulceration; improvement in healing rates, by whatever means, will have a huge overall benefit, not only for the patient, but also for the local health economy. Solent NHS Trust targets are to reduce amputation rates by 50% over the next five years. If, by utilising TCC-EZ, forefoot ulceration can be healed within the average

of 5–8 weeks, it will have far-reaching effects. This may be further supported by changes in practice, whereby planning customised footwear before the patient comes out of the cast may minimise re-ulceration.

In Solent NHS Trust, use of TCC-EZ has helped to overcome delays in providing gold standard treatment. Patients can be identified earlier and decisions about treatment stay with practitioners directly involved in their care. This has increased individual ownership of the integrated diabetic foot pathway (see video at: <http://bit.ly/1AOZ84E>).

Studies have shown that earlier interventions can reduce time to healing and the rate of amputations (Kerr, 2012). Getting more patients into TCC-EZ, healed and back into footwear will increase productivity, with more patients receiving gold standard care, reducing hospital admissions for diabetic foot problems, and potentially decreasing nursing time and resource use. As well as getting new patients onto the diabetic foot pathway earlier, TCC-EZ has also helped to provide solutions for those complex patients

in whom it has not been clear what to do next.

Clinical experience of using TCC-EZ

The following case studies describe how TCC-EZ can be used in practice to optimise outcomes in patients with complex diabetic foot ulcers.

Case 1

Mr J is a 50-year-old man with a history of type 2 diabetes, atrial fibrillation and hypertension. Current medication is: metformin, gliclazide, exenatide, amlodipine, simvastatin, bisoprolol and omeprazole. His blood glucose was suboptimal at HbA1c 76 mmol/mol. Pedal pulses were palpable and strong, and monofilaments were recorded as 4/10 to the right foot.

He had served in the armed forces and following a shrapnel wound to the left leg in 1982, he had sustained severe nerve damage, with the development of peripheral neuropathy. This led to the development of a heel ulcer, which became infected and resulted in a below-knee amputation in May 2010.

He did not present to Podiatry until September 2012, when he had a small superficial fissure over the right first plantar surface, which deteriorated due to infection. He was followed regularly in the clinic, but due to work commitments this was not always as often as necessary, and compliance with treatment was poor.

He was seen and assessed in the diabetic multidisciplinary foot clinic at Portsmouth Hospital, where he was referred to orthopaedics to be assessed for TCC, as previous functional insoles had had little benefit.

It took 6 weeks before he was seen in the orthopaedics department and he was placed into TCC. Once healed, he remained ulcer-free until January 2014, at which time the area broke down due to mechanical trauma.

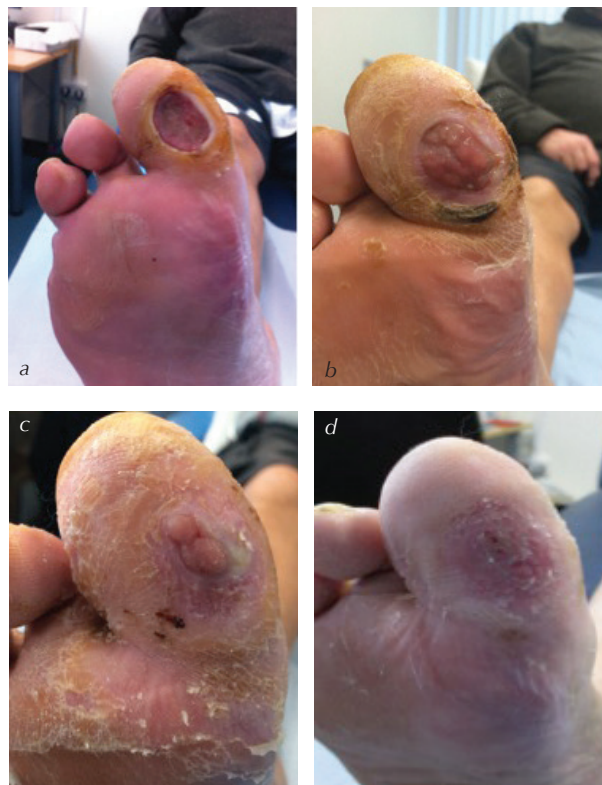

Figure 3a. Case one — Pre-TCC-EZ (November 18 2014). The wound measured 30mm x 18mm x 4mm.
 Figure 3b. One month after start of treatment with TCC-EZ (December 22 2014). The wound had decreased in size and now measured 20mm x 12mm x <2mm.
 Figure 3c. Ulcer almost healed (January 13 2015), measuring 10mm x 5mm x <2mm.
 Figure 3d. Ulcer healed 11 weeks (January 27 2015).

He was not referred back to Podiatry once his ulcer had healed and following the appearance of the new ulceration he did not contact Podiatry for another 4 months, at which stage he reported repeated infections with deterioration to the ulcer.

At this stage, the patient was frustrated with the slow rate of healing and was not keen to take more time off work. An alternative offloading device (TCC-EZ) was discussed with the patient. The reported 89% healing rate over 5–8 weeks (mean 6 weeks) with the device was used as a key point for the patient to engage in treatment. This healing time gave the patient a specific goal and allowed him to organise work and home with an end date in mind. This improved his compliance with treatment (Armstrong et al, 2001).

He did not want to be referred to another service who would be unaware of his history, but wanted to be seen weekly by a clinician he trusted (before using TCC-EZ the patient would have been referred to orthopaedics for traditional casting). He was happy to be seen weekly for the TCC-EZ cast to be applied and progress monitored. The continuity of care this offered the patient, and the improvement that was seen, continued to improve the patient's compliance and confidence in the system.

The weekly improvement of the ulcer impressed both the patient and team. The patient has found the cast lightweight and comfortable, not too restrictive but stable at the same time. Balance was not affected with his prosthetic limb and he has remained relatively active throughout the process. Ease of application made the process a pleasant experience for the patient, who remarked that "he enjoyed his weekly massage".

Although the patient did not heal within the 6-week average, he could clearly see the weekly improvement, which was encouraging, and he was happy to

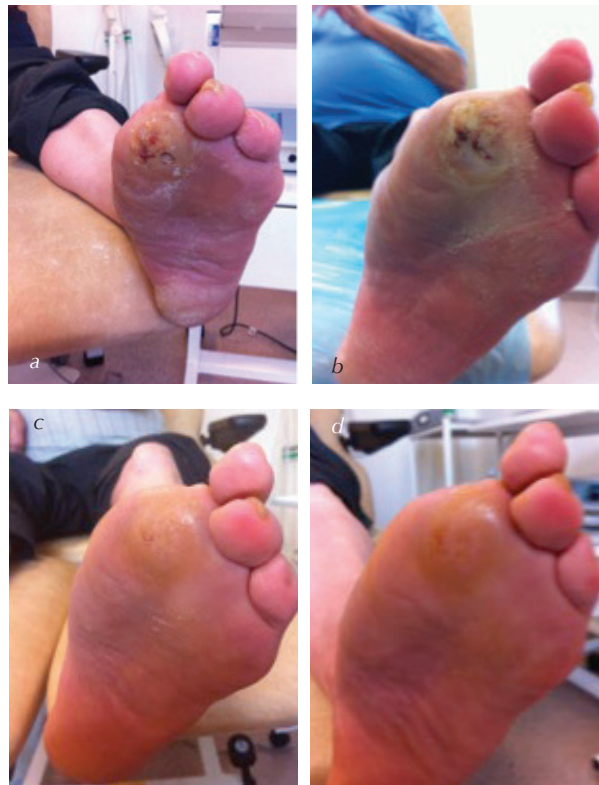

Figure 4a. Wound prior to debridement and commencement of TCC-EZ cast (September 16 2014). Wound measured 7mm x 6mm x 2mm. There is heavy surrounding callus; the wound is static with adhered slough at the base; there is moderate exudate and oedema in the lower limb.
 Figure 4b. Wound after debridement following removal of cast (September 18 2014). Wound measured 5mm x 4mm x 1mm. There was light surrounding callus. Wound had reduced in size with peelable slough, granulation tissue, moderate exudate and strikethrough to the dressing. Limb oedema had reduced.
 Figure 4c. Wound following cast removal (October 7 2014). Wound has healed. There is light surrounding callus. Wound is epithelialising and there is no exudate on the dressing.
 Figure 4d. Wound post cast removal (October 14 2014). Wound is completely healed with minimal surrounding callus and no exudate on dressing removal. Surrounding skin looks healthy and well hydrated.

continue treatment. The patient being an amputee did not stop the staff using TCC-EZ and the patient was able to mobilise without any problems.

Case 2

A 73-year-old man presented with a history of previous ulceration on the left foot, resulting in amputation of the first and second toes. He has insulin-dependent type 2 diabetes, diagnosed in 1999, with hypertension and elevated cholesterol, controlled with simvastatin, ramipril and ranitidine to prevent stomach ulceration. The patient has biphasic pedal pulses with good microcirculation and venous return, left foot scores were 3/10 and right foot 5/10 with 10g monofilament.

The left first toe amputation was performed in September 2009 following

ulceration and infection on the plantar aspect of the first interphalangeal joint. The left second toe was amputated in December 2009 following ulceration and underlying osteomyelitis. Prior to the TCC-EZ cast, he wore bespoke footwear and orthoses to redistribute pressure, helping to prevent further ulceration.

“Ease of application made the process a pleasant experience for the patient, who remarked that “he enjoyed his weekly massage.”

Trauma to left first amputation site led to ulceration on the plantar aspect of first metatarsal phalangeal joint area in 2010, which healed in 14 weeks with podiatry intervention. Subsequent ulceration on the plantar first/second metatarsal phalangeal joints on the left foot in 2012 and 2013 were managed by the podiatry team. X-ray of the area showed no underlying deformities, osteomyelitis or bone shards present in the wound. The wound healed within 8 weeks.

In May 2014, the amputation site re-ulcerated and became infected. Infection was managed with 500mg flucloxacillin four times daily and the wound decreased in size over 6 weeks (from 20mm x 16mm x 2mm baseline to 8mm x 7mm x 2mm). In August 2014 the wound deteriorated again, measuring 30mm x 27mm x 4mm on presentation following the patient's holiday. By September 2014, the wound had become static despite offloading the wound with 10mm semi-compressed felt plantar padding and bespoke orthoses.

The decision was made in September 2014 to use an offloading cast. TCC-EZ, a new system in the UK, was chosen, having been used in the USA with excellent results. TCC-EZ was applied on 16 September 2014. A petrolatum-gauze dressing was applied under the cast from week 3 to hydrate the skin on the foot.

After 3 weeks' treatment, the wound had healed. The decision was made to continue use of the cast for a further week, to allow healed tissue to strengthen and help reduce risk of re-ulceration. The cast was removed one week later and the patient returned to bespoke footwear with custom orthoses to manage plantar pressures and reduce risk of re-ulceration. The patient subsequently had a rub on the dorsum of the third and fourth toes from his footwear; these areas healed within 3 weeks and the patient remains ulcer-free 10 weeks post-TCC-EZ removal.

The patient's compliance and cooperation has been a key factor in ensuring success with TCC-EZ. He was happy that he was able to continue his daily activities and, in particular, was able to maintain his role as main carer by visiting his wife in hospital on a regular basis and managing the house while ensuring he rested sufficiently to heal his wound.

Summary

The cost of ulceration and amputation care for people with diabetes is likely to rise substantially unless there are a

significant changes in the delivery of diabetic foot care services within the NHS. Provision of higher quality, cost-effective foot care for people with diabetes, and early intervention to avoid complications, are likely to play an important part in attempts to improve the overall quality and productivity of the NHS in the coming years (Kerr, 2012).

Offloading is key to preventing and healing plantar neuropathic foot ulcers in diabetes. TCC is recommended in guidelines as a first-line option for offloading; however, the use of irremovable devices has been found to be low.

Embedding TCC-EZ into current working practices can help to offset some of the challenges of TCC. Clinical experience and early evidence indicates an important role for TCC-EZ as a method of TCC offloading in patients with diabetic foot problems. One of the most attractive features of TCC-EZ is that it is easy to apply and safe to use, allowing clinicians with different levels of experience to use the device confidently.

Improving diabetes footcare and reducing amputations saves lives and saves money (Feet First — <http://www.scpod.org/easysiteweb/getresource.axd?assetid=35947>). CCGs should set themselves challenging targets for reducing amputations each year with the involvement of people with diabetes and local clinicians. ■

Acknowledgement

The product used by the authors was purchased from Derma Sciences and training was provided by the company to both Emily Sambrook and Tom Delpierre.

Armstrong DG, Isaac AL, Bevilacqua N, Wu S (2014) Offloading foot wounds in people with diabetes. *Wounds* **26**: 13–20

Armstrong DG, Nguyen H, Lavery LA et al (2001) Off-loading the diabetic foot wound. *Diabetes Care* **24**: 1019–22

Armstrong DG, Lavery LA, Kimbriel HR, et al (2003) Activity patterns of patients with diabetic foot ulceration: patients with active ulceration may not adhere to a standard offloading regimen. *Diabetes Care* **26**: 2595–7

Bohn G (2009) Cost Effectiveness and Implementation of an Easy to Apply Total Contact Casting System for Diabetic Grade 2 Neuropathic Foot Ulcers in a Multi Physician Clinic. Clinical Symposium on Advances in Skin and Wound Care, October 2009, San Antonio, USA, Poster

Boulton A, Armstrong DG (2004) Off-loading in trials of neuropathic diabetic foot ulceration. Further evidence for a paradigm shift. *Diabetes Care* **27**: 636–7

Diabetes UK (2012) *State of the Nation 2012: England*. Diabetes UK, London

Edmonds M (2006) Adjunctive treatments for wound healing in the diabetic foot. *The Diabetic Foot Journal* **9**: 128–36

Fife CE; Carter MJ, Walker D (2010) Why is it so hard to do the right thing in wound care? *Wound Rep Reg* **18**: 154–8

Fife CE, Carter MJ, Walker D et al (2014) Diabetic foot ulcer offloading: the gap between evidence and practice. Data from the US Wound Registry. *Adv Skin Wound Care* **27**: 310–6

Jensen J, Jaakola E, Gillin B et al (2008) *TCC-EZ – Total Contact Casting System Overcoming the Barriers to Utilizing a Proven Gold Standard Treatment*. Diabetic Foot Global Conference, 2008

Lavery LA, Vela SA, Lavery DC, Quebedeaux TL (1996) Reducing dynamic foot pressures in high-risk diabetic subjects with foot ulcerations. A comparison of treatments. *Diabetes Care* **19**: 818–21

McInnes AD (2012) Diabetic foot disease in the United Kingdom: about time to put feet first. *Journal of Foot and Ankle Research* **5**:26

Mueller MJ, Diamond JE, Sinacore DR, et al (1989) Total contact casting in treatment of diabetic plantar ulcers. Controlled clinical trial. *Diabetes Care* **12**: 384–8

Kerr, M (2012) *Inpatient Care for People with Diabetes – The Economic Case for Change*. NHS Diabetes. Available at: <http://bit.ly/1LHdese> (accessed 27.02.2015)

National Institute for Health and Care Excellence (2004) *Type 2 diabetes foot problems: Prevention and management of foot problems*. Guidance CG10. Available at: <https://www.nice.org.uk/guidance/cg10> (accessed 27.02.2015)

Raspovic A, Landorf KB (2014) A survey of offloading practices for diabetes-related plantar neuropathic foot ulcers. *J Foot Ankle Res* **7**: doi 10.1186/s13047-014-0035-8

Robbins JM, Strauss G, Aron D et al (2008) Mortality rates and diabetic foot ulcers: Is it time to communicate mortality risk to patients with diabetic foot ulceration? *J Am Pod Med Assoc* **98**: 489–93

Snyder R, Frykberg R, Rogers L et al (2014) The management of diabetic foot ulcers through optimal offloading. *J Am Pod Med Assoc* **104**: 555–67

Quality Outcomes Framework (QOF) (2013) England: Diabetes prevalence. Available at: <http://bit.ly/1dR5kdG> (accessed 27.02.2015)

Wounds International (2013) *Best Practice Guidelines: Wound Management in Diabetic Foot Ulcers*. Wounds International. Available at: <http://bit.ly/1DpEiZm> (accessed 27.02.2015)