

Hyperbaric oxygen therapy for chronic diabetic foot ulceration

Magnus Löndahl, Katarina Fagher,
Per Katzman

Hyperbaric oxygen therapy as an adjunct therapeutic modality for chronic wounds has been used for some 50 years. Here, the authors present a review of the basic science of hyperbaric oxygen therapy, its clinical indications and complications, as well as data on the modality's clinical effectiveness in the treatment of diabetic foot ulcers.

Despite significant reductions in the frequency of diabetes-related major amputations achieved within the multidisciplinary team model, non-healing diabetic foot ulcers remain a major problem (Faglia et al, 1998; Krishnan et al, 2008). Even within centres of excellence, 19–35% of diabetic foot ulcers are reported to be non-healing at 1-year follow-up (Prompers et al, 2008; Gershater et al, 2009). Thus, there is need for treatment modalities that promote healing in the chronic diabetic foot ulcer. One modality that has been under investigation for some 50 years is hyperbaric oxygen therapy (HBOT).

HBOT: Basic science

Under normal environmental and physiological conditions, haemoglobin carries the majority of oxygen in the blood and only a fraction is dissolved in blood plasma. Neither an increase in barometric pressure alone, nor an ambient oxygen concentration of 100%, will increase haemoglobin-mediated oxygen transport in people with normal cardiac and pulmonary function to a clinically relevant degree.

However, increased barometric pressure facilitates the dissolution of oxygen in blood plasma, and breathing pure oxygen at 2.5 Atmosphere Absolute (ATA) will achieve close to 60 mL of oxygen per litre of blood plasma; such conditions are sufficient to meet tissue oxygen demand at rest, without the contribution of haemoglobin. Furthermore, HBOT increases the diffusion distance of oxygen from capillary to tissue from 64 μm to 247 μm (Figure 1). Thus, under these conditions, oxygen dissolved in blood plasma can more readily reach body tissues (Gill and Bell, 2004).

This HBOT-mediated increase in tissue oxygen availability has been shown to stimulate angiogenesis and the development of granulation tissue formation through enhancement of fibroblast function, and control of infection due to improved leukocyte function in wounds (Hunt and Pai, 1972; Hunt et al, 1975; Knighton et al, 1981). Given this, HBOT may be undertaken by people with ischaemic diabetic foot ulcers so that the ulcer site might benefit from the increased tissue oxygenation conferred by HBOT and so heal.

Article points

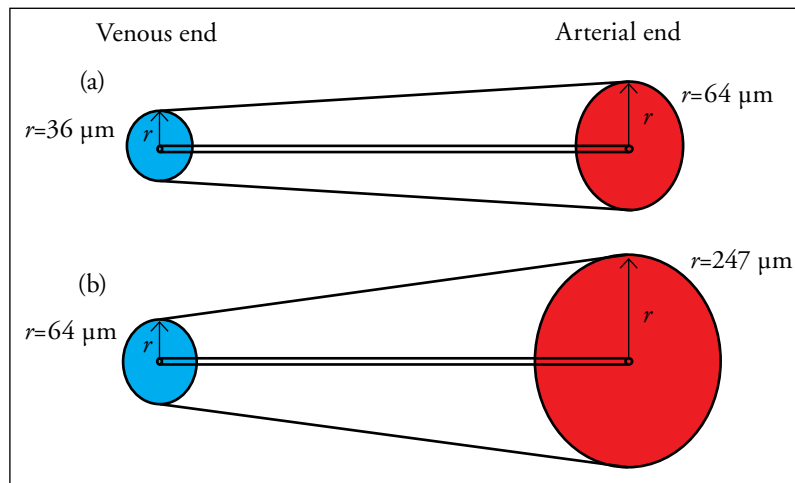
1. Increased barometric pressure facilitates the dissolution of oxygen in blood plasma and this has been shown to stimulate angiogenesis and the development of granulation tissue formation and improve leukocyte function in chronic wounds.
2. The use of hyperbaric oxygen therapy to treat chronic wounds has been undertaken for some 50 years, and its first reported use in diabetic foot ulcers was in 1979.
3. Some studies find that hyperbaric oxygen therapy in conjunction with multidisciplinary wound care can reduce chronic diabetic foot ulcer size, improve healing rates, reduce amputation rates and improve health-related quality of life.

Key words:

- Chronic diabetic foot ulcer
- Hyperbaric oxygen therapy

Author details be found on the last page of this article.

Figure 1. Diagrams (not to scale) representing the diffusion of oxygen to tissues while (a) breathing air at 1 ATA, and (b) breathing pure oxygen at 3 ATA.



Clinical setting of HBOT

HBOT for wound healing is a systemic therapy during which a person enters an environment with increased barometric pressure and breaths 100% oxygen. This can be achieved in two ways: monoplace or multiplace hyperbaric chambers (Figure 2).

Monoplace chambers are most commonly used to deliver HBOT. The monoplace chamber is filled with 100% oxygen under pressure. The pure oxygen environment makes the monoplace chamber a potential fire hazard.

Multiplace chambers are annexed by an antichamber and contain air. People receiving therapy in a multiplace chamber breath 100% oxygen via a rubber or silicon hood or mask, thereby reducing the risk of fire, but making therapy more arduous for the person receiving therapy.



Figure 2. An example of a multiplace hyperbaric chamber.

Treatment schedules

HBOT in the management of diabetic foot ulcers is usually given as daily treatments at 2.0–2.5 ATA for 90–120 minutes. An additional 5–10 minutes per session is required for compression and decompression. If the person receiving therapy experiences discomfort (see below for further discussion of complications) the session can be discontinued. Some centres schedule one or two 5-minute long “air breaks” during which the pure oxygen is replaced with by air in an effort to reduce the risk of oxygen toxicity. A course of treatment for a chronic wound usually consist of between 20 and 40 sessions. Although HBOT is time-consuming, people receiving the treatment report it to be well-functioning, unproblematic and pleasant (Hjelm et al, 2009).

Contraindications

Absolute contraindications for HBOT include untreated pneumothorax and concomitant use of certain chemotherapeutics. Relative contraindications are upper-respiratory infections, chronic sinusitis (risk of otobarotrauma), severe emphysema (risk of pneumothorax), high fever (risk of seizure) and pregnancy (risk of congenital malformations following HBOT during early pregnancy in animal studies [Jain, 2009]).

Complications

Common complications

The most common complications of HBOT are middle-ear barotraumas. Ear pain or discomfort when equalising middle-ear pressure during HBOT has been reported in up to 20% of those receiving treatment. Injuries caused by HBOT visible on ear microscopy are uncommon, with reported incidences between 0.5 and 3.8% (Plafki et al, 2000; Sheffield, 2002; Löndahl et al, 2010).

Avoiding severe middle-ear barotrauma is important and people undergoing HBOT should be taught Valsalva’s manoeuvre to equalise middle-ear pressure. Tympanostomy with tube placement may be performed in those unable to equalise their own ear pressure.

Sinus entrapment, especially in the frontal sinuses, may cause severe pain during HBOT and sessions should be postponed if the patient has an upper-respiratory infection.

Reversible myopia, due to oxygen toxicity of the lens, is a common side-effect of HBOT with up to one in five people affected and may last for weeks or months (Heyneman and Lawless-Liday, 2002). Animal studies and clinical trials show an increased risk of developing cataract after prolonged HBOT (Palmquist et al, 1984; Varma, 1991).

Rare complications

Oxygen seizures are a rare complication of HBOT (approximately 1/10 000 treatments). Epileptic fits are also rare and do usually not cause permanent damage. The convulsions are self-limiting and are treated by stopping the supply of pure oxygen to the chamber (Plafki et al, 2000).

Pulmonary barotrauma, with pneumothorax or gas embolism, is a rare (1/50 000–60 000 treatments), but potentially severe, complication of HBOT (Murphy et al, 1991; Trytko and Bennett, 1999).

A rare but fatal complication of HBOT is chamber fire. Such events have not been reported in multiplace chambers (Sheffield and Desautels, 1997).

Health economics

A health economics review published in 2008 (Chow et al) analysed a range of adjuvant therapies for the treatment of the diabetic foot, including HBOT. HBOT was found to produce an incremental cost per quality-adjusted life year (QALY) at year 1 of US\$27 310 and US\$2255 at year 12 (2001 values). Chow et al concluded that, although HBOT may be more cost-effective than traditional therapies alone, more research is required to confirm this.

A study in a Canadian cohort found that the 12-year ulcer treatment cost for people receiving standard care plus HBOT was CND\$40 695, compared with CND\$49 786 for standard care alone (Chuck et al, 2008).

Improvements in QALYs were also found in those receiving HBOT compared with controls (3.64 vs 3.01 QALYs). Chuck et al concluded that HBOT for diabetic foot ulceration was cost-effective compared with standard care, but that the capacity to provide the therapy at a large scale was low.

Thus, access to HBOT is limited to those who have access to chambers through a diabetic foot care service involved in delivering this type of adjuvant therapy, and is also limited by a person's proximity to a chamber, which are traditionally located only in large hospitals.

Clinical use of HBOT in the treatment of diabetic foot ulcers

HBOT has been used in the management of chronic wounds for about 50 years (Lee Williams, 1997), but the first study reporting its use in people with diabetic foot ulcers was published in 1979 (Hart and Strauss). In this small, retrospective study 10 out of 11 people with chronic ulcers healed following HBOT. The results were described by the authors as "a fair and good response" to the treatment.

The first prospective, controlled study to investigate HBOT in diabetic foot ulceration was published in 1987 (Baroni et al). Eighteen hospitalised inpatients with Wagner grade 3 and 4 diabetic foot ulcers were matched for ulcer duration, lesion size, sub-fascia involvement and the severity of diabetes-related micro- and macrovascular disease. Attending surgeons taking decisions about amputations were blinded as to which group inpatients belonged. In the HBOT group 16 people's ulcers healed and two underwent amputation, compared with one healed, four amputations and 13 remained unhealed in the control group. The authors concluded that HBOT was beneficial in the treatment of diabetic Wagner grade 3 and 4 foot ulcers.

Seven randomised, controlled trials evaluating the effect of HBOT as an adjunct therapy in the management of diabetic foot ulceration have been reported to date (*Appendix I*; Doctor

Page points

1. Oxygen seizures are a rare complication of hyperbaric oxygen therapy (HBOT; approximately 1/10000 treatments).
2. The cost-effectiveness of HBOT is yet to be firmly shown.
3. HBOT has been used in the management of chronic wounds for about 50 years, but the first study reporting its use in people with diabetic foot ulcers was published in 1979.
4. Seven randomised, controlled trials evaluating the effect of HBOT as an adjunct therapy in the management of diabetic foot ulceration have been reported to date.

Page points

1. Four trials have assessed the rate of above-ankle amputation following hyperbaric oxygen therapy (HBOT) or control and, overall, 8.6% of people who received HBOT underwent above-ankle amputation, compared with 19.6% of controls.
2. Abidia et al (2003) report a 58% ulcers healing rate in the HBOT group, and none in the control group.
3. Investigating the effect of HBOT on health-related quality of life, Abidia et al (2003) showed a significant improvement in general health and vitality, and Lin et al (2006) report an overall improvement in quality of life following HBOT linked to a reduction in self-perceived wound severity.
4. Several studies indicate that transcutaneous partial pressure of oxygen measures may be a useful predictor of wound healing following HBOT.

et al, 1992; Faglia et al, 1996; Lin et al, 2001; Abidia et al, 2003; Kessler et al, 2003; Duzgun et al, 2008; Löndahl et al, 2010). One of these trials, which evaluated the effect of HBOT versus sham HBOT on transcutaneous partial pressure of oxygen (TcPO₂) in 29 people with diabetes, is excluded from this review as it has only been presented as an abstract (Lin et al, 2001).

Amputation

Four trials (Doctor et al, 1992; Faglia et al, 1996; Abidia et al, 2003; Löndahl et al, 2010), comprising 210 people with diabetic foot ulceration randomised to receive HBOT or control, have assessed the rate of above-ankle amputation. The follow-up periods of these studies varied, from discharge in Doctor et al's (1992) study, to 7 weeks in Faglia et al's (1996) study, and 1 year in the studies by Abidia et al (2003) and Löndahl et al (2010). Overall, 8.6% (9/108) of people who received HBOT underwent above-ankle amputation, compared with 19.6% (20/102) of controls.

In the study by Duzgun et al (2008), amputations were classified as proximal ("major amputation") or distal ("minor amputation") to the metatarsophalangeal joint. The rate of major amputations in this study was, according to this definition, 34% in the control group and none in the HBOT group.

Ulcer healing and reduction in ulcer size

The study by Kessler et al (2003) evaluated the effect of twice-daily HBOT sessions for 2 weeks (20 sessions) on ulcer area. By study end, ulcers in the HBOT group were significantly smaller compared with those not receiving HBOT.

Two studies report ulcer healing rates at 1 year. In the study by Abidia et al (2003) of 17 people, 58% of ulcers in the HBOT group were healed, while none in the control group had healed. In the study of 75 people by Löndahl et al (2010) healing rates were 61% in the HBOT group and 27% in the control group.

Health-related quality of life

Healing of diabetic foot ulcers leads to improved health-related quality of life (HRQOL), as can be shown by using the self-reported 36-Item Short-Form Health Survey (SF-36) health measurement instrument (McHorney et al, 1993; Sullivan and Karlsson, 1998; Ragnarson Tennvall and Apelqvist, 2000; Armstrong et al, 2008).

Investigating the effect of HBOT on HRQOL, Abidia et al (2003) evaluated 18 people with Wagner grade 2 diabetic foot ulcers in a randomised, placebo-controlled study and showed a significant improvement SF-36 domains in terms of general health and vitality, but no change in physical or mental health summary scores, in the HBOT-group. In another small study by Lin et al (2006), evaluating HRQOL in 15 people with foot ulcers (11 with diabetic foot ulcers), overall QOL improved following HBOT. The improvement was linked to a reduction in self-perceived wound severity. In those with longer ulcer duration and deeper ulcers (mainly Wagner grade 3) Löndahl et al (2011a) showed significantly improved HRQOL in terms of SF-36 domains physical and emotional roles at 1-year follow-up in those receiving HBOT, but not in the control group.

TcPO₂ as a predictor of outcome

Unlike toe blood pressure and ankle-brachial pressure index, TcPO₂ seems to reflect micro- as well as macrocirculation. Several studies indicate that TcPO₂ – being a composite measure of several factors (arterial pressure, arterial oxygen content, local tissue perfusion pressures, neurovascular function and local oxygen consumption) – may be a useful predictor of wound healing following HBOT.

In a prospective, randomised, placebo-controlled study TcPO₂ was significantly correlated with long-term foot ulcer healing after HBOT in a group of 38 people with diabetic foot ulcers (Löndahl et al, 2011b). None of the participants with a basal TcPO₂ <25 mmHg healed, whereas healing rates in those with TcPO₂ 26–50, 51–75

and >75 mmHg were 50, 73 and 100%, respectively. Similarly, in a case series of 629 patients by Fife et al (2007), participants with a basal TcPO₂ <25 mmHg were less likely to benefit from HBOT than those with higher TcPO₂ values. In a retrospective analysis of 1144 people, TcPO₂ measured in the hyperbaric chamber provided the best single discriminator between healing and non-healing following HBOT (Fife et al, 2002).

Conclusion

Although access to such technology is not universal nor always practicable, a number of studies suggest that HBOT as an adjunct to multidisciplinary diabetic foot care improves healing of chronic diabetic foot ulcers. Evidence is lacking for the use of HBOT in people with acute diabetic foot ulcers. ■

Authors

Magnus Löndahl and Per Katzman are Consultant Physicians, Department of Endocrinology; Katarina Fagher is a Resident Physician, Department of Emergency Medicine. All are based at Skåne University Hospital, Lund, Sweden.

- Abidia A, Laden G, Kuhan G et al (2003) The role of hyperbaric oxygen therapy in ischaemic diabetic lower extremity ulcers: a double-blind randomised-controlled trial. *Eur J Vasc Endovasc Surg* 25: 513–18
- Armstrong DG, Lavery LA, Wrobel JS, Vileikyte L (2008) Quality of life in healing diabetic wounds: does the end justify the means? *J Foot Ankle Surg* 47: 278–82
- Baroni G, Porro T, Faglia E et al (1987) Hyperbaric oxygen in diabetic gangrene treatment. *Diabetes Care* 10: 81–6
- Chow I, Lemos EV, Einarson TR (2008) Management and prevention of diabetic foot ulcers and infections: a health economic review. *Int J Technol Assess Health Care* 24: 178–83
- Chuck AW, Hailey D, Jacobs P, Perry DC (2008) Cost-effectiveness and budget impact of adjunctive hyperbaric oxygen therapy for diabetic foot ulcers. *Pharmacoeconomics* 26: 1019–35
- Doctor N, Pandya S, Supe A (1992) Hyperbaric oxygen therapy in diabetic foot. *J Postgrad Med* 38: 111–14
- Duzgun AP, Satir HZ, Ozozan O et al (2008) Effect of hyperbaric oxygen therapy on healing of diabetic foot ulcers. *J Foot Ankle Surg* 47: 515–19
- Faglia E, Favales F, Aldeghi A et al (1996) Adjunctive systemic hyperbaric oxygen therapy in treatment of severe prevalently ischemic diabetic foot ulcer. A randomized study. *Diabetes Care* 19: 1338–43
- Faglia E, Favales F, Aldeghi A et al (1998) Change in major amputation rate in a center dedicated to diabetic foot care during the 1980s: prognostic determinants for major amputation. *J Diabetes Complications* 12: 96–102
- Fife CE, Buyukcakir C, Otto GH et al (2002) The predictive value of transcutaneous oxygen tension measurement in diabetic lower extremity ulcers treated with hyperbaric oxygen therapy: a retrospective analysis of 1,144 patients. *Wound Repair Regen* 10: 198–207
- Fife CE, Buyukcakir C, Otto G et al (2007) Factors influencing the outcome of lower-extremity diabetic ulcers treated with hyperbaric oxygen therapy. *Wound Repair Regen* 15: 322–31
- Gershater MA, Löndahl M, Nyberg P et al (2009) Complexity of factors related to outcome of neuropathic and neuroischaemic/ischaemic diabetic foot ulcers: a cohort study. *Diabetologia* 52: 398–407
- Gill AL, Bell CN (2004) Hyperbaric oxygen: its uses, mechanisms of action and outcomes. *QJM* 97: 385–95
- Hart G, Strauss M (1979) Response of ischemic ulcerative conditions to OHP. In: Smith G (ed). *Sixth International Congress on Hyperbaric Medicine*. Aberdeen University Press, Aberdeen: 312–14
- Heyneman CA, Lawless-Liday C (2002) Using hyperbaric oxygen to treat diabetic foot ulcers: safety and effectiveness. *Crit Care Nurse* 22: 52–60
- Hjelm K, Löndahl M, Katzman P, Apelqvist J (2009) Diabetic persons with foot ulcers and their perceptions of hyperbaric oxygen chamber therapy. *J Clin Nurs* 18: 1975–85
- Hunt TK, Pai MP (1972) The effect of varying ambient oxygen tensions on wound metabolism and collagen synthesis. *Surg Gynecol Obstet* 135: 561–7
- Hunt TK, Linsey M, Grislis H et al (1975) The effect of differing ambient oxygen tensions on wound infection. *Ann Surg* 181: 35–9
- Jain KK (ed) (2009) *Textbook of Hyperbaric Medicine*. 5th edn. Hogrefe & Huber, Göttingen
- Kessler L, Billbault P, Ortega F et al (2003) Hyperbaric oxygenation accelerates the healing rate of nonischemic chronic diabetic foot ulcers: a prospective randomized study. *Diabetes Care* 26: 2378–82
- Knighton DR, Silver IA, Hunt TK (1981) Regulation of wound-healing angiogenesis-effect of oxygen gradients and inspired oxygen concentration. *Surgery* 90: 262–70
- Krishnan S, Nash F, Baker N et al (2008) Reduction in diabetic amputations over 11 years in a defined UK population: benefits of multidisciplinary team work and continuous prospective audit. *Diabetes Care* 31: 99–101
- Lee Williams R (1997) Hyperbaric oxygen therapy and the diabetic foot. *J Am Podiatr Med Assoc* 87: 279–92
- Lin T, Chen S, Niu K (2001) The vascular effects of hyperbaric oxygen therapy in treatment of early diabetic foot. *Undersea Hyperb Med* 28(Suppl): 63
- Lin LC, Yau G, Lin TF (2006) The efficacy of hyperbaric oxygen therapy in improving the quality of life in patients with problem wounds. *J Nurs Res* 14: 219–27
- Löndahl M, Katzman P, Nilsson A, Hammarlund C (2010) Hyperbaric oxygen therapy facilitates healing of chronic foot ulcers in patients with diabetes mellitus. *Diabetes Care* 33: 999–1003
- Löndahl M, Landin-Olsson M, Katzman P (2011a) Hyperbaric oxygen therapy improves health-related quality of life in patients with diabetes and chronic foot ulcer. *Diabet Med* 28: 186–90

Page points

1. In one study, transcutaneous partial pressure of oxygen measured in the hyperbaric chamber provided the best single discriminator between wound healing and non-healing following hyperbaric oxygen therapy (HBOT).
2. Access to HBOT is not universal nor always practicable.
3. A number of studies suggest that HBOT as an adjunct to multidisciplinary diabetic foot care improves healing of chronic diabetic foot ulcers; evidence is lacking for the use of HBOT in people with acute diabetic foot ulcers.

“... a number of studies suggest that hyperbaric oxygen therapy as an adjunct to multidisciplinary diabetic foot care improves healing of chronic diabetic foot ulcers.”

APPENDIX I. A summary of the randomised trials investigating the effect of HBOT on diabetic foot ulceration.

Study	Wound description	Treatment and participants	
		Intervention	Control
Doctor et al (1992)	Chronic ulcers, not further specified	MWC; HBOT (3.0 ATA), 4x45-minute session (n=15)	MWC (n=15)
Faglia et al (1996)	Wagner grade 2-4; duration >3 months	MWC; HBOT (2.2–2.5 ATA), 38±8x90-minute sessions (n=36)	MWC (n=34)
Kessler et al (2003)	Wagner grade 1-3; duration >3 months; neuropathy present	MWC; HBOT (2.5 ATA), 20x90-minute sessions over 10 days (n=14)	MWC (n=13)
Abidia et al (2003)	Duration ≥6 weeks; diameter 1–10 cm ² ; ankle-brachial pressure index <0.8 or toe-brachial pressure index <0.7; HbA _{1c} <8.5% [<69 mmol/mol]	MWC; HBOT (2.4 ATA), 30x90-minute sessions (n=9)	MWC; sham HBOT (n=9)
Duzgun et al (2008)	Duration ≥4 weeks	MWC; HBOT (2.5 ATA), 3–45x90-minute sessions (n=50)	MWC (n=50)
Löndahl et al (2010)	Wagner grade 2–4; Duration >3 months; no need for, or possibility of, revascularisation	MWC; HBOT (2.4 ATA), 40x90-minute sessions (n=49)	MWC; sham HBOT (n=45)

ATA, Atmosphere Absolute; HBOT, hyperbaric oxygen therapy; MWC, multidisciplinary wound care.

Löndahl M, Katzman P, Hammarlund C et al (2011b) Relationship between ulcer healing after hyperbaric oxygen therapy and transcutaneous oximetry, toe blood pressure and ankle-brachial index in patients with diabetes and chronic foot ulcers. *Diabetologia* 54: 65–8

McHorney CA, Ware JE Jr, Raczek AE (1993) The MOS 36-Item Short-Form Health Survey (SF-36): II. Psychometric and clinical tests of validity in measuring physical and mental health constructs. *Med Care* 31: 247–63

Murphy DG, Sloan EP, Hart RG et al (1991) Tension pneumothorax associated with hyperbaric oxygen therapy. *Am J Emerg Med* 9: 176–9

Palmquist BM, Philipson B, Barr PO (1984) Nuclear cataract and myopia during hyperbaric oxygen therapy. *Br J Ophthalmol* 68: 113–17

Plafki C, Peters P, Almeling M et al (2000) Complications and side effects of hyperbaric oxygen therapy. *Aviat Space Environ Med* 71: 119–24

Prompers L, Schaper N, Apelqvist J et al (2008) Prediction of outcome in individuals with diabetic foot ulcers: focus on the differences between individuals with and without peripheral arterial disease. The EURODIALE Study. *Diabetologia* 51: 747–55

Ragnarson Tennvall G, Apelqvist J (2000) Health-related quality of life in patients with diabetes mellitus and foot ulcers. *J Diabetes Complications* 14: 235–41

Sheffield PJ, Desautels DA (1997) Hyperbaric and hypobaric chamber fires: a 73-year analysis. *Undersea Hyperb Med* 24: 153–64

Sheffield PJ (2002) Physiological and pharmacological basis of hyperbaric oxygen therapy. In: Cramer FS, Bakker DJ (eds). *Hyperbaric Oxygen: Perioperative Care*. 1st edn. Best Publishing, Flagstaff, AZ: 63–109

Sullivan M, Karlsson J (1998) The Swedish SF-36 Health Survey III. Evaluation of criterion-based validity: results from normative population. *J Clin Epidemiol* 51: 1105–13

Trytko BE, Bennett M (1999) Hyperbaric oxygen therapy. Complication rates are much lower than author suggest. *BMJ* 318: 107–8

Varma SD (1991) Scientific basis for medical therapy of cataracts by antioxidants. *Am J Clin Nutr* 53: S335–45