

Diagnosis challenge

In this quiz, Consultant Podiatrist Frank Webb encourages you to test your diagnostic abilities and apply your knowledge of diabetic foot treatments to a series of case studies.

Introduction

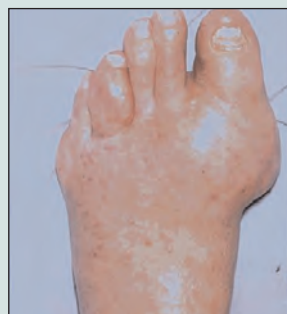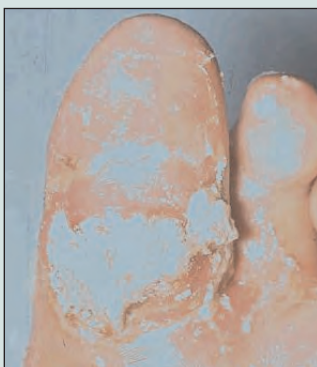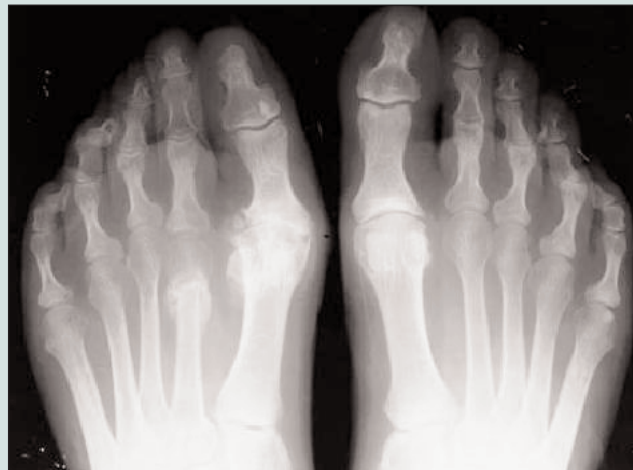
The following sets of slides contain X-rays, magnetic resonance (MR) scans and clinical pictures of the foot. A short clinical history will be given. The aim is to use the information provided along with the X-rays and MR scans to diagnose the patient's problem and to consider possible treatments. When looking at the X-rays, a simple process of using the ABCS approach (below) should help in locating abnormalities on X-rays and aid diagnosis.

- A:** Alignment of bones in relation to each other, e.g. hallux valgus, retracted toes, etc.
- B:** Bone density – are there signs of sclerosis/osteopenia or loss of bone?
- C:** Cartilage (appears black on X-rays) – is there a space between joints or is this absent?
- S:** Soft tissues, presence of gas (which would appear black), calcified vessels, ulceration, sinus tracts or foreign bodies.

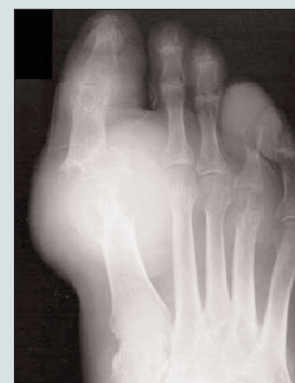Case study 1

Sixty-four-year-old male, type 2 diabetes, HbA_{1c} 7.0%, well controlled. Presented with pain and discomfort in his right first metatarsal phalangeal joint. He describes the pain as having been present for several years but which has become increasingly worse over the past three to four months.

What is the diagnosis and what are the proposed treatments?



Case study 2

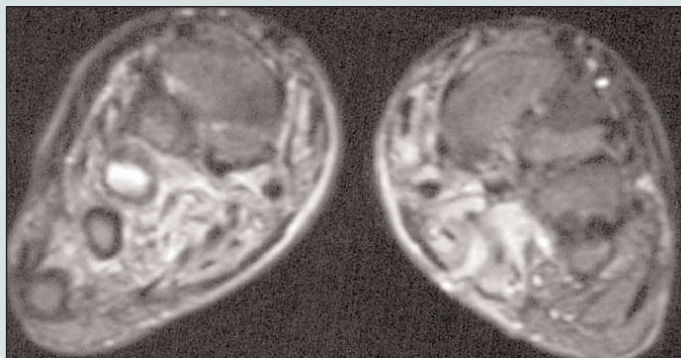
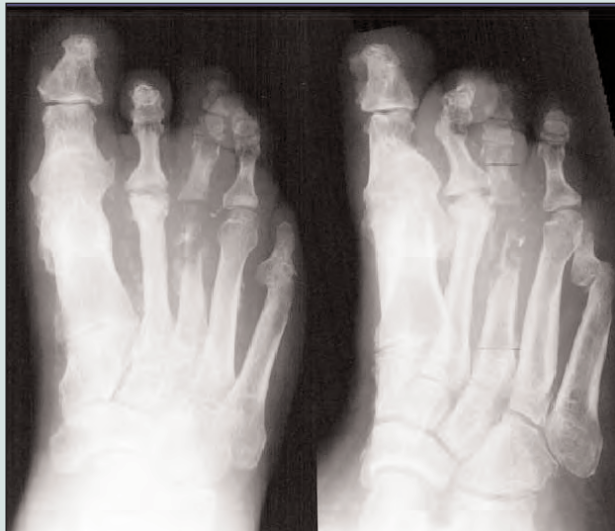

Seventy-eight-year-old male, type 2 diabetes, renal impairment and chronic heart failure. Presented with gross ulceration of his hallux on the plantar surface and first MP joint, and a moderate degree of discomfort. Neuropathy was detected. Pulses and circulation were adequate. The ulceration was foul-smelling with a copious discharge. What is the diagnosis, and what are the proposed treatments?

Case study 3

Forty-two-year-old male, type I diabetes, known to the hospital. This patient, who frequently disappears for months on end due to work commitments, returned after working away for four months. He presented to casualty feeling unwell with fever and septicaemia. On admission his HbA_{1c} level was 13.4%, and his foot and leg were grossly swollen with cellulitis extending above the knee. He also had lymphadenopathy of the knee and groin, and a large ulcer on the plantar surface of the foot. His C-reactive protein (CRP) was 243.

What is the diagnosis in this case and what are the proposed treatments?

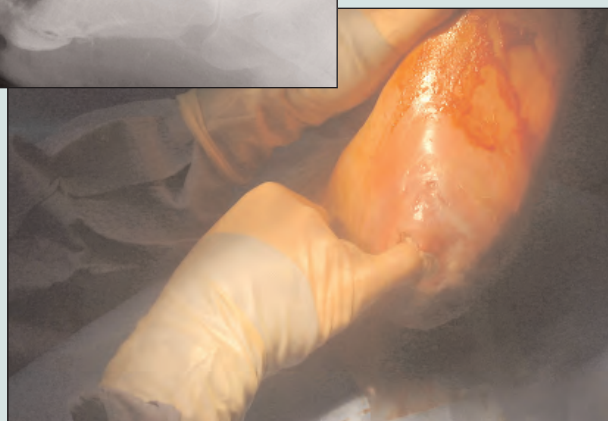
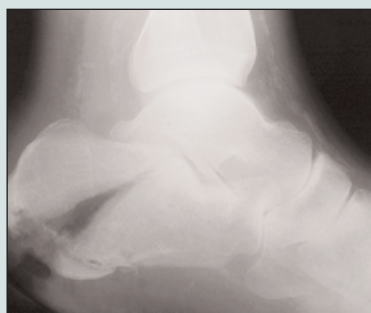

Forty-two-year-old male, type I diabetes, profound neuropathy, renal failure on haemodialysis. Presented with ulceration to his calcaneus for a duration of eight months. Test results showed HbA_{1c} 9.5%, CRP 200 and creatinine 459 µmol/L.

There has been a longstanding ulceration on the plantar surface of his right foot, with the recent development of ulceration on the left calcaneus. Initial X-rays showed no osteomyelitis. He was treated for soft-tissue infection. There are marked problems with compliance, pressure relief and antibiotic therapy due to resistances and intolerance. Further X-rays taken (e.g. see right) show the extent of bony abnormality.

What would you diagnose here and how would you treat this patient?

Case study 4



Diagnosis challenge: how many did you get right?

Below are the answers to the case studies provided by Consultant Podiatrist Frank Webb that featured on pages 145–146 of this issue.

Case study 1

Diagnosis

Hallux limitus affecting first metatarsal phalangeal joint with osteophyte formation and joint space narrowing, which has been present for a number of years. Incidence of a stress fracture in the past six to 12 months. On closer discussion with the patient, he informs that he had pain in the foot approximately nine months ago with no visible swelling but quite marked tenderness.

X-rays show a displaced fracture with bone callus formation and signs of bone healing of the second metatarsal. Due to the second metatarsal being displaced and shortened, increased pressure is put on and around the first metatarsal phalangeal joint, resulting in the increasing discomfort in this area.

Treatment

The hallux limitus could either be treated locally with orthotics to redistribute pressure, or with cortisone injections for symptomatic relief. Surgery would involve cheilectomy and/or fusion of the first metatarsal phalangeal joint.

Case study 2

Diagnosis

The extensive changes at the first metatarsal phalangeal joint and interphalangeal joint of the hallux are due to large punched-out erosions related to gout. A thick discharge was diagnosed as gouty tophi on microscopy. There is virtually total loss of the distal and intermediate phalanges of the fourth toe due to gouty erosions. Swabs were taken for culture and sensitivity of the wound, as well as samples of fluid to identify infecting

bacteria. Bloods were taken to establish the status of his urate.

Treatment

Debridement of the gouty tophi from the ulcerated site to promote healing. Unfortunately, the patient was not a suitable candidate for allopurinol due to intolerance, so his water tablets were reduced to try and control the amount of fluid loss. Surgical shoes were provided to protect his feet. The patient re-ulcerated, however, due to gouty tophi, which then required debridement from the ulcerated site to promote healing. This was done after the soft tissue infection was controlled using intravenous antibiotics, namely flucloxacillin and amoxicillin in conjunction with metronidazole.

Case study 3

Diagnosis

There is a fusion to his first metatarsal phalangeal joint, osteoarthritis to the second metatarsal phalangeal joint, osteomyelitis affecting the third metatarsal with marked loss of the head and part of the base of the proximal phalanx of the third. Periosteal reaction is extending down the shaft. There is sequestra formation and the early formation of involucrum. Calcified vessels are also noted. There is some periosteal reaction at the base of the third phalanx also.

Magnetic resonance scans were used to show the level of bone oedema in order to give a good indication of the extent of the infected bone before surgery. STIR image is shown, which clearly demonstrates a cross-sectional view of the foot showing the third metatarsal to be white showing oedema (infection) whereas the other metatarsals appear grey.

Treatment

Patient was admitted for intravenous antibiotics (clindamycin and ciprofloxacin). The surgical procedure involved removal of a third ray under local anaesthetic after the draining of an abscess three days earlier.

Case study 4

Diagnosis

Fracture of calcaneus with osteomyelitis evident, with loss of bone and irregular cortex – early periosteal reaction.

Treatment

Treatment was to place the patient in a removable cast.

Attempts were made to address his glucose levels as well as his renal function. This was extremely difficult due to poor compliance, diet and lack of attention to restricted fluid intake. This caused problems with the amount of fluid retention in the foot.

He ultimately developed methicillin-resistant *Staphylococcus aureus* (MRSA), which was located in the bone on biopsy. The patient was taken to theatre for debridement of the osteomyelitic calcaneus, with a plan to take him at a later stage for fusion. At the time of debridement the wound was cleaned and packed with gentamicin beads as well as a Collatamp (gentamicin collagen dressing).

Initially the patient made good progress. He eventually went on to fixation of the calcaneus, which failed, and now awaits further surgery. ■

Frank Webb is Consultant Podiatrist in the Department of Podiatry and Foot Health, Hope Hospital, Salford