

The role of surgery in the management of the diabetic foot

David C Mitchell

Introduction

The surgical input to diabetic foot disease is focused on the management of soft tissue infection and necrosis. The aim of surgery is to minimise tissue loss and preserve foot function. Early debridement of dead and infected tissue may prevent loss of the foot. Major limb amputation is only indicated when destruction is too extensive to permit salvage of a useful foot, or where prolonged attempts at foot salvage are inappropriate.

The role of surgery in diabetic foot disease is mainly restricted to managing the complications of advanced disease in the neuropathic or ischaemic foot. The aim is to achieve an intact foot presented 'flat to the floor' that will spread loads evenly and avoid areas of high peak pressure. Collaboration with podiatric and orthotic services is required to ensure an even distribution of pressure during walking. This becomes even more important when the shape of the foot is radically altered by surgical intervention.

The role of the surgeon

The principle non-operative role for vascular surgeons is to advise on the vascularity of the foot. This can be far from straightforward but should include ankle brachial pressure index and duplex ultrasound measurements if these are abnormal. Severe ischaemia is associated with a high mortality and this should be taken into consideration if complex surgery with a prolonged hospital stay is planned (Howell MA et al, 1989). An adequate blood supply is a prerequisite for most foot surgery. Its absence significantly limits surgical options and may indicate the need for revascularisation prior to any other intervention. If this cannot be achieved, then limb loss may be inevitable.

The role of the surgeon is mainly directed at three pathological presentations, which are not mutually exclusive. These are sepsis, necrosis and ulceration. Deformity may accompany these, either due to Charcot's osteoarthropathy, or as a consequence of surgery. The best results are obtained by a team of committed individuals and should include as a minimum, a diabetologist,

orthopaedic surgeon, vascular surgeon, podiatrist, orthotist and plaster technician (Meltzer et al, 2002). A coordinated approach is the key to obtaining a healed foot that does not repeatedly break down.

Sepsis

Sepsis in the diabetic foot can present in many ways. It can be mistaken for acute Charcot changes, resulting in the delayed use of antibiotics and surgical drainage. This may have disastrous consequences for the patient. An inflamed foot should be regarded as containing pus until this has been disproved. The possibility of misdiagnosing infection as Charcot changes should alert the surgeon to the need for early (and occasionally repeated) investigation. Ultrasound scanning by skilled healthcare professionals is good at detecting infection (Enderle MD et al, 1999). Magnetic resonance imaging is very helpful (Enderle MD et al, 1999; Tomas MB et al, 2000) but it can be difficult to consistently distinguish sepsis and inflammation in the absence of collections.

If no focal collection is found, but soft tissue infection or osteomyelitis is strongly suspected clinically, then a prolonged course of antibiotics is appropriate (Eckman MH et al, 1995). Not all infected feet will produce detectable systemic signs. An acute Charcot foot that is not responding to rest and elevation may be infected and a trial of antibiotics may be indicated. The presence of a collection, either clinically or on investigation is an indication for drainage, as is the presence of a significant cavity detected by gentle probing of an infected ulcer. If bone can be probed at the same time, there is a significant probability that there is underlying osteomyelitis (Grayson ML, 1995).

ARTICLE POINTS

- 1 Surgeons are an important part of the diabetic foot care team.
- 2 The aim of care is to have a stable foot presented 'flat to the floor'.
- 3 The help of a vascular surgeon should always be sought if ischaemia is present.
- 4 Revascularisation may prevent the loss of the ischaemic foot.
- 5 Early referral and drainage of pus may prevent loss of the foot.

KEY WORDS

- Surgery
- Diabetic foot disease
- Sepsis
- Necrosis
- Ulceration

David C Mitchell is a Vascular Surgeon, at the Department of Surgery, Southmead Hospital, North Bristol NHS Trust, Westbury-on-Trym, Bristol.

There are two reasons for adopting an aggressive surgical approach to the treatment of sepsis. Firstly, the extent of sepsis is not often fully evident on clinical examination – the signs being masked by neuropathy (Eneroth M et al, 1997). Secondly, failure to drain deeper pockets of pus can lead to extensive spread of infection and destruction of large areas of the foot, or leg.

The surgical management of sepsis is not for the junior surgeon (Lepantalo M et al, 2000). Inadequate surgery and incisions positioned unnecessarily through weight-bearing skin can compromise healing and delay recovery. It is important that preoperative consent should cover the steps to be followed in the event of extensive spreading sepsis. This should include digital and ray amputation, as well as the possibility of partial or total loss of the foot, which may be necessary in the presence of fulminant sepsis (Figure 1).

Incisions are best placed adjacent to the main weight bearing areas if compatible with adequate exploration and drainage. If not, then simple incisions are used to open up the infected area. Under no circumstances should viable skin be excised from the sole of the foot as replacement is very difficult. Debridement must be thorough and include all dead tissue. Tendons are best cut under tension to allow them to retract away from the open wound. It is important to look for evidence of pus coming down tendon sheaths as this will indicate the need for more extensive debridement. It is important to avoid straying from an infected ray into an adjacent uninvolved one as this may precipitate the loss of digits that could have been spared.

Sometimes the amount of sepsis is very extensive and there would appear to be little chance of salvaging a useful foot. It is important to undertake debridement in these cases, as some desperate looking feet turn out to have mainly superficial involvement.

When the extent of damage is uncertain, it is wise to drain all pus. All dead tissue must be excised. The wounds should always be left open and inspected at 24 to 36h. Further debridement can be carried out as necessary until the wound is clean and healing is underway. In the presence of an adequate arterial supply, rapid healing can follow a thorough debridement (Figure 2). If healing does not occur,

this is usually due to failure to drain all areas of infection, or unrecognised ischaemia.

The decision that a useful foot cannot be saved is one for the experienced surgeon. Some very odd shaped feet have served patients well for many years with skilled orthotic input. If in doubt, all dead tissue should be excised and the wounds left open. This permits delayed examination to determine the quality of the remaining tissue and if necessary to test the speed of healing. It also allows the patient to view the extent of the problem for him/herself. This can help make the decision to proceed to limb amputation more palatable.

Necrosis and foot ischaemia

The commonest presentation is of a necrotic toe which is often associated with infection in the web space (Figure 3). The other problem is the older patient who ulcerates a necrotic heel. Decubitus ulceration is the commonest cause, often as the result of immobility due to intercurrent illness. In both these cases, healing may follow localised debridement. Although extensive tissue loss over the heel usually results in limb amputation, healing is described following partial calcaneotomy (Isenberg JS et al, 1995). More extensive ischaemic changes within the foot are usually due to proximal arterial disease. Foot pulses are absent and Doppler pressures are often unreliable. The signal quality can give an indication of the severity of disease. Duplex ultrasound and arteriography are usually required to identify the extent of occlusion and to guide treatment choices. The vascular calcification that makes Doppler pressure measurement unreliable may hamper good visualisation by ultrasound. It is my practice usually to request arteriography unless tissue loss is so extensive that amputation is inevitable.

The pattern of arterial disease in diabetes is often one of spared proximal vessels down to the level of the mid-thigh or lower. Progressive occlusion is seen in more distal vessels. This distribution of disease is difficult to treat as no adequate run-off vessel can be identified onto which to place a bypass graft. However, this is not always the case and occasionally angioplasty of short occlusions, or bypass to distal calf or foot vessels, can salvage an ischaemic foot (Wengertter KR et al, 1992). The surgery is high-risk due to concomitant cardiac and

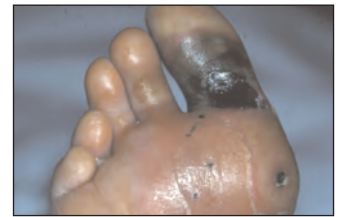

Figure 1. Foot with gas gangrene, necessitating emergency ankle disarticulation

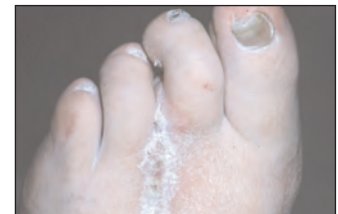

Figure 2. The healed scar following ray amputation

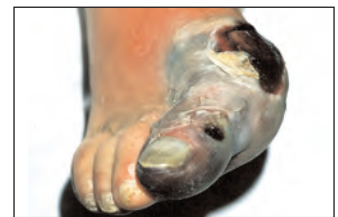

Figure 3. An ischaemic hallux with surrounding cellulites

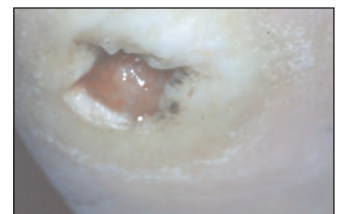


Figure 4. An ulcer under the 5th metatarsal head

PAGE POINTS

1 There are two reasons for adopting an aggressive surgical approach to the treatment of sepsis.

2 Firstly, the extent of sepsis is not often fully evident on clinical examination. Secondly, failure to drain deeper pockets of pus can lead to extensive spread of infection.

Baumhauer JF, Fraga CJ, Gould JS (1998) Total calcanectomy for the treatment of chronic calcaneal osteomyelitis. *Foot Ankle Int* **19**(12): 849-55

Calhoun JH, Overgaard KA, Stevens CM et al (2002) Diabetic foot ulcers and infections: current concepts. *Adv Skin Wound Care* **15**(1): 31-42

Eckman MH, Greenfield S, Mackey WC et al (1995) Foot infections in diabetic patients. Decision and cost-effectiveness analyses. *JAMA* **273**(9): 712-20

Enderle MD, Coerper S, Schweizer HP et al (1999) Correlation of imaging techniques to histopathology in patients with diabetic foot syndrome and clinical suspicion of chronic osteomyelitis. The role of high-resolution ultrasound. *Diab Care* **22**(2): 294-99

Eneroth M, Apelqvist J, Stenstrom A (1997) Clinical characteristics and outcome in 223 diabetic patients with deep foot infections. *Foot Ankle Int* **18**(11): 716-22

Grayson ML, Gibbons GVV, Balogh K et al (1995) Probing to bone in infected pedal ulcers. A clinical sign of underlying osteomyelitis in diabetic patients. *JAMA* **273**(9): 721-23

Howell MA, Colgan MP, Seeger RW et al (1989) Relationship of severity of lower limb peripheral vascular disease to mortality and morbidity: a six-year follow-up study. *J Vasc Surg* **9**(5): 691-96

Isonberg JS, Costigan WVM, Thordarson DB (1995) Subtotal calcanectomy for osteomyelitis of the os calcis: a reasonable alternative to free tissue transfer. *Ann Plas Surg* **35**(6): 660-63

Lepantalo M, Biancari F, Tukiainen E (2000) Never amputate without consultation of a vascular surgeon. *Diab Metab Res Rev* **16** (Suppl 1): S27-32

Meltzer DD, Pels S, Payne WG, et al (2002) Decreasing amputation rates in patients with diabetes mellitus. an outcome study. *J Am Pod Med Assoc* **92**(8): 425-28

Musharrafieh R, Saghieh S, Macari G, Atiyeh B (2003) Diabetic foot salvage with microsurgical free-tissue transfer. *Microsurgery* **23**(3): 257-61

O'Meara S (2000) Systematic reviews of wound care management. *Health Technology Assessment* **4**(21): 1-237

Pinzur MS, Slovenkai MP, Trepman E (1999) Guidelines for diabetic foot care. *Foot Ankle Int* **20**(11): 695-702

Pitei DL (1999) The effect of regular callus removal on foot pressures. *J Foot Ankle Surg* **38**(4): 251-55

Spencer S (2000) Pressure relieving interventions for preventing and treating diabetic foot ulcers. *Cochrane Database Syst Rev* 2000 (3)

Tomas MB, Marwin SE, Palestro CJ (2000) The diabetic foot. *Br J Radiology* **73**(868): 443-50

Vermassen FE, van Landuyt K (2000) Combined vascular reconstruction and free flap transfer in diabetic arterial disease. *Diab Metab Res Rev* 2000: 16: S33-6

Wengertter KR (1992) A 12 year experience with the popliteal-to-distal artery bypass. *J Vasc Surg* **15**(1): 143-49

cerebrovascular disease. The mortality risks of amputation are equivalent to arterial bypass, and quality of life will be superior if a healed limb is salvaged.

Primary limb amputation is indicated if no suitable vessel for bypass can be identified. Patients with diabetes on haemodialysis seem to have particularly poor quality vessels and seem to need primary limb amputation more commonly than those not in renal failure.

In more specialised centres, some limbs with extensive tissue loss are salvaged with simultaneous bypass surgery and free tissue flaps to replace lost tissue (Lepantalo M et al, 2000; Musharrafieh R et al, 2003; Vermassen FE et al, 2000). Flaps may be either fasciocutaneous or free muscle flaps. The latter may need to be covered with split skin grafts, but can provide useful bulk where extensive tissue resection has preceded reconstruction. Good results are claimed for this technique from a small number of highly specialised centres. The procedures are lengthy and arduous, and careful patient selection is clearly important in obtaining a good result.

Ulceration

The presence of an ulcer on the sole of the foot indicates that there are high peak ambulatory pressures at the site of ulceration (Figure 4). Offloading the area with appropriate footwear or total contact casting is important (Spencer S, 2000; O'Meara S, 2000) although evidence from randomised trials is limited. Some debridement may be required if there is co-existent infection. It is important not to forget to pare away the excess callus because this helps to reduce peak pressures in the area of the ulcer (Spencer S, 2000; O'Meara S et al, 2000; Pitei DL, 1999).

If an extensive cavity containing necrotic material is present adjacent to the ulcer, then formal debridement will speed healing. If the cavity is clean, then surgery is not required. Rest and elevation is only required if there is active inflammation and then only until it settles. The provision of appropriate footwear to reduce loading in the area of the ulcer is the mainstay of treatment (O'Meara S et al, 2000). Healing should follow provided that the blood supply to the ulcerated area is adequate. Occasionally ulcers may be the outward evidence of deep sinuses within the foot. In this situation, the foot is prone to invasive sepsis and the sinus should ideally be laid open. This is easily done if the sinus is near the borders of

the foot, but if it is deep seated within the central part of the foot, this may not be so easily accomplished. If magnetic resonance imaging shows no evidence of collection or foreign body, then aggressive antibiotic usage and rest may allow healing.

Postoperative care and mobilisation

The principles of care are to eradicate dead and infected tissue and infection. This requires careful debridement and appropriate use of antibiotics (Pinzur MS et al, 1999). Tissue conservation is also important and a balance has to be reached that does not destabilise the foot. Loss of a single ray or the forefoot to the trans-metatarsal level is not usually a problem for subsequent shoe fitting, but tissue destruction extending into the mid-foot may result in an unstable foot that will require amputation in the future. If in doubt, the opinion of an orthopaedic specialist and orthotist can be helpful in deciding how far to persist with complex partial foot amputations.

Once wounds are clean and granulating, the patient should begin to mobilise if possible. Patients should not walk without some form of foot protection. Temporary offloading by use of rocker bottom soled plaster shoes can be used initially in the ward whilst swelling goes down. The foot should be cast for new footwear or insoles as soon as any swelling has settled. If healing is slow, then the use of total contact casting with a window cut in it is an ideal way to aid mobilisation and allow wound inspection.

Contact casting requires skilled application by an experienced plaster technician (Calhoun JH et al, 2002). Casts should be changed regularly and probably no less than fortnightly if the foot is stable. Sudden pain or numbness in a previously unaffected foot is an indication for urgent removal and review.

Conclusion

Early intervention in the infected or necrotic diabetic foot may prevent limb loss. Early aggressive debridement by the surgeon may produce an odd shaped foot, but this is likely to be more useful than prosthetic alternatives. A team of committed specialists is required to obtain good results and to provide appropriate aftercare and footwear. Avoidance of major limb amputation is the aim, and this procedure should be reserved for situations where destruction is so extensive that prolonged efforts at foot salvage are inappropriate. ■