

Surgical techniques to save the diabetic foot

Rod Chalmers

ARTICLE POINTS

- 1 The aim of foot salvage is a viable and functional limb.
- 2 Full clinical and radiological assessment of arterial supply is necessary for every patient.
- 3 Only minor amputations will heal without revascularisation.
- 4 Treat proximal arterial disease first before concentrating on the distal vessels.
- 5 Balloon angioplasty is often primary intervention of choice.
- 6 Surgical bypass to distal vessels should be with autologous vein.

KEY WORDS

- Critical limb ischaemia
- Tibial angioplasty
- Surgical bypass
- Minor amputation

Introduction

The aim of foot salvage in the setting of advanced diabetic disease is adequate vascularity and good function. In this article, we examine the various clinical scenarios in the setting of diabetic foot ischaemia that present to the vascular surgeon and how they are approached.

It is true to say that vascular surgeons may have a somewhat different approach to the diabetic foot than other physicians. Patients can present with varying degrees of sepsis (either superficial or deep) and established tissue loss in the form of ulceration (Figure 1) or gangrene (Figure 2). The lower limb problem can be found in association with widespread occlusive vascular disease with cardiac, cerebrovascular and renal involvement.

The key to limb salvage in the setting of critical ischaemia, is that a considerable number of patients who undergo major limb amputation never walk independently again (Dormandy and Keeck, 1999).

What are we trying to achieve?

The fundamental aims of foot salvage in diabetes are: the eradication of all sepsis; removal of all irreversibly damaged tissue; and the production of a viable limb with healed wounds. Above all other considerations should be the principal of creating a functional foot for the patient.

Options for intervention

Clearly these vary according to the individual patient. The best case scenario is where there is minor involvement of a single digit associated with adequate vascularity. In this case simple digit amputation can be performed.

In many other patients more than one digit is involved, or there ulceration is present with inadequate vascularity. Under these circumstances, some form of revascularisation is likely to be required to allow for the healing of amputation wounds/ulceration.

When present, sepsis should be completely removed, with thorough debridement of all necrotic tissue. Closure of wounds is dictated by the extent of tissue loss and the presence of infection. Simple digit amputations with no associated sepsis can be closed primarily. More often such wounds are left to heal by secondary intention. Occasionally split skin grafts can be used where secondary intention healing is likely to be prolonged. The use of free vascularised flaps is rare in ordinary clinical practice and highly specialised.

Assessment of limb ischaemia

The clinical history may help to provide symptoms of peripheral vascular disease, (e.g. intermittent claudication and rest pain)

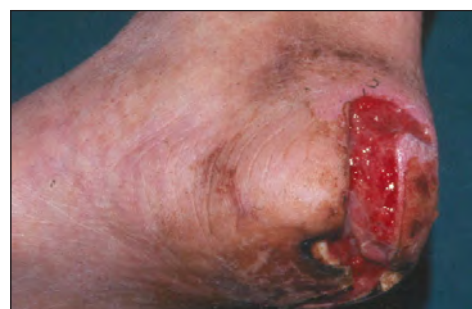

Figure 1. Deep neuropathic heel ulcer.

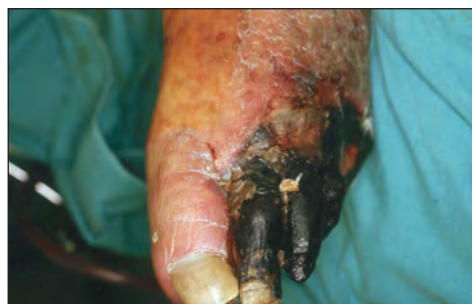

Figure 2. Diabetic gangrene of the lateral four toes of the foot.

PAGE POINTS

1 The degree of ischaemia present is often not obvious from clinical history.

2 Plain radiographs and/or magnetic resonance angiography can be used to show the extent of bone involvement and sepsis.

3 Ankle-brachial pressure measurement is unreliable in people with diabetes.

4 Duplex ultrasound is the primary investigation of choice.

5 Often the foot ischaemic and to guarantee healing of a digital amputation, some form of revascularisation is necessary.

6 Insidious deep sepsis can be missed by the inexperienced clinician.

but often these are not volunteered by people with diabetes for a number of reasons (such as immobility or neuropathy). Physical examination includes peripheral pulse palpation (although in people with diabetes the predominant arterial disease may be in the crural vessels, and concomitant large vessel disease may be in the aorto-iliac or femoro-popliteal segments) and ankle-brachial pressure measurement. The latter is often of limited use in people with diabetes because of vessel incompressibility due to calcification. The measurement of toe pressures is useful in these patients. I find that Buerger's test is a reliable clinical guide to the extent of ischaemia. Careful clinical assessment of the extent of tissue loss is vital from the outset.

In our institution it is routine practice to investigate the lower limb vasculature with duplex ultrasonography in the first instance. This can often allow intervention to be planned and minimise the exposure to iodinated contrast agents (necessary for intra-arterial angiography). Excellent visualisation can be had of the arteries from aorta to ankle. Magnetic resonance angiography can be useful for imaging the aorto-iliac segment when duplex fails to do so adequately and again, avoids the use of nephro-toxic contrast agents. We tend to reserve conventional intra-arterial contrast angiography for intervention (for example percutaneous balloon angioplasty). Plain radiographs of the foot in two planes and magnetic resonance imaging indicate the extent of bone involvement and level of spread of sepsis. Bacteriology swabs should be taken as certain infections need to be treated aggressively especially when associated with cellulitis or evidence of systemic sepsis, (e.g. MRSA).

Is the limb salvageable?

The following factors should be considered:

- The extent of tissue loss. If multiple digits are involved as well as heel necrosis or ulceration, limb salvage is unlikely to be successful.
- The level(s) of occlusive disease. The correction of inflow problems in the aorto-iliac segment may achieve adequate revascularisation, in spite of co-existing distal disease.

- Duplex ultrasound/angiography findings. These will direct the most appropriate form of revascularisation.
- Dependent Doppler assessment of the ankle vessels. This useful bedside technique verifies the patency of the distal tibial arteries (which is important if distal reconstruction is planned), and can be enhanced by pulse generated run-off.

Strategy for limb salvage

If a single digit is involved, and from clinical assessment/investigations the foot is adequately perfused, simple digital amputation will suffice in the majority of cases. Frequently, however, the foot is ischaemic, so to guarantee healing of a digital amputation some form of revascularisation is necessary.

When multiple digits are involved a transmetatarsal amputation (TMA) may be necessary. These usually require revascularisation to guarantee healing. Where more extensive tissue loss is present and a functional foot is a reasonable prospect, revascularisation and free flap reconstruction has been achieved successfully.

Caveats

- If in doubt about the perfusion of the foot and there is a realistic option for revascularisation, this should be performed.
- Caution needs to be exercised about the use of prosthetic bypass grafts to the infrageniculate vessels. Not only is the patency of such grafts far inferior to autologous vein bypass but also, in the setting of sepsis (especially MRSA) there is a very real risk of graft infection.
- Insidious deep sepsis can be missed by the inexperienced clinician.
- Beware of surgical overambition. Many patients who present with advanced diabetic foot sepsis are not fit to withstand multiple operations, the success of which depends on many factors often related to cardiovascular status. Sometimes, the best option for such patients is primary limb amputation.

Revascularisation: options

Ideally, to aid the healing of amputation sites or foot ulcers, the restoration of pulsatile blood flow to the plantar arch is necessary.

Percutaneous balloon angioplasty

This is the treatment of choice for significant focal stenoses or short occlusions of the iliac or superficial femoral arteries. I have not enjoyed good outcomes from tibial artery angioplasty, but this may be operator-dependent.

In patients with longer occlusions, the technique of subintimal angioplasty is popular. The angioplasty balloon creates a dissection plane in the subintima of the vessel and this is the new channel down which the blood flows. A study from Belgium looked at tibial angioplasty mostly in diabetic patients (Vraux, 2000) The majority of occlusions were longer than 10 cm. Technical and clinical success rates were 75%. The immediate limb amputation rate was 10%. The 12 month patency rate was 56% but even so, limb salvage was 81%. It should be recognised that the intervention's primary aim is wound healing and limb salvage. Often, long-term patency is not necessary. Negative predictors for successful tibial angioplasty were long occlusions and the presence of diabetes.

Surgery

Surgical revascularisation for the critically ischaemic foot remains the gold standard. In patients with diabetes the disease is often infra-popliteal and so by definition the bypass graft will be anastomosed to the distal tibial or plantar arteries. The proximal vessels are often essentially disease free to popliteal level, so the grafts can originate from the superficial femoral, or even the popliteal artery. *Figure 3* shows a reversed cephalic vein graft to mid-calf peroneal artery.

Reed et al from the Brigham and Women's Hospital in Boston, USA, looked at such bypasses originating from vessels below the groin (Reed et al, 2002), and compared outcomes in patients with and without diabetes. The patients with diabetes had more renal failure (33% vs 9%) and foot necrosis or gangrene (80% vs 52%). Almost half of the grafts in the patients with diabetes originated from the below-knee popliteal artery. The 5 year primary patency was 73% for people with diabetes and 45% for those without diabetes. Limb salvage was 84% and 69% respectively. Typically, for a cohort of




Figure 3. Reversed cephalic vein graft to mid-calf peroneal artery.

patients with critical limb ischaemia, the patient survival at four years was only 45%, which reiterates the fact that critical limb ischaemia, with or without diabetes, carries a poor long-term survival rate. The aim of limb salvage is for the patient to have a functional limb for that period of survival.

We recently audited the outcome of minor foot amputations in our vascular surgical service over a period of 4 years (unpublished data). We looked specifically at the outcomes for single digit amputations compared to multiple digits and transmetatarsal amputations. The influence of a number of factors including revascularisation and diabetes was assessed. In a concurrent series of 104 patients there were: 46 single digit amputations; 38 hallux only amputations (*Figure 4*); 16 multiple digit amputations; and 22 TMAs (*Figure 5*). Some form of revascularisation was performed in 60% of the hallux amputations, 47% of the TMA and 43% of the digital amputations. Although small numbers of each group were discharged with healed wounds (with district nurse and outpatient care), there was documented healing in well over 50% of single digit and hallux procedures, but less than 50% for multiple digit and TMA. Further intervention was required in 53% of TMA patients, almost half of whom ultimately lost their limb.

Over 50% of the TMA group that ultimately required limb amputation had not had revascularisation. However, of greater concern, irrespective of revascularisation, seven of nine TMA failures in patients with diabetes ended in amputation.

Nehler et al (1999) looked at a group of patients who, through clinical and non-invasive investigation, were thought to have

PAGE POINTS

1 To aid the healing of amputation sites or foot ulcers, the restoration of pulsatile blood flow to the plantar arch is necessary.

2 Percutaneous balloon angioplasty is the treatment of choice for significant focal stenoses or short occlusions of the iliac or superficial femoral arteries.

3 Proximal vessels are essentially disease free to popliteal level, and so the grafts can originate from the superficial femoral, or even the popliteal artery.

4 The aim of limb salvage is for the patient to have a functional limb for that period of survival.

PAGE POINTS

1 Irrespective of revascularisation, seven of nine TMA failures in patients with diabetes ended in amputation.

2 Case selection is vital in the attempt to salvage the diabetic foot.

3 Free flaps can offer an alternative to achieve limb salvage but this technique is not perfect and is very costly in terms of resources.

4 Revascularisation seems the sensible option to take if a viable and functional limb is to be the end result of treatment.

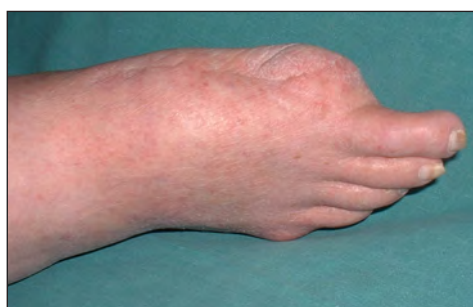

Figure 4. Healed ray amputation of the hallux two years after concomitant distal bypass.

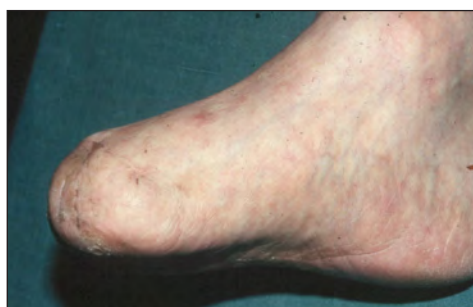

Figure 5. Transmetatarsal amputation.

adequate foot circulation to allow minor amputation and debridement, and achieve healing without revascularisation. Only 39% of the patients achieved healing whilst over a third had ongoing infection and 40% exhibited recurrent infection during follow-up. The patients who ultimately had a limb amputated, experienced almost 12 months of clinic visits and dressing changes before amputation, indicating significant quality of life issues with this approach. At the end of the 5 year follow-up period, only 54% of the patient cohort had retained the affected limb. Clearly case selection is vital in the attempt to salvage the diabetic foot.

In light of our own disappointing results with TMA, we looked at recent literature on the subject. La Fontaine and colleagues (2001) studied patients with diabetes undergoing TMA. They found that the best chance for healing of a TMA was with concomitant revascularisation.

Combined surgical bypass and free flap

The combination of revascularisation and free flap is attractive for patients with extensive tissue loss. Intuitively, if the leg can be salvaged with good functional outcome, this must be better than a prosthetic limb. However, it should be remembered that such procedures are a

massive undertaking and have major resource implications.

Vermassen reported his group's experience with 45 patients who had 53 arterial reconstructions and 47 free flaps (Vermassen and Landuyt, 2000). Grafts were anastomosed distally to tibial or pedal vessels. Muscle flaps used were rectus abdominis, latissimus dorsi and serratus anterior. Split skin grafts were sometimes required over the free muscle flaps. Of the 45 patients, 39 were discharged with a viable limb. Three year limb salvage was 65% but considerable reintervention was necessary. It is reasonable to conclude that while effective, this technique is by no means perfect and is costly in terms of resources.

Conclusion

Achieving limb salvage in the setting of the diabetic foot is a challenging problem. Often labour-intensive, the surgeon needs to temper his/her enthusiasm with realism. Patients usually have a critically ischaemic leg in the setting of co-existent neuropathy and multisystem atherosclerotic disease. The management of such patients should be tailored to the individual. My own experience with transmetatarsal amputation in people with diabetes, and that of others, indicates a need for concomitant revascularisation to give the best chance of healing. Certainly, where it is possible, revascularisation seems the sensible option to take if a viable and functional limb is to be the end result of treatment. If not, there is certainly no shame in opting for primary amputation, as this can avoid suffering of the patient.

Dormandy J, Keeck L, Vig S (1999) Major amputations: clinical patterns and predictors. *Semin Vasc Surg* **12**: 154-61

La Fontaine J, Reyzelman A, Rothenberg G, Husain K, Harkless LB (2001) The role of revascularization in transmetatarsal amputations. *J Am Podiatr Med Assoc* **91**: 533-35.

Nehler MR et al (1999) Intermediate-term outcome of primary digit amputations in patients with diabetes mellitus who have forefoot sepsis requiring hospitalization and presumed adequate circulatory status. *J Vasc Surg* **30**: 509-18.

Reed AB et al (2002) Usefulness of autogenous bypass grafts originating distal to the groin. *J Vasc Surg* **35**: 48-54.

Vermassen FE, van Landuyt K (2000) Combined vascular reconstruction and free flap transfer in diabetic arterial disease. *Diabetes Metab Res Rev* **16**: 33-36.

Vraux H et al (2000) Subintimal angioplasty of tibial vessel occlusions in the treatment of critical limb ischaemia: mid-term results. *Eur J Vasc Surg* **20**: 441-46