

Kerraboot use with a post-operative diabetic foot wound: A case report

Richard Leigh

Abnormal wound healing in people with diabetes is well recognised. Kerraboot is a non-contact boot-shaped plastic film device containing an absorbent base pad. This case study follows the progression of a post-amputation wound in the diabetic foot using Kerraboot.

Since the discovery that wound healing is promoted by a moist environment (Winter, 1962) there have been many dressings designed to achieve this (Sharman, 2003) and they have been used to improve outcomes in diabetic foot wounds. In order to maximise effective wound healing it has been suggested that a wound dressing should keep a moist and thermally protective environment around the wound (Seaman, 2002). These properties have been described in use of the dressing device Kerraboot (Ark Therapeutics, London) as a possible mechanism for stimulating granulation in chronic lower limb ulcers (Barker et al, 2005) and in exudate management (Ashton, 2004; Walker, 2006). There is some evidence that the environment produced by Kerraboot may also stimulate granulation in acute wounds (Barker et al, 2001; Barker and Leigh 2005).

It does not require secondary or retention dressings (Harvey, 2006). Kerraboot has also been shown to efficiently absorb excess ulcer exudate,

reduce wound malodour (Leigh et al, 2004) and has similar healing rates, but additionally it achieves increased granulation tissue, when compared to other dressings (Edmonds et al, 2006). A cost utility model shows that Kerraboot may be more cost effective than conventional dressings at reducing diabetic foot ulcer management (Leigh, 2006).

Case Study

A 74-year-old male (Mr X) had been attending the podiatry clinic with a chronic ulceration of his right third metatarsophalangeal joint (MTPJ). He has a medical history of type 2 diabetes, essential hypertension, myocardial infarction, protein C deficiency and activated protein C resistance, recurrent deep vein thrombosis, pulmonary embolism following transurethral resection of prostate, osteoarthritis, nocturnal dyspnoea and peripheral neuropathy.

Initially, Mr X presented to the clinic with cellulitis and was prescribed oral flucloxacillin

Article points

1. The correct environment for healing is necessary in both chronic and acute wounds.
2. Kerraboot maintains a moist and warm environment around lower limb wounds.
3. Kerraboot can stimulate granulation in acute post surgical diabetic foot wounds.

Key words

- Kerraboot
- Granulation
- Acute wound management

Richard Leigh is Chief Podiatrist at the University College London Hospitals NHS Foundation Trust, London.



Figure 1. The Kerraboot.

500mg qds and amoxicillin 500mg tds. A swab of the ulcer was taken for microbiology. The results of a Doppler scan showed that all pedal pulses in the right foot were biphasic.

After 3 days Mr X returned to the podiatry clinic with a hot, swollen right foot and a sinus tracking to bone. Microbiology reported the earlier swab as having “a mixed growth of doubtful significance”. He was admitted directly to hospital for intravenous antibiotics, magnetic resonance imaging (MRI) and further investigation.

On admission to hospital Mr X’s medication was: metformin 1g tds, atorvastatin 20mg od, valsartan 160mg od, aspirin 27mg od, warfarin 6mg (adjusted for INR), furosemide 120mg od, spironolactone 25mg od, isosorbide mononitrate 60mg od, glyceryl trinitrate spray.

Investigations

The results of the “out-of-range” blood test results on admission were as follows: HbA_{1c} 8.9%; lymphocytes 16.4% (low); urea 11.7mmol/L (high); creatinine 124µmol/L; ESR 98mm/hr; C-reactive protein 55mg/L; Hb 11.6g/dl. Blood cultures showed “no growth after 5 days incubation”.

Plain X-ray on admission reported a generalised loss of bony density, no stress fractures identified and soft tissues unremarkable (Figure 2).

Following discussion with Microbiology Mr X started teicoplanin initially 400mg over 12 hours in 3 doses then 400mg od.

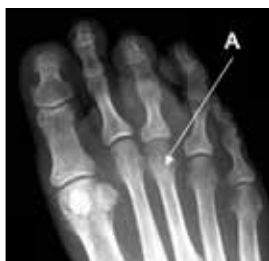

Figure 2. Plain x-ray of the right foot with the site of plantar ulceration (A).

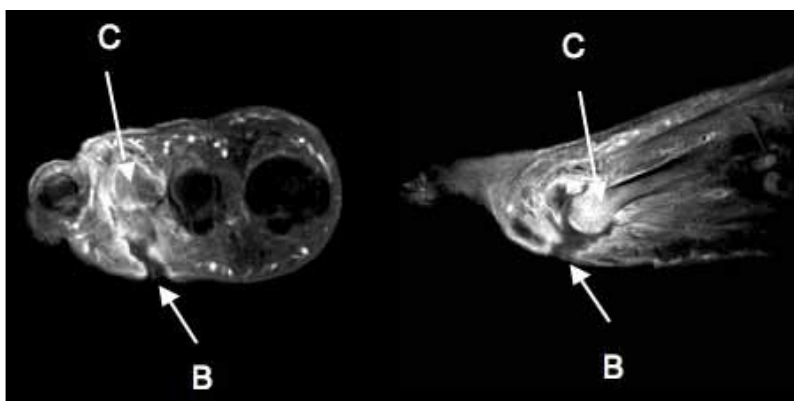


Figure 3: MRI scan right foot: transverse and sagittal views with gadolinium enhancement showing a sinus track (B) and an increased signal indicating osteomyelitis of the third metatarsal (C).

Mr X had an MRI scan (Figure 3) of the right foot, the scan report concluded:

- Septic arthritis of the third MTPJ with discharging sinus and ulcer formation on the plantar aspect of the foot.
- Sub-chondral osteomyelitis of the third metatarsal and the proximal phalanx of the third digit.
- Tenosynovitis and tendon rupture of flexor digitorum to the third digit.
- Surrounding cellulitis.
- Multiple osteochondral lesions of the tarsal bones in the mid foot in keeping with the known neuropathic foot.

A week after admission Mr X’s C-reactive protein concentration rose suddenly (C-reactive protein concentration had decreased over a week from baseline to 46.5mg/L, rapidly rising to 124.0mg/L overnight) and he underwent surgery – amputation of the right third toe and right third MTPJ. The wound was not fully closed surgically but left to heal by secondary intention, due to the underlying infection (see Figure 4). Proximally, three sutures were used to achieve partial approximation of the wound. In theatre the wound was dressed with paraffin gauze, blue gauze, surgical wool and crepe bandage.

Culture of tissue from the amputated toe produced “a mixed growth including *Citrobacter koseri* and coagulase-negative staphylococcus.” Microbiology advised not to alter antibiotic therapy.

Treatment

The surgical team wished to use topical negative pressure (TNP) on the wound post-operatively. However, no TNP units were available in the hospital at that time. There was evidence that Kerraboot would stimulate granulation in chronic wounds and the surgical team decided to adopt the use of Kerraboot, to provide a protective, warm and moist environment, allowing drainage from the wound site, until a TNP unit became available. Two days post-operatively Mr X started use of Kerraboot. This was used in conjunction with an OrthoWedge shoe (Darco International Inc. Huntingdon, US) and zimmer frame to provide offloading of the forefoot

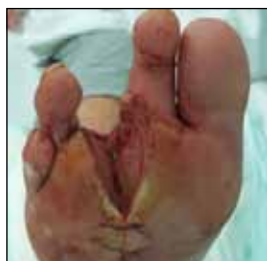

Figure 4. Postoperative amputation site.

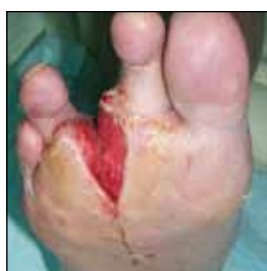

Figure 5. Eleven days after commencing Kerraboot treatment: granulation of the amputation site.

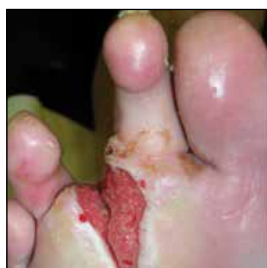

Figure 6. Three weeks after commencing Kerraboot treatment: Continuing granulation of wound site.

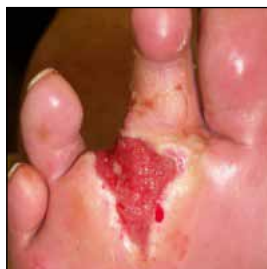

Figure 7. One month after commencing Kerraboot treatment: re-epithelialisation.

during mobilisation. When a TNP unit became available, the wound had started to granulate and Mr X said he would prefer to continue using Kerraboot as he felt it gave him more freedom than being attached to a pump and that he had no dermatological reaction to Kerraboot which he had been susceptible to with previous adhesive dressings on other ulcers. The continuing use of Kerraboot, with frequent review, was agreed by the surgical team.

Mr X developed urinary retention 5 days post operatively and *Klebsiella pneumonia* was isolated from a urine sample. This was treated with trimethoprim 960mg bd. Mr X was kept in hospital while the urinary retention remained problematic.

Eleven days postoperatively there were no clinical signs of infection in the foot and the wound was granulating well (Figure 5). However, Mr X's renal function was not improving. His C-reactive protein concentration was 10.8mg/L. Due to the clinical and haematological picture combined with decreasing renal function (creatinine 192µmol/L), the antibiotic therapy was stopped. Mr X's renal function recovered sufficiently for him to be discharged from hospital 15 days postoperatively for follow up in the outpatient department. While the delay in discharge may have favoured wound healing, due to clinical conditions and offloading, Kerraboot did not inhibit granulation or cause any adverse events suggesting it is efficacious in healing post operative diabetic foot wounds.

Mr X continued as an outpatient with Kerraboot redressing with changes every 48 hours. At dressing change the wound was

irrigated with normal saline and the Kerraboot replaced by Mr X. The wound continued to granulate well (Figure 6), filling the amputation site and re-epithelialisation was apparent 4 weeks postoperatively (Figure 7). Mr X did not have any further episodes of infection and did not require further antibiotics.

Conclusion

The management of diabetic foot wounds remains a challenge to healthcare providers and a costly burden to healthcare services (Kruse and Edelman, 2006). This case study suggests that the wound care device Kerraboot may have applications beyond chronic wound care, which has been its focus, and have a useful position in stimulating healing in postoperative foot wounds. Further study is required to confirm this. This case study also points to the need for a clinical trial to compare outcomes and cost effectiveness of the many wound care devices currently available. ■

- Ashton J (2004) Managing leg and foot ulcers: the role of Kerraboot. *British Journal of Community Nursing* 9: S26–30
- Barker S, Cooper D, Ahmed A et al (2001) The 'Wound Boot': A preliminary assessment of a novel device for the management of leg ulcers. *Phlebology* 16: 73–5
- Barker S, Aoliman S, Leigh R (2005) Stimulating granulation tissue in chronic non-healing wounds: the use of Kerraboot. *Wounds UK* 1: 37
- Barker S, Leigh R (2005) Limb salvage using Kerraboot. *British Journal of Vascular Diseases* 5: 358–60
- Edmonds M, Foster A, Jemmott T et al (2006) Randomised study of Kerraboot vs standard wound care in the management of diabetic neuropathic foot ulcers. *Wounds UK* 2: 25–30
- Harvey D (2006) New, improved Kerraboot: a tool for leg ulcer healing. *British Journal of Community Nursing* 11: S26–S30
- Kruse I, Edelman S (2006) Evaluation and Treatment of Diabetic Foot Ulcers. *Clinical Diabetes* 24: 91–3
- Leigh R (2006) A model to demonstrate the cost utility of Kerraboot. *Wounds UK November 2006, Harrogate, UK*
- Leigh R, Barker S, Murray N et al (2004) The Kerraboot. A novel wound dressing device for the management of leg and foot ulcers. *Practical Diabetes International* 21: 27–30
- Seaman S (2002) Dressing selection in chronic wound management. *Journal of the American Podiatric Medical Association* 92: 24–33
- Sharman D (2003) Moist wound healing: a review of evidence, application and outcome. *The Diabetic Foot* 6: 112–20
- Walker A (2006) Kerraboot case study. *Journal of Community Nursing* 20: 31–2
- Winter GD (1962) Formation of the scab and the rate of epithelization of superficial wounds in the skin of the young domestic pig. *Nature* 193: 293–4

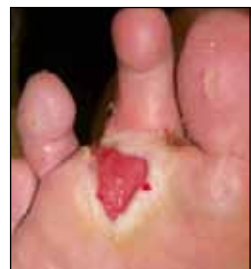

Figure 8. Ten weeks after commencing Kerraboot treatment: Re-epithelialisation.

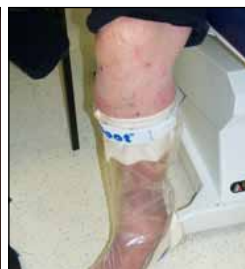

Figure 9. Continuing use of Kerraboot postoperatively.