Case series: Mepilex® Border Comfort under total contact casting in the treatment of exuding diabetic foot ulcers

Samantha Haycocks, Matthew Allen and Paul Chadwick

Haycocks S, Allen M, Chadwick P (2021) Case series: Mepilex® Border Comfort under total contact casting in the treatment of exuding diabetic foot ulcers. *The Diabetic Foot Journal* 24(2): 42–51

Key words

- Dressing wear time
- Exudate
- Healing
- Mepilex Border Comfort
- Total contact cast

By helping to remove excessive amounts of exudate yet maintaining a moist wound environment and minimising wound disturbance, advanced dressings play a key role in facilitating the healing of diabetic foot ulcers (DFUs) (Haycocks et al, 2018). Subsequently, this could reduce the risk of costly complications, such as infection and limb amputation. Pressure reduction through offloading is another mainstay of DFU management (World Union of Wound Healing Societies [WUWHS], 2016). Total contact casts (TCCs) or equivalent are internationally recognised as the 'gold standard' method of offloading (Schaper et al, 2019; Messenger et al, 2017; WUWHS, 2016). Having access to dressings that work effectively under TCCs is, therefore, an important consideration. Based on previously reported evaluations which demonstrated good exudate management properties and high conformability of a multi-layer soft silicone bordered foam dressing (Mepilex® Border Comfort*, Mölnlycke, Sweden) when used as part of the management of DFUs, the authors undertook a follow-up 10-patient case study series to examine how the same dressing performed when used under a TCC. Based on the good healing progression, the healthy condition of the periwound skin and the absence of infection observed in the case studies, it can be concluded that the dressing can be expected to perform well in conjunction with a TCC. The performance of Mepilex Border Comfort allowed the TCCs to be left *in situ* for the desired length of time (up to 7 days), thus promoting patient compliance with treatment and facilitating undisturbed wound healing.

***Mepilex Border Comfort is marketed outside of the UK as Mepilex Border Flex.**

It is estimated that 10% of people with diabetes will develop a foot ulcer at some point in their lives, with DFUs preceding more that 80% of amputations in people with diabetes (NICE, 2015). For the patient, the impact of a DFU can include symptoms such as pain, restricted mobility, pruritus, sleep disturbances, exudate leakage and malodour (WUWHS, 2016). DFUs can significantly impact morbidity and mortality and can have physical and psychological consequences, as well as substantial financial costs (Haycocks et al, 2018).

Given the complex nature of DFUs, a systematic and multidisciplinary approach to the management of these wounds requires understanding of its multiple confounding factors and aetiologies, and a holistic approach should incorporate appropriate DFU assessment, examination and therapeutic modalities with focus placed not only on evaluating and managing the wound, but also on the diagnosis and treatment of the underlying disease (WUWHS, 2016). Patient-focussed and personalised wound care helps to identify issues that may significantly impact the patient and allows the patient's fears and concerns to be addressed (WUWHS, 2016).

Pressure reduction through offloading is a key principle of DFU management and several offloading

Authors

Samantha Haycocks is Consultant Podiatrist at Salford Royal NHS Foundation Trust, Salford, UK; Matthew Allen is Principal Podiatrist at Salford Royal NHS Foundation Trust, Salford, UK; Paul Chadwick is a Visiting Professor in Tissue Viability at the Birmingham City University, Birmingham, UK

devices are available to reduce or redistribute pressure and shear from the affected site (WUWHS, 2016). There are a range of offloading devices available, including irremovable devices, removable devices, insoles and orthoses, with the choice of offloading device dependent on a range of factors (WUWHS, 2016). There is clinical evidence supporting the use of TCCs in neuropathic, non-ischaemic plantar foot ulceration. The use of TCCs has received a strong recommendation from the International Working Group of the Diabetic Foot (IWGDF) (Schaper et al, 2019) and is generally considered the 'gold standard' method of offloading neuropathic plantar DFUs (Messenger et al, 2017; WUWHS, 2016; Schaper et al, 2019). A TCC maintains contact with the entire plantar surface of the foot and lower leg, and immobilises surrounding joints and soft tissues while allowing the patient to remain ambulatory (Messenger et al, 2017). It uses minimal padding to protect the malleoli, tibia shaft and the ulcer. The padding provides total contact to the whole foot while isolating the ulcer (Messenger et al, 2017). *Figure 1* shows a TCC *in situ*.

There are many benefits to the use of TCCs, including the fact that they are irremovable, meaning that patients wear them all the time (Messenger et al, 2017). While the patient can maintain a degree of mobility while wearing a TCC, patients wearing a TCC may be less active when compared to other offloading devices, thereby reducing the number of cycles of repetitive stress (Armstrong et al, 2001; Messenger et al, 2017). Reduced vertical forces on the foot have also been associated with wearing a TCC because of altered pressure distribution, loading times, stride length and walking speed (Hartsell et al, 2002; Messenger et al, 2017). Frictional shearing forces are also controlled when using a TCC (Messenger et al, 2017).

While there is a reasonably strong evidence base in support of the use of TCCs in the management of neuropathic plantar DFUs (despite limitations in methodological robustness of some reported studies) (Bus et al, 2008; Schaper et al, 2019), there are several barriers to the implementation of TCCs, including patient approval and compliance (Raspovic and Landorf, 2014). Reduced ability to access the wound for monitoring and dressing, managing high exudate, fluctuations in oedema and impact on skin condition are among the reported wound-related barriers to the use of TCCs (Raspovic and Landorf, 2014). TCCs may also be contraindicated in certain circumstances; skin abrasions or iatrogenic ulceration, muscle atrophy and reduced bone density associated with the prolonged use of TCCs, leg-length discrepancy resulting in either new or worsening postural instability are all side effects that may be associated with TCCs (Messenger et al, 2017). Furthermore, TCC application requires skill, is time-consuming and is labour intensive (Messenger et al, 2017). However, the benefit of improved compliance of offloading and faster healing times generally outweigh these barriers.

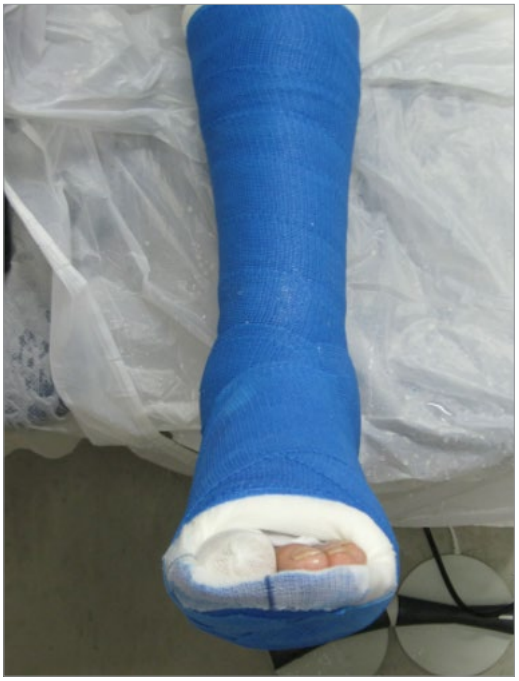

Figure 1. Example of a TCC applied.

Dressing selection is another key part of DFU management and is important in terms of providing patient wellbeing and optimising the healing process (WUWHS, 2016). However, there is limited evidence to support the use of dressings under TCCs. Exudate management is an important part of wound care and the use of dressings that can absorb and retain excess exudate, while creating a moisture balance conducive to healing is a fundamental aspect of that care (Serena et al, 2019). It is important that the wound management strategy is adaptable to address the changes that occur in terms of the levels and nature of exudate at different phases during the healing process (Serena et al, 2019). The chosen dressing should also protect against excoriation and maceration, should minimise trauma and pain during removal, and

Article points

1. Offloading and exudate management are two of the most important interventions in the care of patients with DFUs.
2. The use of total contact casts (TCCs) is often considered to be the 'gold standard' of offloading measures; therefore, there is a clear need to demonstrate that wound dressings can perform well when used under these appliances.
3. A 10-patient case study series demonstrated that a soft silicone bordered foam dressing (Mepilex Border Comfort) performed well under TCC, resulting in good healing outcomes and the avoidance of moisture-related skin damage through effective exudate management of DFUs.

should stay intact and in place during wear (Serena et al, 2019).

Comfort and conformability are also key factors to consider when choosing a dressing (Serena et al, 2019). The ability of a dressing to conform to body contours helps to ensure optimal dressing adhesion (Rippon et al, 2015). However, the foot can be a difficult anatomical area to dress and many dressings can be difficult to apply between or over the toes or plantar surface (International Best Practice Guidelines, 2013; Haycocks et al, 2018). For the patient, other issues such as exudate leakage and malodour may also be important dressing performance characteristics to consider (WUWHS, 2016).

Mepilex® Border Comfort

Dressings that are designed in such a way that they are able to remain securely in place under TCCs and effectively handle exudate during that period are likely to promote patient compliance with treatment, while, at the same time, facilitate undisturbed wound healing. Mepilex® Border Comfort (Mölnlycke, Sweden), which is marketed outside of the UK as Mepilex Border Flex, is an all-in-one self-adherent soft silicone coated foam dressing (*Figure 2*). This dressing is designed for use on a wide range of exuding wounds, such as pressure ulcers, leg and foot ulcers, traumatic wounds (e.g. skin tears) and surgical wounds. It can also be used on dry/necrotic wounds in combination with gels. It comprises:

- A wound contact layer consisting of soft silicone adhesive (Safetac®; Mölnlycke, Sweden) and a film carrier
- A flexible absorbent pad consisting of three layers: an absorbent foam, a non-woven spreading layer and a retention layer with superabsorbent fibres (the wound pad is partly perforated with Flex technology)
- An outer film that is breathable, but impermeable to water, providing a barrier to external contaminants.

Dressings incorporating Safetac wound contact layers readily adhere to intact dry skin and will remain *in situ* on the surface of a moist wound or damaged surrounding skin without adhering to these fragile tissues (White, 2005). Consequently, such dressings can be applied and reapplied without causing damage to the wound or stripping the epidermis in the periwound region (Meaume et al, 2003). The atraumatic nature of the soft silicone also helps minimise pain during dressing removal (Woo et al, 2009; Patton et al, 2013). The gentle but effective seal that forms between the intact skin and a dressing with Safetac inhibits the movement of exudate from the wound onto the surrounding skin, thereby helping prevent maceration of the periwound region (White, 2005).

The Flex technology (Y-shaped cuts in the retention and spreading layers of the absorbent pad) contributes to the flexibility and conformability of the dressing, and helps to prevent its premature detachment (Haycocks et al, 2018). As well as being waterproof, thereby allowing patients to shower with the dressing in place, the backing layer of the dressing incorporates the unique Exudate Progress Monitor. This dot pattern allows for the easy tracking and recording of fluid as it spreads.

Mepilex Border Comfort is a five-layer dressing which absorbs, channels and traps exudate, keeping exudate away from the wound bed, and preventing the re-entry of exudate, even under compression (Mölnlycke Health Care. Data on file, 2019; Serena et al, 2019). Furthermore, the dressing can handle both normal and viscous exudate (Mölnlycke Health Care. Data on file, 2019 (b); Mölnlycke Health Care. Data on file, 2018).

Based on the positive outcomes experienced in an earlier evaluation of Mepilex Border Comfort (Haycocks et al, 2018), the case studies described



Figure 2. Mepilex Border Comfort with Flex technology to enhance flexibility and conformability.

Table 1. Inclusion and exclusion criteria.

Inclusion criteria	Exclusion criteria
Subject with a neuropathic plantar diabetic foot ulcer (DFU) deemed by the investigator to be suitable for treatment with the product being evaluated (under a total contact cast (TCC), in combination with standard care).	Subject not expected to follow the evaluation procedures.
	Subject with known or suspected sensitivity to any of the components of the product being evaluated.
	Subject included in other case study series evaluation or clinical investigation at present or during the last 30 days.

Table 2. Wound status variables assessed at baseline/visit 1 and at subsequent follow-up visits (assessed after cleansing and/or debridement).

Wound status variable	Measurements
Wound tissue appearance	Description of current observation
Clinical signs of infection	Pre-defined list (tick options): no; yes *If yes, pre-defined list (tick options; may tick multiple options): increased pain; swelling; erythema; increased warmth; increased exudation; oedema; other (specify)
Condition of surrounding skin	Pre-defined list (tick options): healthy, intact; not healthy* *If not healthy, pre-defined list (tick options; may tick multiple options): eczematous; erythema; blistered; excoriated; macerated
Wound size	Length (mm), width (mm), depth (mm)
Exudate amount	Pre-defined list (tick options): low; moderate; high
Exudate quality	Pre-defined list (tick options): not applicable; clear/serous; yellow/green; brown/blood; serosanguinous/blood; purulent
Pain severity at dressing change	10-point scale: 0 = no pain, 10 = maximum pain

in this article were undertaken to evaluate the performance of the dressing when used in the management of DFUs under TCCs. In each case, TCCs (*Figure 1*) and dressings were applied according to local clinical practice and with the intention of leaving them in place for up to 7 days, depending on logistics and patient availability to attend follow-up visits. Wound size and progression to healing were assessed at each clinic visit. The performance of the dressing under the TCC was evaluated at each clinic visit in terms of the ability of the dressing to manage exudate, to remain in place and to conform to difficult-to-dress anatomical areas.

Aims

The objectives of this study were to evaluate the performance of Mepilex Border Comfort in terms of several in-use characteristics and clinical outcomes when used under TCC as part of the management of exuding DFUs.

Methods

This was a single-centre case series. Ten participants attending the Salford Royal NHS Foundation Trust with exuding DFUs who met the inclusion/exclusion criteria (out-patients) (*Table 1*) and who were receiving treatment with Mepilex Border Comfort under a TCC as part of their DFU management regimen were included in the study. Each participant was treated according to local routine clinical practice and assessed over a treatment period of up to 4 weeks or until the wound(s) healed, whichever occurred first.

Assessments were made at baseline and at each follow-up clinic visit. Wound size and progression to healing were assessed at each clinic visit. *Table 2* lists the wound and periwound status variables that were assessed (assessed after cleansing and/or debridement). All variables were assessed by visual qualitative assessment, apart from wound size, which was measured quantitatively. All wounds had sharp debridement and cleansing with saline if required.

Table 3. Investigator evaluation variables of the test dressing (measured on a five-point scale, from 'excellent' to 'very poor', assessed at each follow-up visit).

Variables
Ease of unpacking
Clarity of instructions
Ease of application
Stay on ability after application
Allows multiple inspections (long adherence)
Ease of removal without pain or skin damage
Drainage handling capacity (absorption/retention)

Digital photographs of the wound(s) were taken at each clinic visit for each participant, to monitor wound progression throughout the course of the evaluation.

The performance of Mepilex Border Comfort under the TCC was evaluated at each clinic visit (assessed qualitatively using a five-point scale from 'excellent' to 'very poor' by the clinician) in terms of the ability of the dressing to manage exudate, its ability to remain in place and conformability to difficult-to-dress anatomical areas (*Table 3*).

A total of 10 case studies were undertaken, three of which (case study 1, case study 4 and case study 9) are described in detail below. Details of all case studies are given in *Table 4* and *Table 5*.

Case study 1

A 62-year-old male with type 2 diabetes presented with two neuropathic DFUs, one to the right plantar first toe and one to the right plantar first metatarsal head, measuring 5 mm x 2 mm with a depth of 1 mm and 15 mm x 5 mm with a depth of 20 mm, respectively. Based on the date of initial diagnosis of the wounds, the wounds had been present for 1 week and were being treated with an adhesive foam and a Darby sandal. Both wounds were being treated with antibiotics (clindamycin and co-amoxiclav) for osteomyelitis.

At the baseline visit, Mepilex Border Comfort was applied under a non-removable plaster TCC. The patient attended three follow-up visits during the evaluation period, after which the patient was lost to follow-up.

At the first follow-up visit, the wound to the plantar first toe had healed. The wound to plantar first metatarsal head consisted of 100% granulation tissue, the periwound skin was healthy with a moderate amount of clear/serous exudate. There were no clinical signs of infection. No pain was reported at dressing change (the patient had neuropathy).

At the final follow-up visit (day 21), the wound to the right plantar first metatarsal head measured 10 mm x 10 mm with a depth of 5 mm and was composed of 100% granulation tissue. The periwound skin was healthy and intact, and the wound was producing a moderate amount of clear/serous exudate. There were no clinical signs of infection. No pain was reported at dressing change.

At each visit, where applicable, all dressing performance characteristics were rated as 'excellent', including ease of application, ability to remain in place, ease of removal without pain or skin damage and exudate handling capacity.

Case study 1.

Wounds at baseline (day 1), pre-cleansing/debridement.

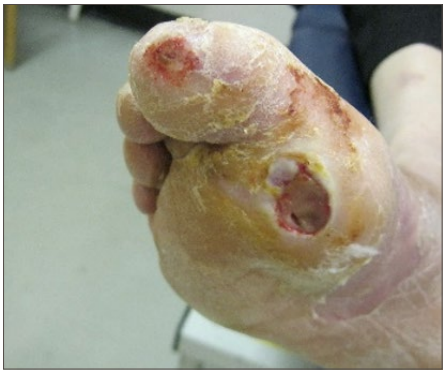

First application of Mepilex Border Comfort.

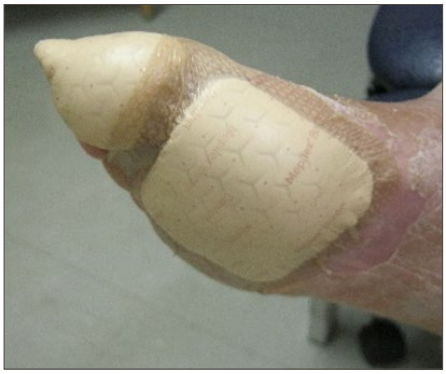

Wounds at final follow-up visit, post-cleansing/debridement (day 21).

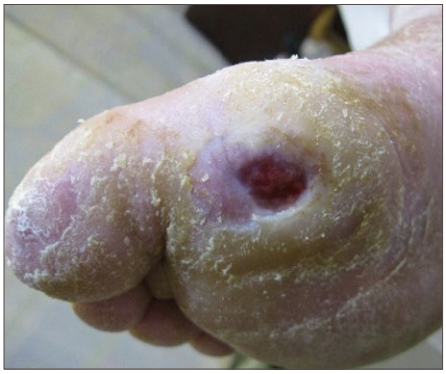

Case study 4.

Wound at baseline, post-cleansing/debridement (day1).

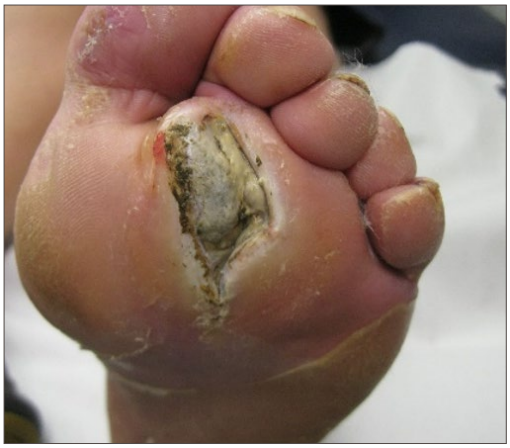

Wound at final follow-up visit, post-cleansing/debridement (day 23).

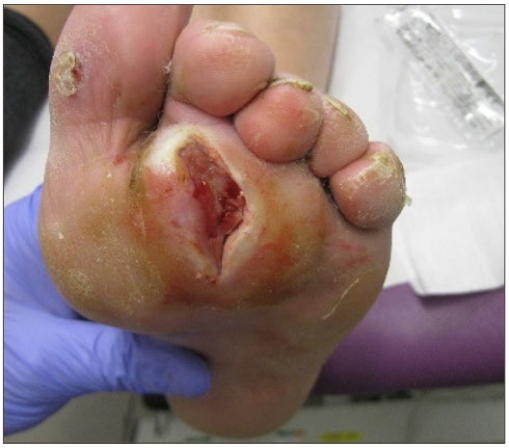

Case study 4

A 51-year-old male with type 2 diabetes presented with a neuropathic DFU on the plantar region of the right foot. The patient was receiving antibiotics (clindamycin, ciprofloxacin) due to osteomyelitis. Based on the date of initial diagnosis of the wound, the wound had been present for 30 days. The wound had previously been treated with a silver-containing dressing (Acticoat® Flex 3, Smith & Nephew) in conjunction with a superabsorbent dressing (Kerramax Care®, Crawford Healthcare). Prior to the application of the study dressing, dressing changes were being undertaken at the podiatry clinic once a week with the patient changing dressings twice a week between clinic visits.

At the baseline evaluation, the deep wound measured 60mm x 20mm. The wound was composed of over-granulation tissue. The periwound skin was macerated and erythematous. Clinical signs of infection included increased warmth, swelling and erythema. The wound was producing a moderate level of clear/serous exudate. No pain was reported at dressing change (the patient had neuropathy). To reduce hypergranulation tissue, a silver-containing dressing (Acticoat Flex 7, Smith & Nephew) was applied to the wound with Mepilex Border Comfort used as the secondary dressing under a non-removable plaster TCC. The patient attended three follow-up visits during the evaluation period. At the second follow-up visit, callous was noted which was debrided.

At the final follow-up visit (day 23), the wound measured 35mm x 10mm with a depth of 6mm and was composed of 100% granulation. The periwound skin was healthy and intact. The wound was producing a moderate (reducing) level of clear/serous exudate. There were no clinical signs of infection. No pain was reported at dressing change due to neuropathy.

At each visit, where applicable, all dressing performance characteristics were rated as 'excellent', including ease of application, ability to remain in place, ease of removal without pain or skin damage and exudate handling capacity.

Case study 9

A 50-year-old male with type 2 diabetes presented with a neuropathic ulcer on the plantar second metatarsal head area of the right foot. The wound had been present for approximately 6 months. Prior to commencement of the evaluation, dressing changes were being undertaken at the podiatry clinic once a week with the patient changing dressings twice a week between clinic visits. The wound was being treated with a soft adherent dressing with poly-absorbent fibres, a self-adhesive absorbent dressing (Mepore®, Mölnlycke, Sweden) and an offloading boot with a total contact insole.

At the baseline visit, the wound measured 6mm x 5mm with a depth of 4mm and was composed of 100% granulation. There were no clinical signs of infection. The periwound skin was healthy and intact. The wound was producing a moderate level of clear/

Case study 9.

Wound at baseline (day 1), pre-cleansing/ debridement.	Wound at first follow-up visit, post-cleansing/ debridement (day 8).	Wound at final follow-up visit, post-cleansing/ debridement (day 23).
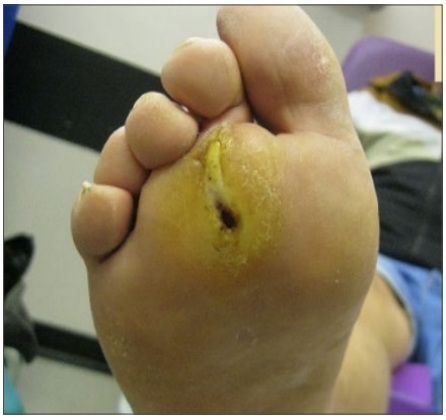	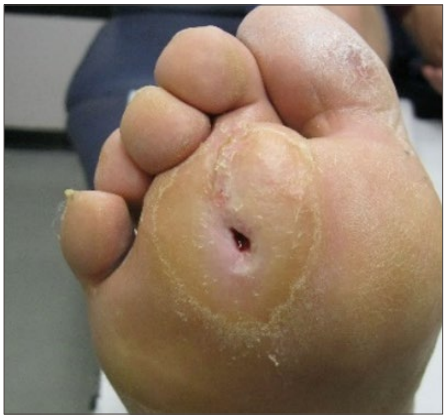	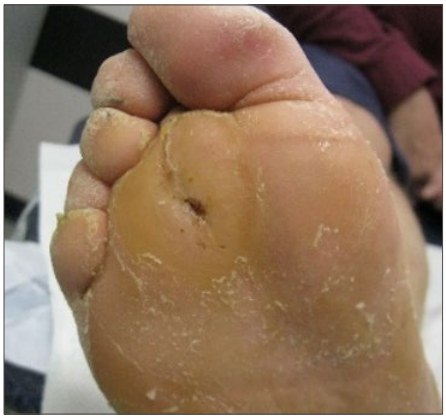

serous exudate. No pain was reported at dressing change (the patient had neuropathy). The patient underwent a tendo-achilles lengthening procedure, after which Mepilex Border Comfort was applied under a non-removable TCC. The patient attended three follow-up visits during the evaluation period.

At the final follow-up visit (day 23), the wound was fully healed. There was a small indentation in the scar line. There were no clinical signs of infection. The periwound skin was healthy and intact. There was no exudate present on the wound dressing. No pain was reported at dressing change (the patient had neuropathy). The wound was redressed with Mepilex Border Comfort as the patient was to continue in a TCC for a further 2 weeks.

At each visit, where applicable, all dressing performance characteristics were rated as 'excellent', including ease of application, ability to remain in place, ease of removal without pain or skin damage and exudate handling capacity.

Discussion

Of the 11 wounds described in the case studies above, two healed within the study period (one of the wounds in case study 1 healed by the first follow-up visit (within 1 week); the wound in case study 9 healed by follow-up day 23), with the remainder reducing in size and/or improving in appearance within 4 weeks.

Pain and trauma to the wound and periwound skin caused during the removal of dressings can negatively influence wound healing (Haycocks et al, 2018). Atraumatic dressings are designed to minimise the pain and trauma that can be associated with dressing removal. Dressings with soft silicone technology, such as Mepilex Border Comfort, also provide a gentle adhesion, ensuring the retention of wound exudate and prevention of periwound skin maceration by forming a seal between the dressing and the intact skin (White, 2005). Evaluations of the in-use characteristics of the dressing indicated that Mepilex Border Comfort was easy to remove without pain or skin damage. Exudate management is also a key factor in wound care (Tickle, 2013; Tickle, 2016; Haycocks et al, 2018); if excess exudate is not effectively absorbed and retained within the dressing, wounds can become macerated. Mepilex Border Comfort efficiently handled wound exudate under the TCCs in the presented case studies.

The ease of dressing application and conformability are particularly relevant dressing characteristics for the management of DFUs given the awkward anatomical location. In all the cases, Mepilex Border Comfort was easy to apply and remained in place under the TCC for up to 7 days.

Conclusion

While more in-depth studies are needed to substantiate the findings presented here, the results of this case study series are suggestive of the benefits of Mepilex Border Comfort in the management of DFUs when used under total contact casting in terms of exudate management, minimisation of dressing-related complications and optimisation of patient experience. Furthermore, in three of the cases

Table 4. Participant/target ulcer data at baseline (day 1).

Case No.	Participant age, gender	Wound type	Anatomical location of wound	Duration of wound (based on date of initial diagnosis of wound)	Ongoing medication/ therapy (that may affect the wound)	Comorbidities (that may affect the wound)	Current wound treatment (prior to start of dressing evaluation period)
1	62-year old male	Two DFUs - neuropathic	Wound 1: right plantar first toe Wound 2: right plantar first metatarsal head	1 week	Antibiotics – clindamycin, co-amoxiclav	Type 2 diabetes	Adhesive foam and a Darby sandal
2	32-year old male	DFU – neuropathic	Left plantar metatarsal area	Approximately 3 months	No	Type 2 diabetes	Total contact cast (TCC)
3	71-year old male	DFU – neuropathic, being treated with antibiotics for osteomyelitis	Left plantar 5th metatarsal head	6 weeks	Antibiotics – co-amoxiclav, amoxicillin	Type 2 diabetes	Tenner boot/Total contact insole
4	51-year old male	DFU – neuropathic	Plantar region of right foot	30 days	Antibiotics - clindamycin, ciprofloxacin	Type 2 diabetes	Silver-containing dressing in conjunction with a superabsorbent dressing
5	34-year old male	DFU – neuropathic	Right plantar 1st metatarsal head	18 months	Insulin	Type 1 diabetes (using insulin)	Foam dressings in conjunction with surgical footwear with insoles
6	63-year old female	DFU – neuropathic	Lateral side of the plantar area of the right foot	Approximately 9 months	Insulin, levothyroxine, simvastatin, aspirin, lisinopril, amitriptyline, pregabalin	Type 2 diabetes, renal impairment, neuropathy, previous toe amputations due to osteomyelitis	Gelling fibre (carboxymethylcellulose) dressing and foam (Mepilex, Mölnlycke, Sweden) dressings secured with a retention bandage and an offloading boot
7	62-year old female	DFU – neuropathic	Plantar area of the left foot	Approximately 2 months	No	Type 1 diabetes, chronic kidney disease (stage 3)	Gelling fibre (carboxymethylcellulose) foam dressing with silicone adhesive, silver-containing gelling fibre (carboxymethylcellulose) dressing and an offloading boot
8	38-year old female	DFU – neuropathic, being treated with antibiotics for osteomyelitis	Right plantar metatarsal area	Approximately 9 months	Antibiotics – co-amoxiclav, amoxicillin	Type 1 diabetes (using insulin)	The patient had a percutaneous tendo-achilles lengthening to reduce planter pressure and a non-removable cast applied
9	50-year old male	Neuropathic ulcer	Plantar second metatarsal head area of the right foot	Approximately 6 months		Type 2 diabetes	Soft adherent dressing with poly-absorbent fibres, a self-adhesive absorbent dressing (Mepore, Mölnlycke, Sweden) and an offloading boot with a total contact insole
10	88-year old female	DFU – neuropathic, resulting from sesamoidectomy due to osteomyelitis	Right plantar at the first metatarsal	6 days	Antibiotic cement used within surgery site – dissolves, causing increase in fluid levels	Type 2 diabetes	Antibiotic cement had been applied to the surgical site (this coincided with increased exudate levels), post-operative dressing and a backslab cast since surgery

Table 5. Wound assessment at baseline and final follow-up visit. **data first recorded at the first follow-up visit.*

Visit	Case No.	Wound size (length x width x depth, mm)	Exudate amount/ quality	Wound tissue appearance	Pain at dressing change (10-point scale; 0 = no pain, 10 = maximum pain)	Clinical signs of infection	Condition of surrounding skin	Clinician comments
Baseline	1	Wound 1 (right plantar first toe): 5 x 2 x 1 Wound 2 (right plantar first metatarsal head): 15 x 5 x 20	Moderate; clear/ serous	100% granulation*	0	No*	Healthy/intact*	
Final follow-up (day 21)		Wound 1: healed (healed by first follow up) Wound 2: 10 x 10 x 5	Wound 2: Moderate; clear/serous	Wound 2: 100% granulation	Wound 2: 0	Wound 2: No	Wound 2: Healthy/ intact	
Baseline	2	10 x 9 x 1	Moderate; clear/ serous	Granulating base	0	No	Healthy/intact	At second follow-up visit, slight wound size increase and dry skin scales due to being in cast (skin becomes dry under the cast because normal cleaning is prevented)
Final follow-up (day 28)		6 x 7 x 1	Moderate; clear/ serous	100% granulating	0	No	Healthy/intact	
Baseline	3	10 x 10 x 12	Moderate; clear/ serous	100% granulating	0	Erythema, increased warmth	Healthy/intact	Baseline visit: infection settling so put into non-removable cast; silver dressing also used due to infection (Mepilex Border Comfort used as secondary dressing under non-removable plaster TCC) During the evaluation period, there was some fluctuation in wound size, but the wound depth decreased compared to baseline
Final follow-up (day 28)		10 x 7 x 1	Low; clear/serous	100% granulating	0	No	Healthy/intact	
Baseline	4	60 x 20, deep (no measurement)	Moderate; clear/ serous	Over-granulation tissue	0	Swelling, erythema, increased warmth	Erythema, macerated	To reduce hypergranulation tissue, a silver-containing dressing (Acticoat Flex 7, Smith & Nephew) was applied to the wound with Mepilex Border Comfort used as the secondary dressing under a non-removable plaster TCC
Final follow-up (day 23)		35 x 10 x 6	Moderate (reducing); clear/serous	100% granulation	0	No	Healthy/intact	
Baseline	5	15 x 13 x 2	Moderate; clear/ serous	100% granulation	0	No	Slightly macerated	
Final follow-up (day 28)		10 x 10 x 1	Low; clear/serous	100% granulation	0	No	Healthy/intact	
Baseline	6	35 x 15 x 4	Moderate; clear/ serous*	100% granulation*	0*	No*	Slight maceration*	Final follow-up visit: wound was epithelialising; on review 7 days later, the wound had healed
Final follow-up (day 29)		20 x 3 x 0.5	Low; clear/serous	100% granulation	0	No	Healthy/intact	
Baseline	7	33 x 25 x 3	Moderate; clear/ serous	40% soft necrosis, 10% slough, 50% granulation	0	No	Healthy/intact	Third follow-up visit: silver-containing low adherent polyester dressing was used to manage hypergranulation tissue Final follow-up visit: some evidence of staining from the silver dressing
Final follow-up (day 27)		32 x 25 x 3	Moderate; clear/ serous	60% granulation (hypergranulation, which was noted at the previous visit, had reduced), 40% slough	0	No	Healthy/intact	
Baseline	8	35 x 28 x 1	Moderate; clear/ serous	80% granulation, 20% slough	0	No	Healthy/intact	First follow-up visit: dressing was coping well with the excess exudate, under the cast, so we extended time between appointments
Final follow-up (day 29)		25 x 12 x 2	Moderate to low; clear/serous	80% granulation, 20% slough	0	No	Healthy/intact	

Table 5. Wound assessment at baseline and final follow-up visit *(Continued)*. **data first recorded at the first follow-up visit.*

Visit	Case No.	Wound size (length x width x depth, mm)	Exudate amount/ quality	Wound tissue appearance	Pain at dressing change (10-point scale; 0 = no pain, 10 = maximum pain)	Clinical signs of infection	Condition of surrounding skin	Clinician comments
Baseline	9	6 x 5 x 4	Moderate; clear/ serous	100% granulation	0	No	Healthy/intact	The patient underwent a tendo-achilles lengthening procedure, after which Mepilex Border Comfort was applied under a non-removable TCC
Final follow-up (day 23)		Healed	None on dressing	Intact - small indentation in the scar line	0	No	Healthy/intact	
Baseline	10	4 x 4, deep (not probed)	Moderate; clear (exudate from the antibiotic cement 'dissolving' in the surgical wound site)	80% slough, 20% granulation (first follow-up visit)	0	No	Healthy/intact	First and second follow-up visits: slight peri-wound maceration after debridement Third follow-up visit: patient had a fall; patient not put back into TCC due to falls risk; put in offloading boot
Final follow-up (day 39)		5 x 5 x 2	Low; clear serous	Granulating appearance	0	No	Healthy/intact	Final follow-up visit: the patient was put back into a non-removable cast; the small increase in wound size was attributed to the patient being in an offloading boot.

with larger, moderately exuding wounds (cases 6, 7 and 8), cast wear time was increased. The performance of Mepilex Border Comfort allowed the TCCs to be left *in situ* for the desired length of time (up to 7 days), thus promoting patient compliance with treatment and facilitating undisturbed wound healing. ■

Acknowledgements

The case studies presented in this article were sponsored by Mölnlycke Health Care.

Centers for Disease Control and Prevention (2020)
National Armstrong DG, Nguyen HC, Lavery LA et al (2001) Off-loading the diabetic foot wound. A randomized clinical trial. *Diabetes Care* 24(6):1019–22
Bus SA, Valk GD, van Deursen RW et al (2008) The effectiveness of footwear and offloading interventions to prevent and heal foot ulcers and reduce plantar pressure in diabetes: a systematic review. *Diabetes Metab Res* 24(Suppl.1):S162–80
Hartsell HD, Brand RA, Saltzman CL (2002) Total contact casting: Its effect on contralateral plantar foot pressure. *Foot Ankle Int* 23(4): 330–34
Haycocks S, Chadwick P, Davies P (2018) Case series: Mepilex Border Comfort in the treatment of diabetic foot ulcers with exudate. *The Diabetic Foot Journal* 21(4):265–71
International Best Practice Guidelines (2013) *Wound Management in Diabetic Foot Ulcers*. Wounds International, London. Available at: www.woundsinternational.com
Meaume S, Van De Looverbosch D, Heyman H et al (2003) A study to compare a new self-adherent soft silicone dressing with a self-adherent polymer dressing in stage II pressure ulcers. *Ostomy Wound Manage* 49(9):44–51
Messenger G, Masoetsa R, Hussain I (2017) A narrative review of the benefits and risks of total contact casts in the management of diabetic foot ulcers. *J Am Coll Clin Wound Spec* 9(1–3): 19–23
Mölnlycke Health Care. Data on file, 2019
Mölnlycke Health Care. Data on file, 2019 (b)
Mölnlycke Health Care. Data on file, 2018
Mölnlycke Health Care. Report nos. PD-528870, PD-530246. Data on file
National Institute for Health and Clinical Excellence (2015) *NICE NG19. Diabetic Foot Problems: Prevention and Management*. NICE, London. Available at: https://www.nice.org.uk/guidance/ng19 (accessed 19.09.2019)
Patton ML, Mullins RF, Smith D et al (2013) An open, prospective, randomized pilot investigation evaluating pain with the use of a soft silicone wound contact layer vs bridal veil and staples on split thickness skin grafts as a primary dressing. *J Burn Care Res* 34(6): 674–81
Raspovic A, Landorf KB (2014) A survey of offloading practices for diabetes-related plantar neuropathic foot ulcers. *J Foot Ankle Res* 7: 35
Rippon M, Waring M, Bielfeldt S (2015) An evaluation of properties related to wear time of four dressings during a five-day period. *Wounds UK* 11(1): 45–54
Schaper NC, van Netten JJ, Apelqvist J et al (2019) *IWGDF Guidelines on the prevention and management of diabetic foot disease*. Available at: https://iwgdfguidelines.org/wp-content/uploads/2019/05/IWGDF-Guidelines-2019.pdf (accessed 29.06.2021)
Serena TE, Chadwick P, Davies P et al (2019) Multifunctional and patient-focused Mepilex Border Flex: an exploration of its holistic clinical benefits. *Journal of Wound Care* 28(6 Supplement 2): S1–S31
Tickle J (2013) Living day-to-day with a heavily exuding wound: recommendations for practice. *Wound Essentials* 8(1): 77–81
Tickle J (2016) Wound exudate: a survey of current understanding and clinical competency. *British Journal of Nursing* 25(2): 102–9
White R (2005) Evidence for atraumatic soft silicone wound dressing use. *Wounds UK* 1: 104–9
Woo KY, Coutts PM, Price P et al (2009) A randomized crossover investigation of pain at dressing change comparing 2 foam dressings. *Adv Skin Wound Care* 22(7): 304–10
World Union of Wound Healing Societies (2016) *Florence Congress. Position Document: Local Management of Diabetic Foot Ulcers*. London: Wounds International. Available at: file:///Users/adambushby/Downloads/position-document-local-management-diabetic-foot-ulcers%20(2).pdf (accessed 29.06.2021)