

The role of Alprep Pad® in facilitating shared care of diabetic foot ulceration

Nia J. Jones and Sarah Barnett

Citation: Jones NJ, Barnett S (2022) The role of Alprep Pad® in facilitating shared care of diabetic foot ulceration. *The Diabetic Foot Journal* 25(2): 1–8

Key words

- Debridement
- Diabetic foot ulcers
- Product evaluation
- PROMS

Article points

1. The unprecedented challenges of COVID-19 highlighted the need to deliver safe and effective shared care.
2. Alprep Pad was highly effective at physically disrupting bioburden and removing non-viable tissue from the wound bed.
3. None of the patients required treatment with antimicrobial dressings or antibiotic therapy over the 4-week evaluation period.

Authors

Nia J. Jones and Sarah Barnett are Highly Specialist Podiatrists, both at Cardiff and Vale University Health Board

The emergence of the COVID-19 pandemic has had a profound impact on the delivery of health and social care in the UK. Services have been forced to adopt unconventional ways of working to prepare for a world in which we must coexist with COVID-19. These unprecedented challenges have highlighted the need to explore alternative methods of delivering safe and effective shared care regardless of knowledge, training and specialist wound care skills. The aim of this evaluation was to document initial clinical experiences of Alprep Pad® and record the cleansing and debriding and performance. The evaluation would also explore patient reported outcome measures (PROMs) and record their personal experience of using the product between clinic visits. The findings demonstrated a 49% reduction in wound surface area over the 4-week evaluation period. One patient achieved complete healing and there was a 52% increase in the mean proportion of healthy granulation tissue documented at the wound bed, and 100% reduction in bioburden, slough and non-viable tissue. Sixty per cent of patients reported that they found Alprep Pad to be easy and convenient to use in the home setting. The remaining 40% found the product both easy and convenient to use in the home setting without the support of a healthcare professional. Overall, the PROMs demonstrated very high levels of satisfaction with the performance of Alprep Pad, with 100% of respondents expressing a preference to use the product in the future. In terms of delivering safe and effective shared care, Alprep Pad could be considered as a cost-effective intervention from a value-based healthcare perspective. Thus, reducing the need for frequent visits to the wound clinic for sharp debridement and minimising waiting times for treatment.

Diabetic foot ulceration is a global health burden that has significant psycho-social and economic ramifications. The lifetime risk of developing a diabetic foot ulcer (DFU) is between 19% and 34%. Recurrence is common after initial healing; approximately 40% of patients have a recurrence within 1 year after ulcer healing, almost 60% within 3 years and 65% within 5 years (Edmonds et al, 2021).

Foot infection is the most common cause of non-

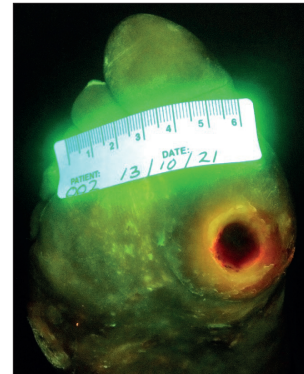
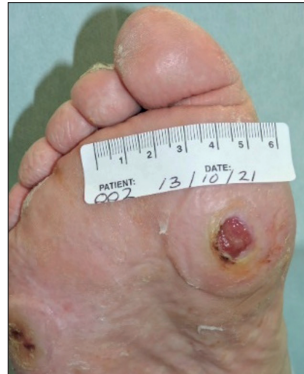traumatic amputation in persons with diabetes (Olid et al, 2015). The key diagnostic features of wound infection are the classic signs of inflammation: erythema or warmth; swelling or induration; pain or tenderness; and the presence of pus or purulent secretions. In persons with diabetes, these clinical features are often absent due to complications arising from peripheral neuropathy, peripheral vascular disease and poor innate and adaptive immune response (Harries et al, 2016). Often clinicians have

to examine the wound for evidence of secondary signs and symptoms of localised infection, such as discoloured granulation tissue, pocketing or undermining of the wound edges and the potential presence of a foul odour (Harries et al, 2016).

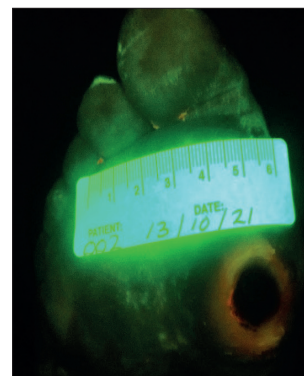
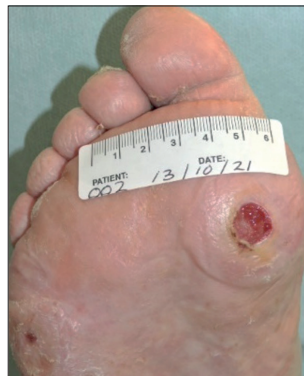The MolecuLight i:X™ (MolecuLight Inc. Toronto, Canada) is a handheld imaging device that identifies high bacterial load in and around the wound. The device emits a safe violet light that enables visualisation of fluorescence produced by bacteria and tissues (Price, 2020). This information can then be translated in clinical practice to target effective cleansing and debridement of non-viable tissue from the wound bed and surrounding tissues (Figures 1–2 and Figures 3–4). The presence of this non-viable tissue in and around the wound bed provides an optimal environment for bacterial growth, which can proliferate and further colonise the wound by constructing colonies known as biofilms (Attinger and Wolcott, 2012). These colonies are embedded and encapsulated in a matrix containing host material. They are often responsible for delayed healing and are particularly challenging to treat (Wounds UK, 2017).

Debridement has long been regarded as the cornerstone of wound bed preparation in the diabetic foot. Its primary function is to remove the cellular burden of non-viable tissue, bacteria and cells that impede the healing process (European Wound Management Association, 2004). There are many methods that facilitate effective wound debridement. These include surgical or sharp debridement, larval, mechanical, autolytic, in addition to hydrosurgical and ultrasonic methods. The gold standard technique for debriding diabetic foot ulcers is regular sharp debridement performed by an experienced practitioner with specialist training (Foot in Diabetes UK, 2012). However, expert consensus opinion states that the method of debridement must be the most effective for the patient and that this choice should not be limited by the skill of the practitioner (Gray et al, 2011).

The emergence of the COVID-19 pandemic has had a profound impact on the delivery of health and social care in the UK. Services have been forced to adopt unconventional ways of working to prepare for a world in which we must coexist with COVID-19. These unprecedented challenges have highlighted the need to explore alternative



Figures 1 & 2. Wound bed pre-debridement with Alprep Pad® at week 1.



Figures 3 & 4. Wound bed post-debridement with Alprep Pad® at week 1.

methods of delivering safe and effective shared care regardless of knowledge, training and specialist wound care skills.

Alprep Pad® is a two in one cleansing and debriding tool. It physically disrupts bioburden and removes non-viable tissue through the mechanism of mechanical debridement. The aim of this evaluation was to document initial clinical experiences of Alprep Pad and record the cleansing and debriding and performance of the product in loosening, absorbing and removing non-viable tissue, bioburden, skin scales including hyperkeratosis, slough and exudate from the wound bed, wound edge and periwound skin. The evaluation would also explore patient reported outcome measures (PROMs) and record their personal experience of using the product between clinic visits.

Methods

This product evaluation was carried out in the Diabetic Foot Clinic at Cardiff and Vale University Health Board, Wales, UK.

Study population

A total of five patients completed this evaluation. Prior to study enrolment, all patients gave their informed written consent to participate. Alprep Pad was used to debride and cleanse the wound bed, wound edge and periwound skin as part of standard care. Patients were also asked to perform a midweek interim dressing change using the Alprep Pad as part of their routine care at home.

Patient inclusion criteria

The inclusion criteria for patients included:

- Men and women aged ≥ 18 years old
- On prescription medicine for diabetes mellitus
- Peripheral neuropathy confirmed with 10g monofilament
- Wound with either confirmed bioburden, slough or non-viable tissue
- Wound classified as TWC A1 on the Texas Wound Classification System
- Duration of ulcer ≥ 6 weeks
- Concordance with optimal offloading modality
- Physically able to perform dressing changes at home
- Able to provide informed consent to participate.

Patient exclusion criteria

The exclusion criteria for patients included:

- Presence of peripheral arterial disease confirmed with doppler
- Wounds classified as \geq TWC A1 on the Texas Wound Classification System (i.e. TWC: A2, A3, B1, B2, B3, C1, C2, C3, D1, D2, D3)
- TWC A1 wounds with suspected or active Osteomyelitis confirmed with X-ray
- Infected wounds or TWC A1 wounds requiring treatment with a topical antimicrobial dressings or systemic antibiotics were excluded throughout the 4-week product evaluation
- TWC A1 wounds with 100% healthy granulation tissue
- Patients who have a current illness or condition which may interfere with wound healing in the last 30 days (carcinoma, connective tissue disease, autoimmune disease or alcohol or drug abuse)
- Life expectancy of < 3 months
- Patients who have participated in a clinical trial on wound healing within the past month
- Patients with a known history of non-adherence

with medical treatment

- Females who are pregnant
- Subject has Acquired Immunodeficiency Syndrome (AIDS) or is known to be infected with Human Immunodeficiency Virus (HIV)
- Subject has viral hepatitis.

Product evaluation objectives

This case series was conducted to evaluate the cleansing and debriding performance of Alprep Pad in loosening, absorbing and removing non-viable tissue, bioburden, skin scales including hyperkeratosis, slough and exudate from the wound bed, wound edge and periwound skin.

In addition, the evaluation assessed the safety performance of Alprep Pad in protecting newly formed granulation tissue. This was determined by assessing whether the product left newly formed granulation tissue undamaged when used in accordance with the indications for use (IFU). Any reactions observed, which were directly related to use of Alprep Pad, were reported to the manufacturer as adverse or serious adverse events.

Further feedback was collected with respect to the effectiveness and acceptability of Alprep Pad to both the clinician and patient managing the wound. Criteria used to assess effectiveness and acceptability of the product included the safe removal of bioburden, slough and non-viable tissue from the wound bed; wound edge condition, the removal of skin scales including: hyperkeratosis from the periwound skin; pain during the cleansing and debridement procedure; and clinician and patient acceptability.

Alprep Pad application

Following a thorough assessment, the wound bed, wound edge and periwound skin was debrided and cleansed with Alprep Pad and sterile saline for 2 minutes. If further sharp debridement of periwound hyperkeratosis was necessary, the type and frequency of debridement was recorded. Frequency of dressing changes were performed at the discretion of the clinician and patient. However, patients were asked to perform a midweek interim dressing change using the Alprep Pad as part of their routine care at home.

Initial and follow-up assessments

All patients received a comprehensive lower-limb

examination prior to the evaluation. Eligibility for participation was confirmed against the inclusion and exclusion criteria. The initial assessment involved recording demographic data, medical history and documenting previous treatments undertaken to the target ulcer. Medical photography and MolecuLight i:X fluorescence images were taken before and after treatment with Alprep Pad.

Subjective and objective measures were collected once a week over the 4-week evaluation period. Findings with respect to the safety, effectiveness and acceptability of the product was recorded in the Alprep Pad Case Series Questionnaire. Medical photography and MolecuLight i:X fluorescence images were taken at each clinic visit, before and after, cleansing and debriding with Alprep Pad.

Wound assessments

Clinical data was collected at the beginning of the evaluation and at each subsequent clinic visit. Features of infection were determined by the presence of three or more of the following clinical signs: periwound erythema, increasing pain between two clinic visits, malodour, abundant exudate, periwound oedema, abscess formation, cellulitis, purulent discharge, discoloured granulation tissue, and cavities probing to bone. The presence of bioburden in the wound bed, wound edge and periwound skin was established using the MolecuLight i:X camera. Photographs of the target ulcer were taken each week and the length, width and depth of the wound was recorded (cm) at each visit.

Tissue type was quantified each week according to the percentage (%) of necrotic, granulating, slough and epithelial tissue observed in the wound bed. Exudate levels were recorded using a semi-quantitative scoring system: 0 (Dry), 1 (Low), 2 (Medium) and 3 (High). The wound edge was graded as either normal, macerated, undermining, dry or other; and the condition of the periwound skin was recorded as either normal, macerated, dry, skin scales, hyperkeratosis or other. Patients were asked to self-report on pain levels using the visual analogue scale (VAS) with scores ranging from zero (0) = no pain, to ten (10) = very strong pain at each clinic visit.

Debridement sessions

Subjective measures pertaining to the clinician's

experience of using Alprep Pad were recorded at each debridement session. The first subjective measure evaluated the effectiveness of the product in loosening, absorbing and removing non-viable tissue, bioburden, skin scales including hyperkeratosis, slough and exudate from the wound bed, wound edge and periwound skin. The second subjective measure examined the safety performance of Alprep Pad in protecting newly formed granulation tissue. This was determined by assessing whether the product left newly formed granulation tissue undamaged when used in accordance with the indications for use (IFU). During the final clinic visit, a patient reported outcome measure (PROM) questionnaire was used to record the patient's acceptability of Alprep Pad as a cleansing and debriding product; in terms of ease of use, tolerability and usability. Adverse Events (AE) were reported and recorded as either related or unrelated to the intervention.

Results

A total of five patients completed the Alprep Pad evaluation; four males (80%) and one female (20%), aged between 44 and 64 years old. Patients presented with neuropathic diabetic foot wounds which had a recurrent history of infection; two plantar forefoot ulcers, one plantar hallux ulcer, one midfoot charcot joint ulcer, and one partial ray amputation ulcer. Mean wound duration was in the region of 55 weeks.

The wound surface area decreased 4.43 cm² (49%) over the 4-week period between baseline (8.96 cm²) and endpoint (3.57 cm²). One patient achieved complete healing during the evaluation (*Figure 5*). There was a 52% increase in the mean proportion of healthy granulation tissue documented at the wound bed and 100% reduction in bioburden, slough and non-viable tissue. None of the patients required treatment with antimicrobial dressings or antibiotic therapy over the 4-week evaluation period (*Table 1*).

The secondary objective outcome measures demonstrated a generalised improvement in the condition of the wound edge and periwound skin as outlined in *Figures 6* and *Figure 7*. There was also a substantial reduction in self-reported pain documented between baseline (VAS=12) and endpoint (VAS=2) clinic visits (*Table 2* and *Table 3*).

Subjective measures pertaining to the clinician's experience of using Alprep Pad were recorded at

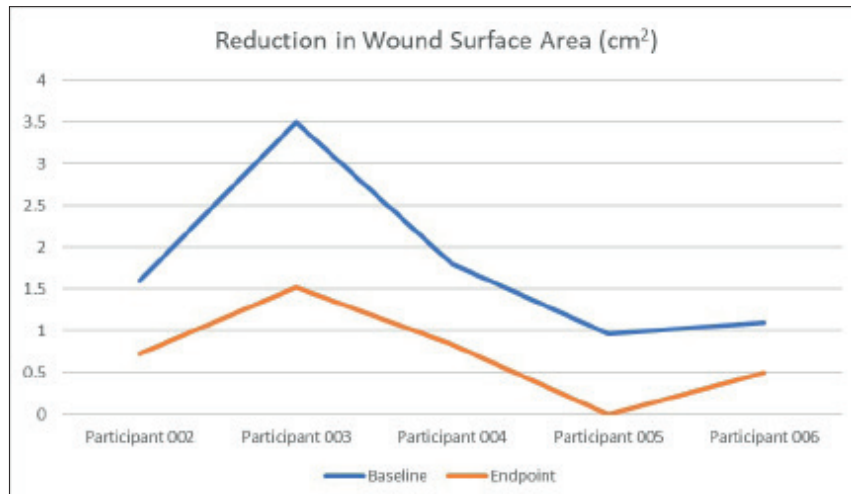


Figure 5. Reduction in wound surface area between baseline and endpoint.

each debridement session. The first subjective measure evaluated the effectiveness of the product in loosening, absorbing and removing non-viable tissue, bioburden, skin scales including hyperkeratosis, slough and exudate from the wound bed, wound edge and periwound skin (Table 2 and Table 3). Clinicians reported high satisfaction in respect of Alprep Pad cleansing and debriding properties.

The second subjective measure examined the safety performance of Alprep Pad in protecting newly formed granulation tissue. This was determined by assessing whether the product left newly formed granulation tissue undamaged when used in accordance with the IFU. Clinicians reported

moderate satisfaction with Alprep Pad safety performance in terms of protecting newly formed granulation tissue.

Discussion

The emergence of the COVID-19 pandemic has had a profound impact on the delivery of wound care services. A recent study reported that over 75% of patients discontinued their care at the wound clinic due to the pandemic. A large proportion of these patients continued to change their own wound dressings at home or had support from a relative. Almost 13% of patients did not have their wound dressing changed for the duration of the pandemic and over 15% stated that their wound had deteriorated as a result of these unprecedented challenges (Tinelli et al, 2020).

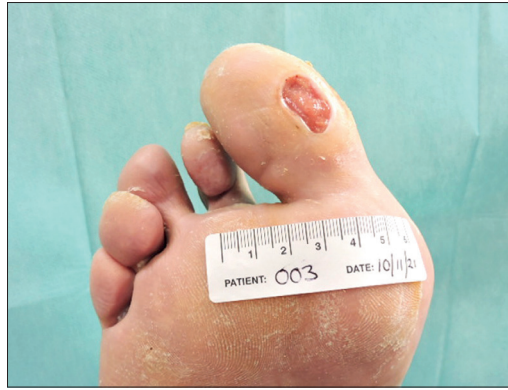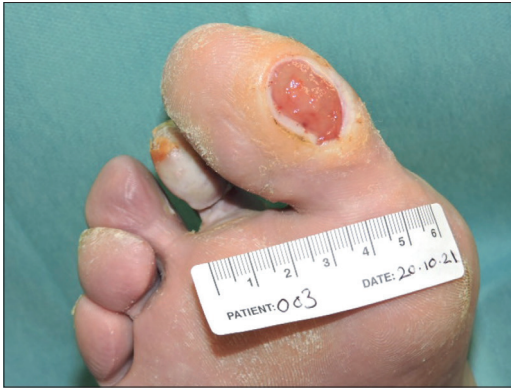While sharp debridement has long been regarded as the cornerstone of wound bed preparation in the diabetic foot, services have been forced to adopt unconventional ways of working to prepare for a world in which we must coexist with COVID-19. These unprecedented challenges have highlighted the need to explore alternative methods of delivering safe and effective shared care regardless of knowledge, training and specialist wound care skills.

Mechanical debridement is often considered an adjunct therapy to the gold standard sharp debridement. However, the findings from this

Table 1. Primary objective outcome measures between baseline and endpoint.

Participant ID	Wound size at baseline: week 1 (cm²)	Wound size at endpoint: week 4 (cm²)	Proportion (%) of granulation/epithelial tissue increase	Removal (%) of bioburden, slough and non-viable tissue
001	*	*	*	*
002	1.6	0.72	30%	100%
003	3.5	1.52	30%	100%
004	1.8	0.84	0%	100%
005	0.96	0.00**	100%**	100%**
006	1.1	0.49	100%	100%
Total	8.96 cm² Mean: 1.79 cm² Range: 3.5–0.96 cm²	3.57 cm² Mean: 0.71 cm² Range: 1.52–0.00 cm²	260% Mean: 52% Range: 0–100%	500% Mean: 100% Range: 100-100%

*Excluded with suspected osteomyelitis **healed at week 4



Figures 6 (left). Wound edge and periwound skin pre-debridement at week 1. Figure 7 (right). Wound edge and periwound skin pre-debridement at week 4.

evaluation suggest that Alprep Pad is safe and effective cleansing and debriding product in the treatment of neuropathic diabetic foot wounds at risk of infection.

Over the 4-week period, the wound surface area decreased 4.43 cm² (49%) between baseline (8.96 cm²) and endpoint (3.57 cm²). One patient achieved complete healing during the evaluation. There was a 52% increase in the mean proportion of healthy granulation tissue documented at the wound bed and 100% reduction in bioburden, slough and non-viable tissue. Previous studies have demonstrated that routine fluorescence imaging to detect wound bioburden and frequent removal of non-viable tissue from the wound bed has the potential to reduce antibiotic use and antimicrobial

dressing expenditure while improving healing outcomes (Attinger and Wolcott, 2012; Harries et al, 2016; Price, 2020).

In accordance with the evidence, none of the patients required treatment with an antimicrobial dressings or antibiotic therapy over the 4-week evaluation period, which suggests that Alprep Pad was highly effective in physically disrupting bioburden and removing non-viable tissue from the wound bed.

The findings also demonstrated a generalised improvement in the condition of the wound edge and periwound skin with regular cleansing and debridement with Alprep Pad. There was a substantial reduction in self-reported pain recorded between baseline (VAS=12) and endpoint (VAS=2).

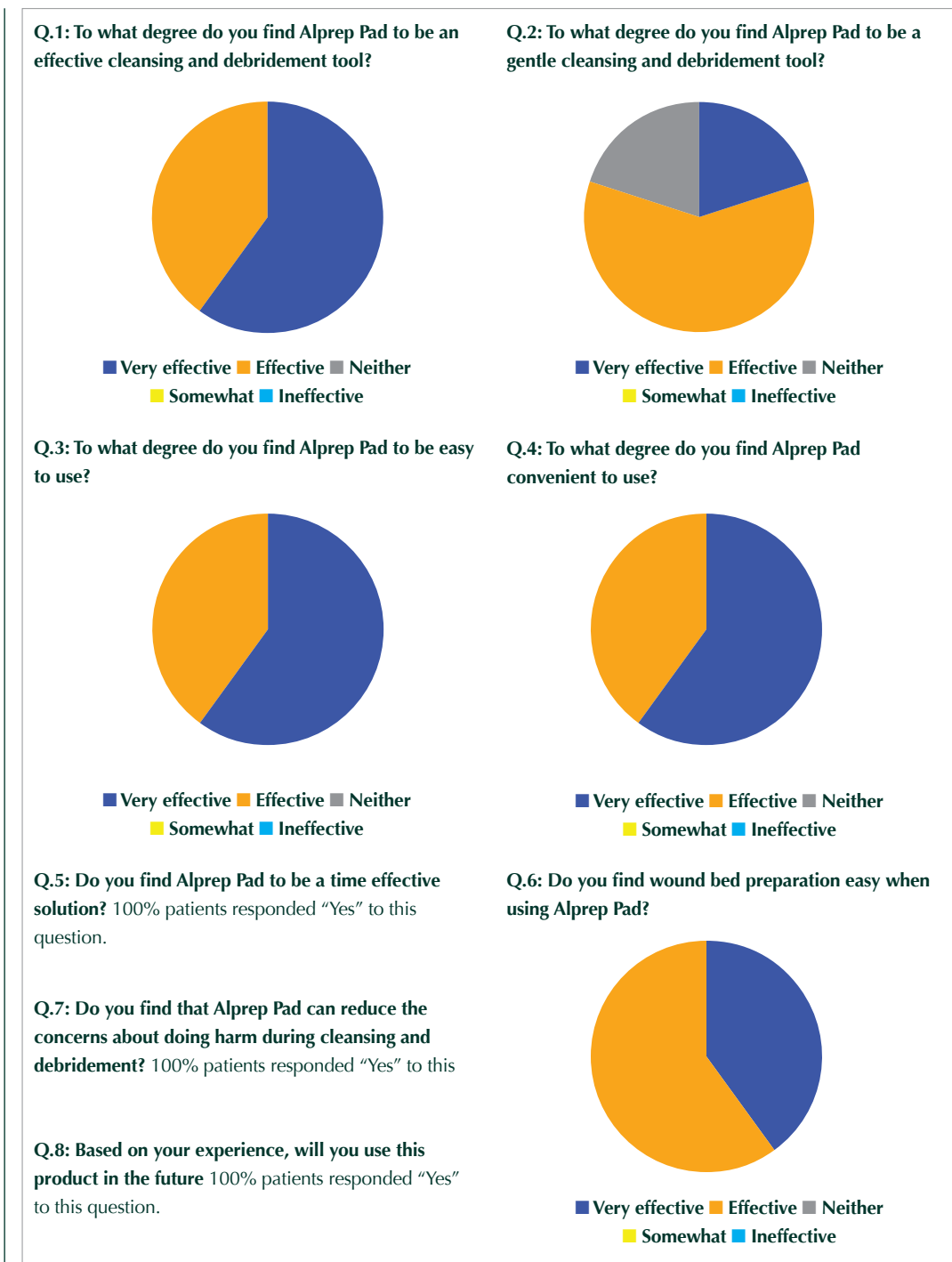
Table 2. Secondary objective outcome scores at baseline.

Participant ID	Exudate levels	Wound edge	Periwound skin	Pain score (VAS)
002	2	Dry	Dry	4
003	3	Macerated	Hyperkeratosis	5
004	2	Macerated	Hyperkeratosis	2
005	2	Dry	Hyperkeratosis	1
006	2	Undermining	Hyperkeratosis	0
Total score	11	N/A	N/A	12

Table 3. Secondary objective outcome scores at endpoint

Participant ID	Exudate levels	Wound edge	Periwound skin	Pain score (VAS)
002	2	Dry	Skin scales	2
003	3	Dry	Normal	0
004	2	Macerated	Hyperkeratosis	0
005	0	Dry	Skin scales	0
006	2	Macerated	Hyperkeratosis	0
Total score	9	N/A	N/A	2

Figure 8. PROMs data.



This was despite documented evidence of peripheral neuropathy and loss of protective sensation.

The second subjective measure examined the safety performance of Alprep Pad in protecting newly formed granulation tissue. This was determined by assessing whether the product left newly formed granulation tissue undamaged when used

in accordance with the IFU. Clinicians reported moderate satisfaction with Alprep Pad safety performance in terms of protecting newly formed granulation tissue. However, it was acknowledged that Alprep Pad was a much safer and less invasive method of removing bioburden, slough and non-viable tissue from of the wound bed when compared

against gold standard sharp debridement with a scalpel or curette device.

During the final clinic visit, a patient reported outcome questionnaire was used to record the patient's acceptability of Alprep Pad as a cleansing and debriding product; in terms of ease of use, tolerability and usability. MolecuLight i:X fluorescence images were used as a visual representation at pre-debridement and post-debridement intervals to help establish to which degree patients found Alprep Pad to be an effective cleansing and debridement tool. Sixty per cent reported that they found Alprep Pad to be a very effective cleansing and debriding tool, whilst the remaining 40% responded that it was an effective cleansing and debriding tool. A further 60% reported that it was very easy and very convenient to use in the home setting. The remaining 40% found the product both easy and convenient to use in the home setting without the support of a healthcare professional. Overall, the PROMs reported very high levels of satisfaction with the performance of Alprep Pad with 100% of respondents expressing a preference to use the product in the future.

In terms of delivering safe and effective shared care, Alprep Pad could be considered as a cost-effective intervention from a value-based healthcare perspective given that 60% of the patient cohort reported that it was both "very

easy" and "very convenient" to use in the home setting. Furthermore, it's highly effective cleansing and debriding properties could also address some of the wound care challenges posed by the COVID-19 pandemic. Thus, reducing the need for frequent visits to the wound clinic for sharp debridement and minimising waiting times for treatment. ■

- Attinger C, Wolcott R (2012) Clinically addressing biofilm in chronic wounds. *Adv Wound Care (New Rochelle)* 1(3): 127–32
- Edmonds M, Manu C, Vas P (2021) The current burden of diabetic foot disease. *J Clin Orthop Trauma* 17: 88–93
- European Wound Management Association (2004) *Position Document: Wound Bed Preparation in Practice*. London: European Wound Management Association. Available at: <https://bit.ly/3NYIKsX> (accessed 16.06.2022)
- Foot in Diabetes UK (FDUK) on behalf of the College of Podiatry (2012) *Principles of Debridement: The Diabetic Foot. Developing a Scope of Practice for Podiatrists in the UK*. London: SB Communications Group. Available at: <https://bit.ly/3Qt9QJ0> (accessed 16.06.2022)
- Gray D, Acton C, Chadwick P et al (2011) Consensus guidance for the use of debriding techniques in the UK. *Wounds UK* 7(1): 77–84
- Harries RL, Bosanquet DC, Harding KG (2016) Wound bed preparation: TIME for an update. *Int Wound J* 13(Suppl 3): 8–14
- Olid SA, Leticia IS, Barajas-Nova LA et al (2015) Systemic antibiotics for treating diabetic foot infection. *Cochrane Database Syst Rev* 4(9): CD009061
- Price N (2020) Routine fluorescence imaging to detect wound bacteria reduces antibiotic use and antimicrobial dressing expenditure while improving healing rates: Retrospective analysis of 229 foot ulcers. *Diagnostics (Basel)* 10(11): 927
- Tinelli G, Sica S, Guarnera G et al (2020) Wound care during COVID-19 pandemic. *Ann Vasc Surg* 68: 93-4
- Wounds UK (2017) *Best Practice Statement: Making Day-to-Day Management of Biofilm Simple*. London: Wounds UK. Available at: <https://bit.ly/3mXrMOF> (accessed 16.06.2022)

Declaration

The evaluation was supported by Coloplast in terms of providing the Alprep Pads free of charge. Cost of staff time was reimbursed to undertake the evaluation but this was a non-profit research project.