

Diabetic foot care: A guide for non-specialists

Neil Baker

Diabetic foot complications are very common and can frequently lead to ulceration and amputation. However, a few simple measures can help prevent these devastating consequences. Being able to identify potential problems and intervene quickly is always better than trying to remedy a problem that has already occurred. This article provides a simple guide to diabetes foot care for non-specialist clinical staff and gives a few pointers on the battle against diabetes-related lower-limb amputations.

Worldwide, approximately 463 million adults are living with diabetes; by 2045, this is predicted to rise to 700 million (International Diabetes Federation, 2019). Poorly controlled diabetes frequently leads to complications, especially in the eyes, kidneys, nerves and blood vessels. The latter two give rise to problems we see in the feet.

The most common foot complication is ulceration, with an estimated annual incidence of 2% and a lifetime incidence between 15% and 25% in people with diabetes (Schaper et al, 2016). Sadly, the 5-year mortality rate of people with newly formed foot ulcers is nearly 50%, a worse prognosis than many cancers (Armstrong et al, 2007; Wukich et al, 2013). Even after healing, the risk for ulcer relapse is very high, with reported rates between 30% and 40% within the first year (Pound et al, 2005, Bus et al, 2013). Additionally, a diabetic foot ulcer precedes 84% of all lower-leg amputations in people with diabetes (Pecoraro et al, 1990).

Preventing foot complications is essential and relies upon integrated care with unhindered clinical referral pathways (Baker, 2006). Foundations of prevention must rely upon identifying those with diabetes who are at risk of foot ulceration. Screening and ulcer risk-stratifying is just the start, and knowing who,

where and when to refer is vitally important (Leese et al, 2011). Additionally, being able to give good and, where available, evidence-based foot care advice – and being sure it is understood and implemented – are equally important (Boulton and Malik, 1998; Fletcher, 2006).

This article aims to give a brief overview of common diabetic foot problems and those who need onward referral. Foot conditions such as thickened nails, callus, dry skin and deformities are not a problem on their own but, when present with diabetic peripheral neuropathy (DPN) and/or peripheral artery disease (PAD), they can lead to ulceration or amputations (Al-Muzaini and Baker, 2017). Detecting problems early and intervening either by referral or actions can significantly help reduce foot complications.

How do I know if DPN or PAD are present?

Diabetes affects the peripheral nerves in such a way that protective sensations can be dulled or lost, and sweat glands not stimulated, leading to dry skin and muscle denervation, resulting in deformity and altered gait. The latter two are easily determined by clinical observation but the former needs to be tested for. The easiest and most reliable way of doing

Citation: Baker N (2020) Diabetic foot care: A guide for non-specialists. *Journal of Diabetes Nursing* 24: JDN144

Article points

1. The 5-year mortality rate of people with newly formed diabetic foot ulcers is nearly 50%, a worse prognosis than many cancers.
2. Detecting problems early and intervening either by referral or actions can significantly help reduce foot complications.

Key words

- Basic guide
- Diabetic foot
- Screening

Author

Neil Baker is Consultant Podiatrist, 60 Degree Vascular and Diabetic Foot Clinic, Bneid Al Gar, Kuwait.



Read more
online

Tools to improve inpatient foot checks

A multidisciplinary collaboration across all four nations to develop simple and effective tools to improve the quality and performance of comprehensive inpatient foot checks.

Journal of Diabetes Nursing
24: JDN124

[Click here to access](#)

this is by using a 10 g monofilament to determine intact or lost light touch sensation. This is explained briefly below but comprehensively by [Al-Muzaini and Baker \(2017\)](#).

More difficult to determine is PAD, as this requires both a test and clinical observation.

The loss of both pulses in a foot together with an impoverished-looking foot is indicative of possible PAD.

The following is a brief overview of common diabetic foot problems, how to detect them and how to act on them.

Neuropathy

Autonomic neuropathy

Sympathetic nerves are responsible for vasoconstriction and innervating sweat glands, thereby maintaining good skin moisture. Typically, feet have very dry, warm skin, are slightly oedematous and have strong or “bounding” foot pulses. Very dry skin becomes inelastic, so it is common to find skin fissures (splits), particularly on the borders of the heel (Baker et al, 2005b).

Motor neuropathy

This late complication manifests as a high-arched foot with clawing/retraction of the toes on standing, “hollowing out” between the extensor tendons and altered gait.

Symptomatic neuropathy

This is small nerve fibre damage producing pain or odd feelings such as burning, shooting, stabbing pains or pins and needles. It is not a risk factor for ulceration but can cause depression and is a marker of uncontrolled diabetes. It is generally under-reported, possibly because it may not form part of any formal foot or diabetes review.

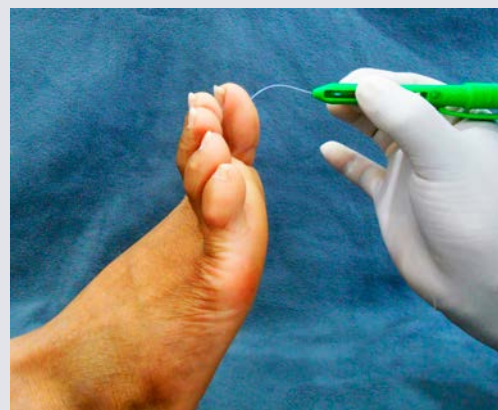Detecting neuropathy

Loss of protective sensation (LOPS)

The most common test used to determine this is simple, cheap, reliable, reproducible and easy to use with little training: the 10 g monofilament test. Inability to feel this is associated with a sevenfold increased risk of ulceration (Adler et al, 1997; Leese et al, 2006).

How to use a 10 g monofilament

Apply the monofilament gently to the tip of the first, third and fifth toes until it bends, and then slowly release. With closed eyes, patients should indicate every time they feel the stimulus.



Inability to detect one or more site in either foot indicates sensory deficit.

The literature is unclear about where or how many sites should be tested (Baker et al, 2005a). International guidelines suggest the plantar surfaces of the first toe and the first, third and fifth metatarsal heads as appropriate testing sites (Schaper et al, 2016).

If a monofilament is not available you can use a similar technique that uses your finger only: the Ipswich Touch Test (Rayman et al, 2011).

Action plan

- Improve diabetes control.
- Advice/education.
- Refer for medication if symptoms are lifestyle-limiting or cause insomnia.

Peripheral arterial disease (PAD)

This is a disease of the arteries that significantly reduces arterial blood flow, making the tissues impoverished, unable to respond to tissue damage and, ultimately, ulceration and gangrene. It is estimated that >200 million people have PAD worldwide, with symptoms ranging from none to severe (Fowkes et al, 2013). In the general population, 15–20% of people over 70 years old reportedly have PAD (Shammas, 2007). Moreover, 20–30% of people with PAD have diabetes, possibly more due to altered pain perception resulting from peripheral neuropathy (American Diabetes Association, 2003; Marso and Hiatt, 2006).

The most commonly used and accepted method for determining the possibility of PAD is by palpation of the pedal pulses (Al-Muzaini and Baker, 2017).

Pulse palpation

Although there are three arteries that enter the foot, only two of these are examined: the Dorsalis Pedis and the Posterior Tibial, as illustrated in the pictures alongside.

Feeling for the pulses:

Place your first and second fingers lightly on the patient's skin overlying the pulse site you are examining. You should feel a regular light beating under the pulps of your fingers. If you cannot feel a pulse, move your fingers slightly to the adjacent skin to try to locate one; record the pulses as "present" or "absent".

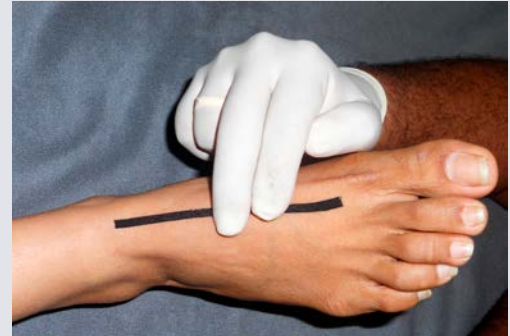
Reasons for difficulty in obtaining a pulse can be due to:

- Oedema.
- Poor technique.
- Abnormal position of arteries.
- Diseased or absent arteries.

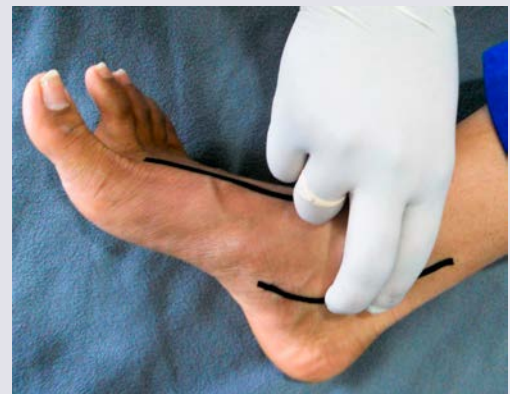Symptoms of PAD include intermittent claudication (pain in leg muscles when walking) or rest pain at night. However, these may not be present due to neuropathy. The skin may appear wrinkled, atrophic and impoverished with a loss of substance, and dark skin appears darker compared with neighbouring skin.

Action plan

- Advice/education.
- Avoid any skin breaks.
- Refer for further assessment.



Feeling for a Dorsalis Pedis pulse.



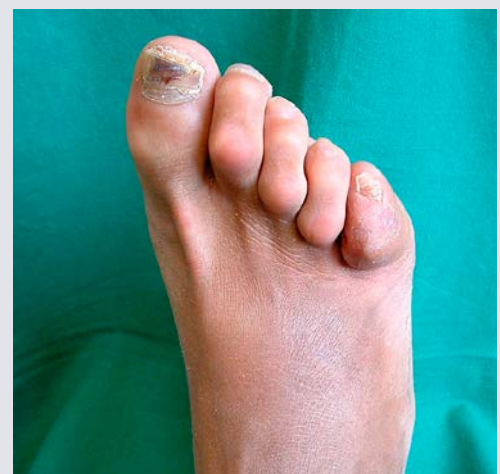Feeling for a Posterior Tibial pulse.

Foot deformity

A common-sense definition of deformity could be "a foot that cannot be accommodated in everyday shoes without distortion". The most common deformities are clawed, hammered toes and bunions. Shoe rubs are one of the most common causes of foot wounds, particularly when LOPS is present. Any patient with LOPS and foot deformity should be given footwear advice and referred to a podiatrist and possibly an orthotist. Daily self-foot examination for shoe rubs should be strongly advised.

Action plan

- Advice: Wear correctly fitting shoes, avoid slip-on shoes.

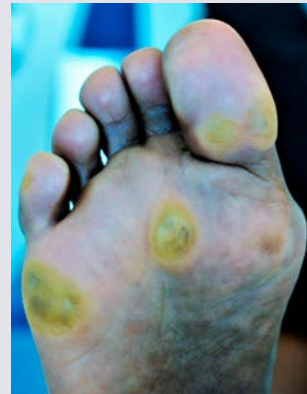

Callus and hard skin

This is a common feature of a neuropathic foot. It is strongly associated with ulceration, and its removal significantly reduces this risk (Young et al, 1992; Murray et al, 1996). The presence of bloodstained callus is highly predictive of ulceration, being present in up to 80% of cases following callus removal (Rosen et al, 1985, Harkless and Dennis, 1987). Clinically, this looks like raspberry or blackcurrant jam under hard skin! This is a clinical emergency that requires urgent attention.

Action plan

- Daily use of urea-based moisturising cream and see a podiatrist regularly.
- Do not use hard skin-removing products or devices.
- If callus is bloodstained, refer urgently to a podiatrist or diabetic foot centre.
- Advice/education.



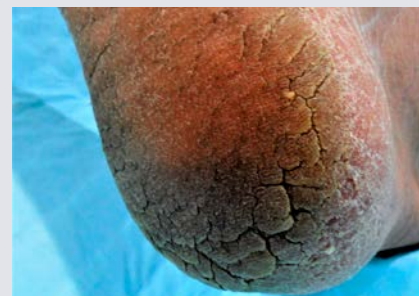
Plantar callus with evidence of underlying blood staining.

Dry skin – xeroderma

This may have a number of causes, including autonomic neuropathy, PAD, age, and medication. It causes a loss of skin elasticity, thus increasing the risk of fissures and potential infection. It is best treated by once- or twice-daily use of urea-based moisturisers (Pham et al, 2002; Rayman and Baker, 2008; Federici et al, 2012; Martini et al, 2017).

Action plan

- Xeroderma is best treated by once- or twice-daily use of urea-based moisturisers.
- Advice/education.

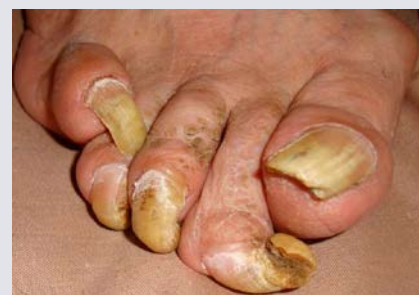

Long nails

If toenails are left to get too long, the results can be devastating in those with LOPS, as a long toenail may penetrate the next toe unnoticed. If LOPS is present, nails should be cut by a carer, as the person may unknowingly cut the end of their own toes. The most commonly used and accepted method for determining the possibility of PAD is by palpation of the pedal pulses (Al-Muzaini and Baker, 2017).

Action plan

- Simple nail care: nail should be cut following the shape of the toe, not down the sides or straight; file the edges afterwards.
- Advice/education.

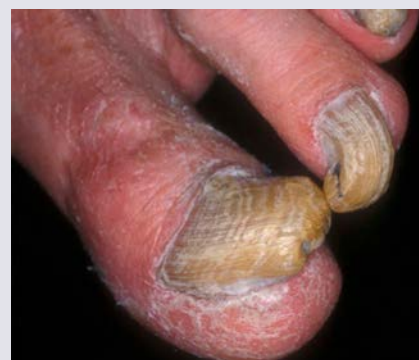

Thickened nails

The hard, thickened and frequently discoloured nail plate may lead to ulceration of the nail bed due to constant pressure (pressure injury). This can be disastrous as there is very little tissue between the nail bed and underlying bone, which, if exposed, can quickly lead to osteomyelitis. This is especially true in patients with absent sensation, poor blood supply or those with renal failure.

Action plan

- The nail should be thinned; refer to a podiatrist.
- Advice/education.

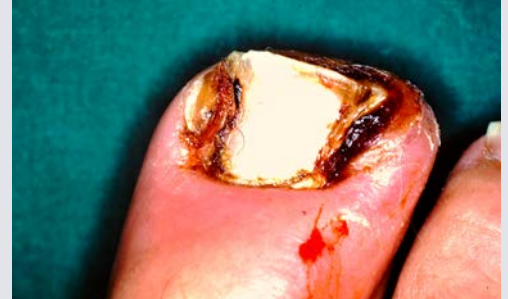

In-growing toenails

These are often caused by very curved nail plates, incorrect nail cutting or injuries leading to a spicule of nail penetrating the skin in the nail groove (sulcus). Frequently, these lesions become infected.

Action plan

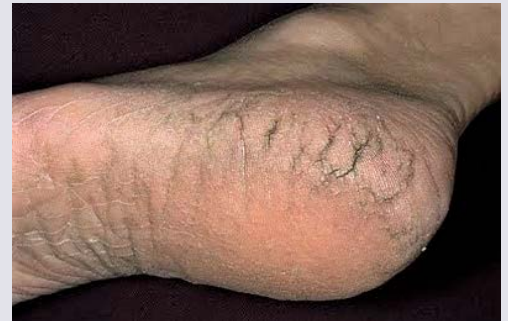- This requires the nail spicule to be removed and possibly the hypergranulation tissue to be removed. This should be referred to a podiatrist.
- If infection is present, antibiotics are required.
- A sterile antiseptic dressing should be applied if there is a wound.
- Advice/education.

**Fissures – skin splits**

Skin fissures are a common clinical finding, occurring most frequently on the heel borders, and can deteriorate rapidly to ulceration. They must be dealt with swiftly by removing the callus at the fissure margins to allow the edges to knit together.

Action plan

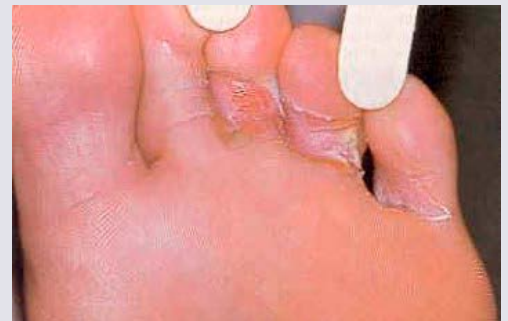- Apply urea-based moisturisers once or twice daily.
- Steristrips™ can be used to hold the fissure together.
- Follow up for any infection if the fissure has reached the dermis, and apply a sterile antiseptic dressing.
- Advice/education.

**Tinea pedis – Athlete's foot**

Fungal skin infections are not a primary cause of foot ulceration; however, they erode the epidermis, increasing the risk for bacterial infections. Common sites are between the toes and in the arch; manifestations include interdigital fissuring, flaking, vesicular eruptions, inflammation and intense itching. They are often recurrent and persistent. Fungal nail infections render the nail thick, discoloured and friable. They are less dangerous than skin infections unless the nail becomes very thick, as this may cause nail bed ulceration.

Action plan

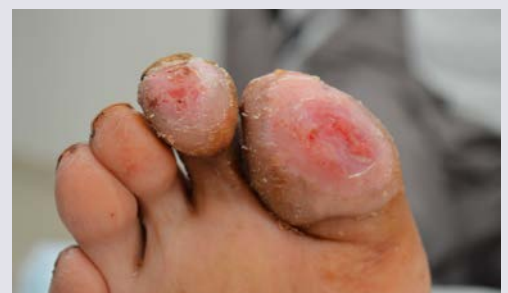- If the dermis is exposed, apply an antiseptic dressing and review until healed.
- Dry well between the toes, using topical antifungal preparations (powders for inside shoes).
- Follow up regularly until cleared, due to the risk of secondary bacterial infections.
- Reinfections are common, probably due to contaminated hosiery or shoes.
- Silver-impregnated hosiery may be effective.
- Refer nail infections to physicians or podiatrists.
- Advice/education.

**Simple wounds**

Superficial wounds can occur and should heal quickly, but they should be monitored closely, especially if LOPS or PAD are present.

Action plan

- Identify and remove the cause.
- Use an antiseptic sterile dressing.
- Review frequently until healed.
- If there are no signs of healing in 3–4 days, refer to a diabetic foot clinic.
- Advise patients with LOPS to limit weight-bearing until healed.
- Advice/education.



Ill-fitting footwear

This is possibly one of the most common extrinsic causes of foot ulceration, especially in the elderly (when wearing house-shoes or slippers). However, addressing footwear problems is very difficult owing to fashion concerns, finance, perceived comfort, ability to bend, etc. Footwear education must address these issues first.

Action plan

- Ask what shoes are normally worn. If LOPS, deformity or PAD are present, refer to a diabetic foot centre.
- Otherwise, shoes should be long, wide and deep enough to accommodate the foot adequately.
- Advice/education.



Concluding remarks

This is not a comprehensive text on diabetic foot complications but rather a simple overview of the most commonly seen foot conditions. When these are combined with peripheral neuropathy or vascular disease, they can and frequently do lead to serious problems. It is hoped that the information in this article will help non-specialist clinical staff to recognise and know what to do with the conditions mentioned.

Adler AI, Boyko EJ, Ahroni JH et al (1997) Risk factors for diabetic peripheral sensory neuropathy. Results of the Seattle Prospective Diabetic Foot Study. *Diabetes Care* **20**: 1162–7

Al-Muzaini A, Baker NR (2017) Users guide to diabetic foot screening. *Diabetic Foot Journal Middle East* **3**: 14–21

American Diabetes Association (2003) Peripheral arterial disease in people with diabetes. *Diabetes Care* **26**: 3333–41

Armstrong DG, Wrobel J, Robbins JM (2007) Guest editorial: are diabetes-related wounds and amputations worse than cancer? *Int Wound J* **4**: 286–7

Baker N, Murali-Krishnan S, Rayman G (2005a) A user's guide to foot screening. Part 1: peripheral neuropathy. *The Diabetic Foot Journal* **8**: 28–37

Baker N, Murali-Krishnan S, Rayman G (2005b) A user's guide to foot screening. Part 3: Skin and joints. *The Diabetic Foot Journal* **8**: 168–80

Baker NR (2006) Practical issues in diabetic foot care: podiatry – linking primary and secondary care. In: Boulton AJM, Cavanagh PR, Rayman G (editors). *The Foot in Diabetes* (4th edition). Wiley and Sons, Chichester: 424–30

Boulton AJ, Malik RA (1998) Diabetic neuropathy. *Med Clin North Am* **82**: 909–29

Bus SA, Waaijman R, Arts M et al (2013) Effect of custom-made footwear on foot ulcer recurrence in diabetes: a multicenter randomized controlled trial. *Diabetes Care* **36**: 4109–16

Federici A, Federici G, Milani M (2012) An urea, arginine and carnosine based cream (Ureadin Rx Db ISDIN) shows greater efficacy in the treatment of severe xerosis of the feet in type 2 diabetic patients in comparison with glycerol-based emollient cream. A randomized, assessor-blinded, controlled trial. *BMC Dermatol* **12**: 16

Fletcher J (2006) Full nursing assessment of patients at risk of diabetic foot ulcers. *Br J Nurs* **15**: S18–21

Fowkes FG, Rudan D, Rudan I et al (2013) Comparison of global estimates of prevalence and risk factors for peripheral artery disease in 2000 and 2010: a systematic review and analysis. *Lancet* **382**: 1329–40

Harkless LB, Dennis KJ (1987) You see what you look for and recognize what you know. *Clin Podiatr Med Surg* **4**: 331–9

International Diabetes Federation (2019) *Diabetes Atlas* (9th edition). IDF, Brussels. Available at: <https://bit.ly/3dBq0FY> (accessed 27.03.20)

Leese GP, Reid F, Green V et al (2006) Stratification of foot ulcer risk in patients with diabetes: a population-based study. *Int J Clin Pract* **60**: 541–5

Leese GP, Cochrane L, Mackie AD et al (2011) Measuring the accuracy of different ways to identify the “at-risk” foot in routine clinical practice. *Diabet Med* **28**: 747–54

Marso SP, Hiatt WR (2006) Peripheral arterial disease in patients with diabetes. *J Am Coll Cardiol* **47**: 921–9

Martini J, Huertas C, Turlier V et al (2017) Efficacy of an emollient cream in the treatment of xerosis in diabetic foot: a double-blind, randomized, vehicle-controlled clinical trial. *J Eur Acad Dermatol Venereol* **31**: 743–7

Murray HJ, Young MJ, Hollis S, Boulton AJ (1996) The association between callus formation, high pressures and neuropathy in diabetic foot ulceration. *Diabet Med* **13**: 979–82

Pecoraro RE, Reiber GE, Burgess EM (1990) Pathways to diabetic limb amputation. Basis for prevention. *Diabetes Care* **13**: 513–21

Pham HT, Exelbert L, Segal-Owens AC, Veves A (2002) A prospective, randomized, controlled double-blind study of a moisturizer for xerosis of the feet in patients with diabetes. *Ostomy Wound Manage* **48**: 30–6

Pound N, Chipchase S, Treece K et al (2005) Ulcer-free survival following management of foot ulcers in diabetes. *Diabet Med* **22**: 1306–9

Rayman G, Baker N (2008) Effects of a urea-based moisturiser on foot xerosis in people with diabetes. *The Diabetic Foot Journal* **11**: 179–82

Rayman G, Vas PR, Baker N et al (2011) The Ipswich Touch Test: a simple and novel method to identify inpatients with diabetes at risk of foot ulceration. *Diabetes Care* **34**: 1517–8

Rosen RC, Davids MS, Bohanske LM, Lemont H (1985) Hemorrhage into plantar callus and diabetes mellitus. *Cutis* **35**: 339–41

Schaper NC, Van Netten JJ, Apelqvist J et al; International Working Group on the Diabetic Foot (2016) Prevention and management of foot problems in diabetes: a Summary Guidance for Daily Practice 2015, based on the IWGDF Guidance Documents. *Diabetes Metab Res Rev* **32**(Suppl 1): 7–15

Shammas NW (2007) Epidemiology, classification, and modifiable risk factors of peripheral arterial disease. *Vasc Health Risk Manag* **3**: 229–34

Wukich DK, Armstrong DG, Attinger CE et al (2013) Inpatient management of diabetic foot disorders: a clinical guide. *Diabetes Care* **36**: 2862–71

Young MJ, Cavanagh PR, Thomas G et al (1992) The effect of callus removal on dynamic plantar foot pressures in diabetic patients. *Diabet Med* **9**: 55–7